

Rectal band ligation as a treatment for chronic radiation proctitis: a feasibility study



Authors

Laura Lamonaca¹, Francesco Auriemma¹, Danilo Paduano¹, Mario Bianchetti¹, Federica Spatola¹, Piera Galtieri², Roberta Maselli², Alessandro Repici^{2,3}, Benedetto Mangiavillano^{1,3}

Institutions

- 1 Gastrointestinal Endoscopy Unit – Humanitas Mater Domini, Castellanza (VA), Italy
- 2 Humanitas Clinical and Research Center IRCCS, Digestive Endoscopy Unit, Division of Gastroenterology, Rozzano (MI), Italy
- 3 Humanitas University, Department of Biomedical Sciences, Pieve Emanuele, Milan, Italy

submitted 1.8.2021

accepted after revision 6.4.2022

published online 8.4.2022

Bibliography

Endosc Int Open 2022; 10: E787–E790

DOI 10.1055/a-1821-0776

ISSN 2364-3722

© 2022. The Author(s).

This is an open access article published by Thieme under the terms of the Creative Commons Attribution-NonDerivative-NonCommercial License, permitting copying and reproduction so long as the original work is given appropriate credit. Contents may not be used for commercial purposes, or adapted, remixed, transformed or built upon. (<https://creativecommons.org/licenses/by-nc-nd/4.0/>)

Georg Thieme Verlag KG, Rüdigerstraße 14,
70469 Stuttgart, Germany

Corresponding author

Benedetto Mangiavillano, MD, Gastrointestinal Endoscopy Unit, Humanitas – Mater Domini, Via Gerenzano n.2, 21053, Castellanza (VA), Italy
Fax: +0039 0282 247385
bennymangiavillano@gmail.com

ABSTRACT

Background and study aims Chronic radiation proctitis (CRP) occurs in 5% to 20% of patients undergoing pelvic radiation therapy and frequently manifests with rectal bleeding. Endoscopic management of more severe and refractory cases can be challenging. Rectal band ligation (RBL) has been shown to be a feasible alternative to current available techniques, especially in extensive CRP. Our aim is to evaluate clinical and technical success of RBL.

Patients and methods We enrolled all consecutive patients treated with RBL for severe or recurrent hemorrhagic CRP. Success was defined as endoscopic evidence of complete rectal healing and/or cessation of bleeding not requiring further treatment or blood transfusion.

Results We enrolled 10 patients (7 males, mean age 75.6 years). Median length of the CRP from the anal verge was 4.5 cm and mean surface area involved was 89%. Eight patients (80%) were naïve to endoscopic treatment, while two had undergone argon plasma coagulation (APC). Median follow-up was 136.5 days. Success was achieved in 100% of patients after a mean number of 1.8 RBL sessions. A mean number of 4.7 bands were released in the first session while a mean of 3.1 and 2 bands were placed in the second and third sessions, respectively. As for adverse events, only one patient reported mild tenesmus and pelvic pain after the procedure.

Conclusions RBL is a safe and effective therapeutic modality for the treatment of hemorrhagic CRP. It could be considered a valid first-line option in case of extensive rectal involvement as well as a viable rescue treatment after failed APC.

Introduction

Radiation therapy (RT) is indicated for treatment of various pelvic tumors and the most frequent indications are prostate neoplasia, bladder cancer, gynecological malignancies, and anorectal cancer [1]. Due to the rapid gut epithelial turnover and to the fixed position of the rectum, pelvic RT is burdened by toxicity in the gastrointestinal tract, among which chronic radiation proctitis (CRP), also referred as radiation-associated vascular

ectasia (RAVE), affected around 30% of patients up until a few years ago [2–4]. Thanks to advances in conformal radiation, the delivery of more targeted external beam radiation and, to a lesser extent, also to prophylactic measures, the incidence of CRP has declined to 5% to 20%, although it remains a cumbersome RT complication [5].

Rectal bleeding is the most frequent symptom of CRP [4]. Its management includes medical treatment, with topical drug administration, and interventional treatment. Endoscopic therapy

is a cornerstone of treatment for CRP-related bleeding and relies on various techniques, such as argon plasma coagulation (APC), radiofrequency ablation (RFA), cryotherapy, laser therapy and Heater probe and BiCAP – contact therapy [6]. In two case reports, Mangiavillano et al. described a new treatment option for controlling rectal bleeding from CRP, which was based on the rectal band ligation (RBL) technique, but no other study of the technique has been published [7, 8]. Endoscopic band ligation has already been used to treat lower gastrointestinal bleeding from sources different from CRP, with good results [9–11].

Our belief is that RBL can be a valid further treatment modality for bleeding CRP, particularly in patients who have extensive disease with recurrent hemorrhage.

The primary aim of this study was to evaluate clinical and technical success of this new treatment for bleeding from CRP. The second aim was to evaluate the possible adverse events (AEs) related to the procedure.

Patients and methods

Study population and data record

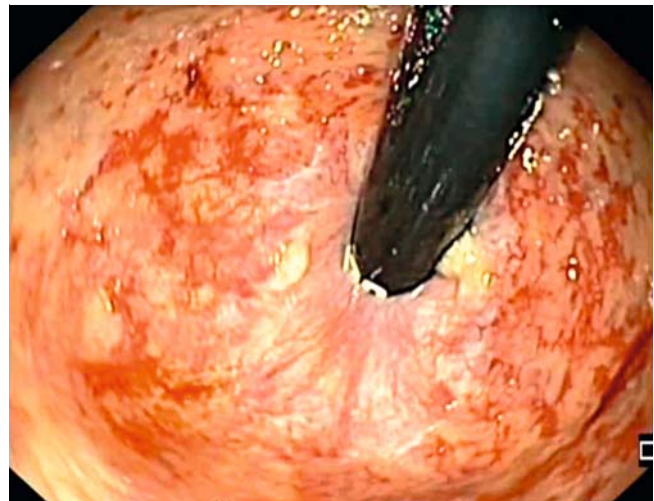
All included patients were treated in Humanitas – Mater Domini (Casellanza, Varese, Italy) and Humanitas Research Hospital (Rozzano, Milan, Italy) for persistent bleeding from CRP. After preoperative endoscopic assessment, we considered RBL in patients who had telangiectasias on more than 50% of the rectal circumference during luminal insufflation. Demographic and anamnestic data were retrospectively analyzed, as well as endoscopic aspects before and after RBL.

Rectal band ligation technique

All procedures were performed with the patient under conscious or deep sedation after bowel preparation with enemas. After endoscopic evaluation, a multi-band ligator (6 Shooter Multi-Band Ligator, Cook Medical) was mounted on a standard gastroscope and the bands were released until the visible rectal telangiectasias had been completely obliterated, up to and including the entire circumference. Attention must be paid after releasing the band because excessive insufflation can cause early slippage of the band. Standard protocol after RBL included daily mesalamine enemas for 1 month. Endoscopic control was planned between 2 and 3 months after the procedure, although earlier evaluation was performed in case of relevant recurrent bleeding. Success was defined as endoscopic evidence of complete rectal healing and/or cessation or significant reduction in bleeding not requiring further treatment or blood transfusion. Technical success was defined as the ability to place at least one band on the rectal area of interest.

Results

We enrolled and retrospectively evaluated 10 patients, who were treated between February 2016 and February 2020. There were seven males (70%) and mean age was 75.6 years. Median follow-up was of 136.5 days (range 21–979 days). All male patients had received local RT for prostate cancer. Of the remain-



► **Fig. 1** Extensive hemorrhagic CRP with telangiectasias on about 75% of the rectal circumference.

ing three women, one had been treated for endometrial cancer and the other two for a rectal adenocarcinoma.

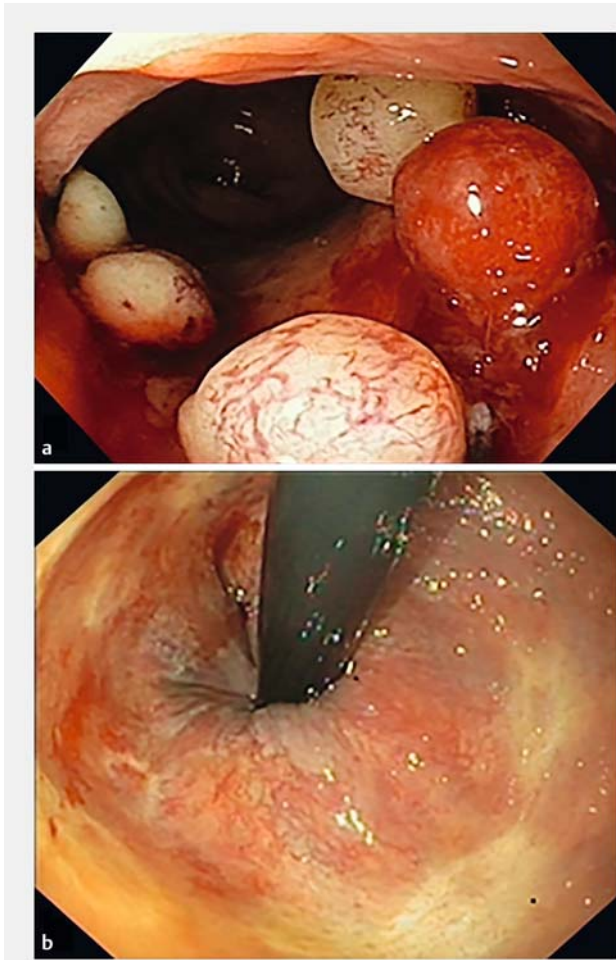
Eight patients (80%) were naïve to endoscopic treatment, while in two patients (20%), APC had already been performed without any benefit.

Median length of affected rectum from the anal verge was 4.5 ± 3.12 cm (range 3–12 cm) and mean surface area covered by telangiectasias was 89% (range 50%–100%) (► **Fig. 1**).

At least one band was released in every patient, with a technical success rate of 100%. Clinical success was achieved in 100% of patients after a mean number of 1.8 ± 0.8 RBL sessions (range 1–3) (► **Fig. 2**). A mean number of 4.7 ± 2.0 bands were released in the first session while a mean of 3.1 and 2 bands were placed in the second and third sessions, respectively. Only one patient experienced an early AE: mild tenesmus and pelvic pain the day after the procedure, with spontaneous resolution after 30 days of topical therapy with mesalamine enema. Results are summarized in ► **Table 1**.

Discussion

Pelvic radiotherapy is a fundamental step in treatment of pelvic tumors. Unfortunately, the gut wall is particularly radiosensitive due to its high epithelial turnover, and the fixed position of the rectum in the pelvis makes it prone to damage, with symptoms of CRP occurring approximately 3 to 6 months after radiation exposure [12]. Persistent bleeding is typical, with concomitant complaints of tenesmus, urgency, and fecal incontinence. To date, medical therapies and endoscopic interventions have been the best treatment modalities for CRP [2, 6]. In regard to endoscopic treatments, APC is usually the first-choice treatment modality for CRP, although no consensus exists regarding the best APC settings. Reported success rates for APC are between 70% and 90%, with at least two sessions in most of treated patients [6, 13–15]. However, if disease is extensive disease, more than two sessions may be required, and



► **Fig. 2** **a** Rectal band ligation technique on extensive CRP, which required placement of five bands for achievement of complete obliteration of visible telangiectasia. **b** At 30-month reevaluation, the rectal mucosa was completely restored.

the presence of telangiectasias on more than 50% of the surface area has been demonstrated to be related to APC failure [14].

Promising results have been reported with RFA, with clinical and endoscopic success rates of 99% and 100%, respectively, and a mean number of 1.71 RFA sessions needed to achieve response [16]. To date, use of a band ligator to treat acute lower gastrointestinal bleeding (ALGIB) has been commonly reported in the setting of colonic diverticular bleeding and is indicated as one of the first endoscopic treatment options [17]. The band ligation technique also has been used in other settings of ALGIB, such as post-polypectomy bleeding and Dieulafoy's lesion, with success rates around 93%. RBL has been used to treat rectal bleeding in patients with acute hemorrhagic rectal ulcer, rectal varices, post-prostate biopsy bleeding, and rectal Dieulafoy's lesion [9, 10]. De Robles et al. reported their experience with RBL as an often necessary complement in management of hemorrhagic radiation proctitis with concomitant symptomatic hemorrhoids, even though they released bands on hemorrhoids, unlike in the case of proctitis [11]. Mangiavillano et al.

► **Table 1** Summary of results.

	No. patients
Demographics	
▪ Males	70%
Mean age	75.6 yr
Median follow-up	136.5 d
RBL characteristics	
▪ Previous endoscopic treatment	20%
Median CRP length	4.5 cm
Mean surface area involved	89%
Mean RBL sessions	1.8
Technical success	100%
Clinical success	100%
Adverse events	1
RBL, rectal band ligation; CRP, chronic radiation proctitis.	

reported for the first time in literature, in two different case reports, the possibility of using band ligation on patients with CRP who had severe bleeding, with excellent results, although the disease was extensive [7, 8]. The supposed mechanism of action of RBL should be comparable to band ligation in esophageal varices. That is, induction of ischemic necrosis and superficial ulceration as the main modifications in the trapped tissue, with extension of histological changes limited to the mucosa and submucosa, and the intent of creating scar tissue to prevent relapse of angiogenesis [18]. Our data show 100% of technical and clinical success rates with use of RBL for treatment of CRP with fewer endoscopic sessions (mean of 1.8) than with APC. RBL also appears to be as effective as RFA, with a similar rate of success and number of endoscopic sessions required. However, it is noteworthy that the HALO catheter for RFA is not widely available and more expensive than an endoscopic band ligation system. Although RFA is increasingly being used for a variety of gastrointestinal conditions, it is primarily used in third-level centers for Barrett's esophagus ablation [19]. In contrast, every interventional endoscopy unit owns a band ligator, thus making RBL readily available. Apart from being effective, RBL is also safe because no serious AEs have been reported with it, apart from tenesmus and pelvic pain in one patient, which spontaneously improved. However, Pita et described a severe complication—development of a rectourethral fistula, which occurred in a patient with a rectal ulcer who had been treated for a hemorrhoid with elastic band ligation and had grade 1 CRP [20]. Although ulcers and fistula are counted as rare complications of CRP, this experience should heighten awareness of possible AEs in patients who have frail irradiated mucosa. RBL is distinguished from APC, which is associated with a 3% to 40% rate of AEs including ulcerations, perforations, strictures, and fistulae [14, 15]. The most common procedure-related complication with APC is rectal or anal pain,

with or without tenesmus, probably related to treatment too near the dentate line. Coriat et al. proposed to use a transparent distal attachment to improve visualization of the distal part of the rectum to ensure a proper distance for safe APC application [21]. The natural presence of the transparent cap on the ligator set helps overcome this problem. Moreover, RBL does not require particular endoscopic skills or involve a learning curve and is applicable in all endoscopic centers.

This study has some strengths. It described a novel, cheap, safe, and widely available technique for treating a common disease. Its limitations can be ascribed to the retrospective design and the small sample analyzed. Further studies are needed to confirm the efficacy of RBL, for treatment of bleeding and for other CRP-related symptoms, because APC also has been proven to improve tenesmus, diarrhea, and urgency in up to 75% of patients. An additional suggestion for future studies could be to use an endoscopic severity score to grade CRP so that results are comparable [22]. To our knowledge, ours is the first study reporting on the use of RBL for treatment of CRP.

Conclusions

In conclusion, RBL could be a valid, cheap, and easily performed alternative for treatment of persistent bleeding from CRP, particularly in patients who have wide disease extension, with a very low rate of AEs and no need for particular operator skills.

Competing interests

The authors declare that they have no conflict of interest.

References

- [1] Kamran SC, D'Amico AV. Radiation therapy for prostate cancer. *Hematol Oncol Clin North Am* 2020; 34: 45–69
- [2] Paquette IM, Vogel JD, Abbas MA et al. The American Society of Colon And Rectal Surgeons clinical practice guidelines for the treatment of chronic radiation proctitis. *Dis Colon Rectum* 2018; 61: 1135–1140
- [3] Ali F, Hu KY. Evaluation and management of chronic radiation proctitis. *Dis Colon Rectum* 2020; 63: 285–289
- [4] Wu XR, Liu XL, Katz S et al. Pathogenesis, diagnosis, and management of ulcerative proctitis, chronic radiation proctopathy, and diversion proctitis. *Inflamm Bowel Dis* 2015; 21: 703–715
- [5] Ramakrishnaiah VPN, Krishnamachari S. Chronic haemorrhagic radiation proctitis: A review. *World J Gastrointest Surg* 2016; 8: 483–491
- [6] Lenz L, Rohr S, Nakao F et al. Chronic radiation proctopathy: A practical review of endoscopic treatment. *World J Gastrointest Surg* 2016; 8: 151–160
- [7] Mangiavillano B, Morandi E, Viaggi P et al. Rectal band ligation for treatment of extensive chronic hemorrhagic radiation proctitis. *Endoscopy* 2012; 44: E375
- [8] Mangiavillano B, Bianchetti M, Semeraro R et al. Long extensive radiation proctitis treated with rectal band ligation (with video). *Dig Liver Dis* 2018; 50: 1093
- [9] Iwai N, Okuda T, Tsuji T et al. Endoscopic band ligation for a rectal dieulafoy's lesion. *Ann Gastroenterol* 2020; 33: 220
- [10] Shiratori Y, Ikeya T, Ishii N et al. Endoscopic band ligation for acute lower gastrointestinal bleeding. *Intern Med* 2019; 58: 3505–3508
- [11] De Robles MS, Young CJ. Rubber band ligation of hemorrhoids is often a necessary complement in the management of hemorrhagic radiation proctitis. *Scand J Surg* 2020; 109: 108–114
- [12] Donaldson S. Radiation proctitis after prostate carcinoma therapy. *JAMA* 1994; 271: 819–820
- [13] Furtado FS, Furtado GB, Oliveira AT et al. Endorectal formalin instillation or argon plasma coagulation for hemorrhagic radiation proctopathy therapy: a prospective and randomized clinical trial. *Gastrointest Endosc* 2021; 93: 1393–1400
- [14] Zhong QH, Liu Z, Yuan Z et al. Efficacy and complications of argon plasma coagulation for hemorrhagic chronic radiation proctitis. *World J Gastroenterol* 2019; 25: 1618–1627
- [15] Weiner J, Schwartz D, Martinez M et al. Long-term results on the efficacy of argon plasma coagulation for patients with chronic radiation proctitis after conventionally fractionated, dose-escalated radiation therapy for prostate cancer. *Pract Radiat Oncol* 2017; 7: e35–e42
- [16] McCarty TR, Garg R, Rustagi T et al. Efficacy and safety of radiofrequency ablation for treatment of chronic radiation proctitis: A systematic review and meta-analysis. *J Gastroenterol Hepatol* 2019; 34: 1479–1485
- [17] Nagata N, Ishii N, Manabe N. Guidelines for colonic diverticular bleeding and colonic diverticulitis: Japan Gastroenterological Association. *Digestion* 2019; 1: 1–26
- [18] Polski JM, Brunt EM, Saeed ZA. Chronology of histological changes after band ligation of esophageal varices in humans. *Endoscopy* 2001; 33: 443–447
- [19] Shaheen NJ, Prateek S, Overholt BF et al. Radiofrequency ablation in Barrett's esophagus with dysplasia. *N Engl J Med* 2009; 360: 2277–2288
- [20] Pita I, Bastos P, Dinis-Ribeiro M. Pelvic catastrophe after elastic band ligation in an irradiated rectum. *GE Port J Gastroenterol* 2018; 25: 42–46
- [21] Coriat R, Wolfers C, Chaput U et al. Treatment of radiation-induced distal rectal lesions with argon plasma coagulation: use of a transparent cap. *Endoscopy* 2008; 40: (Suppl. 02): E270
- [22] Zinicola R, Rutter MD, Falasco G et al. Haemorrhagic radiation proctitis: Endoscopic severity may be useful to guide therapy. *Int J Colorectal Dis* 2003; 18: 439–444