

Colorectal submucosa thickness in specimens obtained by EMR versus ESD: a retrospective pilot study



Authors

Natalie Clees¹, Alinda D. Várnai-Händel², Ralf Hildenbrand², Karl-E. Grund³, Klaus Metter⁴, Franz Ludwig Dumoulin¹

Institutions

- 1 Department of Medicine and Gastroenterology, Gemeinschaftskrankenhaus Bonn, Academic Teaching Hospital, University of Bonn, Bonn, Germany
- 2 Institute für Pathology Bonn-Duisdorf, Bonn, Germany
- 3 Institute for Experimental Surgical Endoscopy, Tübingen University, Tübingen, Germany
- 4 Clinic for Gastroenterology, Hepatology and Diabetology, Göttingen, Germany

Fax: +49-228-508-1562

f.dumoulin@gk-bonn.de

ABSTRACT

Accurate histopathology is the mainstay for reliable classification of resected early colorectal cancer lesions in terms of potential risk of lymph node metastasis. In particular, thickness of resected submucosa is important in cases of submucosal invasive cancer. Nevertheless, little is known about the quality and thickness of submucosal tissue obtained using different endoscopic resection techniques. In this small pilot study, we performed morphometric analysis of submucosal thickness in specimens obtained from right-sided colorectal lesions using endoscopic mucosal resection (EMR) versus endoscopic submucosal resection (ESD). Comparative measurements showed significant differences in submucosal area $\geq 1000 \mu\text{m}$ and minimum submucosal thickness per tissue section analyzed (EMR vs. ESD: $91.2\% \pm 6.6$ vs. $47.1\% \pm 10.6$, $P=0.018$; $933.7 \mu\text{m} \pm 125.1$ vs. $319.0 \mu\text{m} \pm 123.6$, $P=0.009$). In contrast, no significant differences were observed in variation coefficient and mean maximum submucosal thickness. Thus, unexpectedly, in this small retrospective pilot study, specimens obtained using EMR had a better preserved submucosal layer than those obtained using ESD – possibly due to the different methods of specimen acquisition. The findings should be kept in mind when attempting to resect lesions suspicious for submucosal invasive cancer.

submitted 18.12.2021

accepted after revision 30.3.2022

Bibliography

Endosc Int Open 2022; 10: E721–E726

DOI 10.1055/a-1816-6381

ISSN 2364-3722

© 2022. The Author(s).

This is an open access article published by Thieme under the terms of the Creative Commons Attribution-NonDerivative-NonCommercial License, permitting copying and reproduction so long as the original work is given appropriate credit. Contents may not be used for commercial purposes, or adapted, remixed, transformed or built upon. (<https://creativecommons.org/licenses/by-nc-nd/4.0/>)

Georg Thieme Verlag KG, Rüdigerstraße 14,
70469 Stuttgart, Germany

Corresponding author

Prof. Dr. Franz Ludwig Dumoulin, Gemeinschaftskrankenhaus Bonn – Medicine/Gastroenterology, Bonner Talweg 4-6, Bonn 53113, Germany

Introduction

Endoscopic resection of early colorectal neoplasia is the current standard of care. In cases of endoscopic resection of early colorectal cancer, resection is considered curative if the predicted lymph node metastasis risk is absent or very low [1–3]. Accepted features of low risk of lymph node metastasis are well-differentiated histology (G1/2), absence of lymph or blood vessel infiltration (L0/V0), complete (R0) resection, low tumor cell budding, and limited submucosal infiltration depth of < 1000

μm [4, 5]. Accurate histopathology, therefore, is of great importance to reliably classify a resected lesion as low or high risk, particularly in patients who have submucosal invasion. The thickness of submucosal tissue becomes even more important because even a submucosal tumor infiltration depth of $> 1000 \mu\text{m}$ with no other risk factors for lymphatic spread is probably not associated with an increased risk of lymph node metastasis [5].

The current standard for endoscopic resection of benign-appearing colorectal lesions is endoscopic mucosal resection

► **Table 1** Specimens selected for morphometric analysis.

EMR cases	Location	Size (mm)	ESD cases	Location	Size (mm)
#1	Cecum	17 (piecemeal)	# 1	Cecum	33 (en bloc)
#2	Ascending colon	23 (piecemeal)	# 2	Cecum	33 (en bloc)
#3	Ascending colon	22 (en bloc)	# 3	Ascending colon	27 (en bloc)
#4	Ascending colon	8 (en bloc)	# 4	Ascending colon	22 (en bloc)
#5	Ascending colon	12 (en bloc)	# 5	Transverse colon	33 (en bloc)
#6	Ascending colon	12 (piecemeal)	# 6	Transverse colon	36 (en bloc)

EMR: endoscopic mucosal resection; ESD: endoscopic submucosal dissection.

(EMR), which has to be carried out as fragmented resection (piecemeal EMR) in patients who have of larger flat or sessile lesions [6, 7]. The resulting specimens are suboptimal for histopathology due to fragmentation and coagulation artifacts. In patients who have invasive cancer, this can lead to unclear resection status. Moreover, coagulation artifacts may lead to destruction of possible high-risk features, and thus, result in a misclassification of high-risk lesions as low-risk. In contrast, endoscopic submucosal dissection (ESD) is superior to EMR with regard to en bloc resection rates for flat or sessile lesions measuring > 15 to 20 mm [8]. Therefore, it has been advocated for larger colorectal lesions suspected of harboring invasive cancer [1–3]. While the majority of studies focus on en bloc and R0 resection rates, little is known about quality and abundance of submucosal layer in the resected specimens, which is of particular importance in patients who have submucosal invasive cancer.

Here, we report data from a retrospective morphometric pilot study comparing submucosa quality and thickness from routine specimens obtained by piecemeal EMR versus ESD.

Methods

We analyzed tissue sections that had been processed for routine staining with hematoxylin and eosin (H&E) or periodic acid/Schiff (PAS). EMR and ESD were carried out by an experienced endoscopist (>1000 EMR/>300 colorectal ESD procedures). Normal saline with 0.05% indigo carmine was used for submucosal injection.

At the end of the procedure, en bloc EMR and ESD specimens were loosely stretched out on corkboard and immersed in 4% formaldehyde fixative. Tissue fragments from piecemeal EMR were collected directly into a vial containing the fixative solution. The pre-embedding procedure consisted of automated sequential dehydration of the tissue with increasing alcohol concentrations and gradual replacement of alcohol with paraf-

fin solvent. Finally, the specimens were embedded and sectioned for histopathology. All sections had been previously used for histopathology diagnosis carried out by certified gastrointestinal pathologists. Specimens obtained from six EMR and six ESD resections from the right colon were included in our analysis (► **Table 1**). We selected tissue sections suitable for morphometric analysis according to the following criteria: 1) sections cut in parallel to the submucosal layer; 2) no or minimal fixation artifacts; and 3) exclusion of the lateral 2-mm areas of the specimen, which are prone to artifacts. We excluded poorly oriented or directly adjacent sections. Using these selection criteria, the EMR group comprised 18 of 278 (6.5%) routine sections and the ESD group 34 of 381 (8.9%) sections for further morphometric analysis (► **Table 2**). Submucosal thickness was measured perpendicularly from the muscularis mucosae down to the vertical resection margin of the specimen in accordance with Japanese Guidelines [2]. We assessed quality and quantity of the submucosal layer in each of the clinical cases with four parameters. First, as an approach to gather information about the homogeneity (or variation) of submucosal thickness, we calculated the variation coefficient from repetitive measurement of submucosal thickness every 1000 μm . Moreover, we identified minimal submucosal thickness and maximal submucosal thickness. Finally, to obtain data on the average thickness of submucosal layer, we calculated a ratio of the area of submucosal layer $\geq 1000 \mu\text{m}$ relative to the total submucosal area (► **Fig. 1**). The 1000- μm threshold was used because it represents an important landmark for assessment of curative endoscopic resections in patients who have submucosal invasive cancer [4, 5]. Morphometric measurements were performed on scanned photographic images with a commercially available scanner system (Seiko Epson Corporation; Suwa, Nagano, Japan). Statistical calculations were carried out with Microsoft Excel (Microsoft Corporation; Redmond, Washington, United States) and the R-Studio software (R-Studio Inc.; Boston, Massachusetts, United States). Data from EMR

► **Table 2** Characteristics of specimens selected for morphometric analysis.

EMR	Sections analyzed/total, n (%)	ESD	Sections analyzed/total, n (%)
# 1	4/36(11.1%)	1	8/66(12.1%)
# 2	3/49(6.1%)	2	7/69(10.1%)
# 3	4/86(4.6%)	3	3/43(7.0%)
# 4	2/18(11.1%)	4	3/52(5.8%)
# 5	3/65(4.6%)	5	9/48(18.8%)
# 6	2/24(8.3%)	6	4/103(3.9%)
Total	18/278(6.5%)	Total	34/381(8.9%)

EMR: endoscopic mucosal resection; ESD: endoscopic submucosal dissection.

and ESD specimens were compared using a two-sided Wilcoxon-test for unpaired samples. $P < 0.05$ was considered statistically significant.

Results

The EMR group comprised specimens from three en bloc and three piecemeal resections and the ESD group en bloc resections only; all specimens were from the right colon (► **Table 1**). Histology was tubular or tubular-villous with low-grade dysplasia and one tubular-villous adenoma, with the exception of one adenoma with partial transformation into a G2 adenocarcinoma in the ESD group.

Comparative measurements from both groups showed significant differences in minimum submucosal thickness and in the fraction of resected submucosal thickness area $\geq 1000 \mu\text{m}$. No significant differences were observed in homogeneity (variation coefficient) or maximum submucosal thickness (► **Table 3**, ► **Fig. 2**).

Discussion

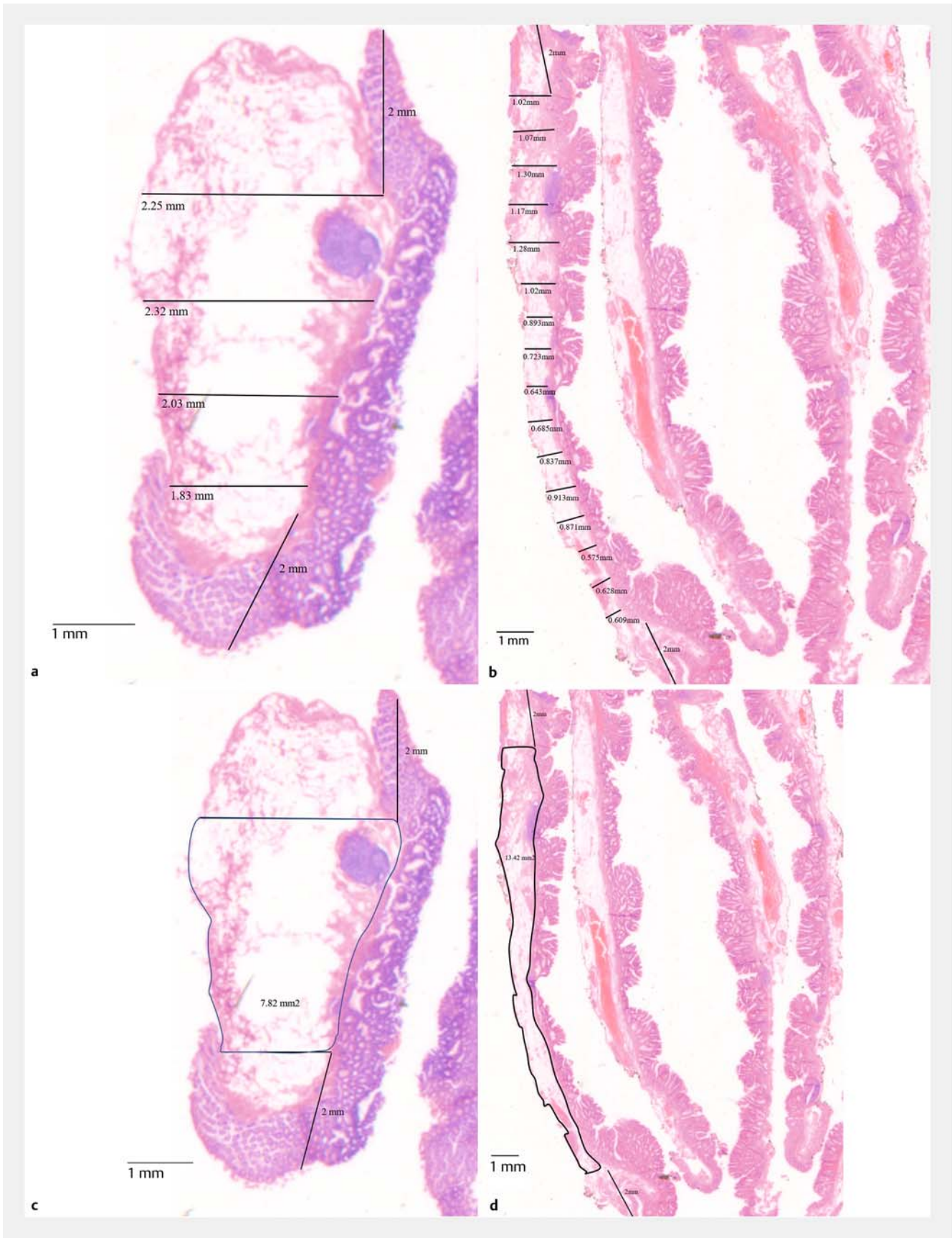
In this small pilot study, we retrospectively analyzed submucosal thickness in routine histopathology specimens obtained using EMR or ESD. We observed a significantly higher fraction of submucosal layer thickness $> 1000 \mu\text{m}$ as well as a higher mean minimal submucosal thickness for EMR specimens than for specimens obtained using ESD. No difference was found in variability of submucosal thickness or mean maximum submucosal thickness.

Although a small pilot study obviously does have limitations, these results suggest more abundant submucosal tissue in specimens obtained using EMR rather than using ESD. Several possible explanations can be considered to account for the observed differences. First, the differences might reflect different handling of specimens – in particular, stretching/pinning of en bloc specimens on corkboard versus direct collection of tissue fragments into the fixative solution. However, in our study, three of six EMR specimens were resected en bloc, which makes this an unlikely explanation. Second, variation in submucosal thickness might be due to the quantity of submucosal injection

solution. In this study, normal saline was used for submucosal injection in both EMR and ESD and the amount of submucosal fluid present in tissue specimens at the end of an endoscopic procedure would have varied greatly, particularly due to different procedure times. Nevertheless, this would probably not translate into differences in submucosal thickness because specimens are dehydrated during the pre-embedding procedure followed by paraffin embedding. Third, interindividual variability of submucosal thickness cannot be ruled out. This is an obvious limitation of the small sample size and will need to be analyzed in a larger number of specimens, including full-thickness specimens (e.g. from endoscopic full-thickness resection or laparoscopic surgery). Finally, and perhaps most likely, the observed difference could result from differences in preparation technique. ESD is carried out with dedicated knives. The cutting line will be oriented toward the mucosal layer to prevent perforation of the proper muscle, unless a lesion is suspicious for submucosal invasive cancer. In contrast, for piecemeal EMR, tissue is grasped when closing the snare around the specimen, thus possibly yielding thicker submucosal tissue.

As previously described, ESD is recommended for resection of lesions that may be malignant. This still seems to be justified, because ESD allows better definition of lateral margins and has a higher en bloc resection rate for larger flat or sessile lesions [1]. Thus, ESD will remain the method of choice for lesions confined to the mucosal layer. However, the data presented above suggest that in patients suspected to have cancer with slight submucosal infiltration, care should be taken to resect the submucosal layer close to the propria muscle layer. Alternatively, an endoscopic full-thickness resection might be considered for smaller lesions suspected to have submucosal invasion [9]. Moreover, a modified hybrid EMR technique referred to as endoscopic submucosal resection has been introduced using a newly designed, partially insulated snare that allows cutting close to the propria muscle layer [10, 11].

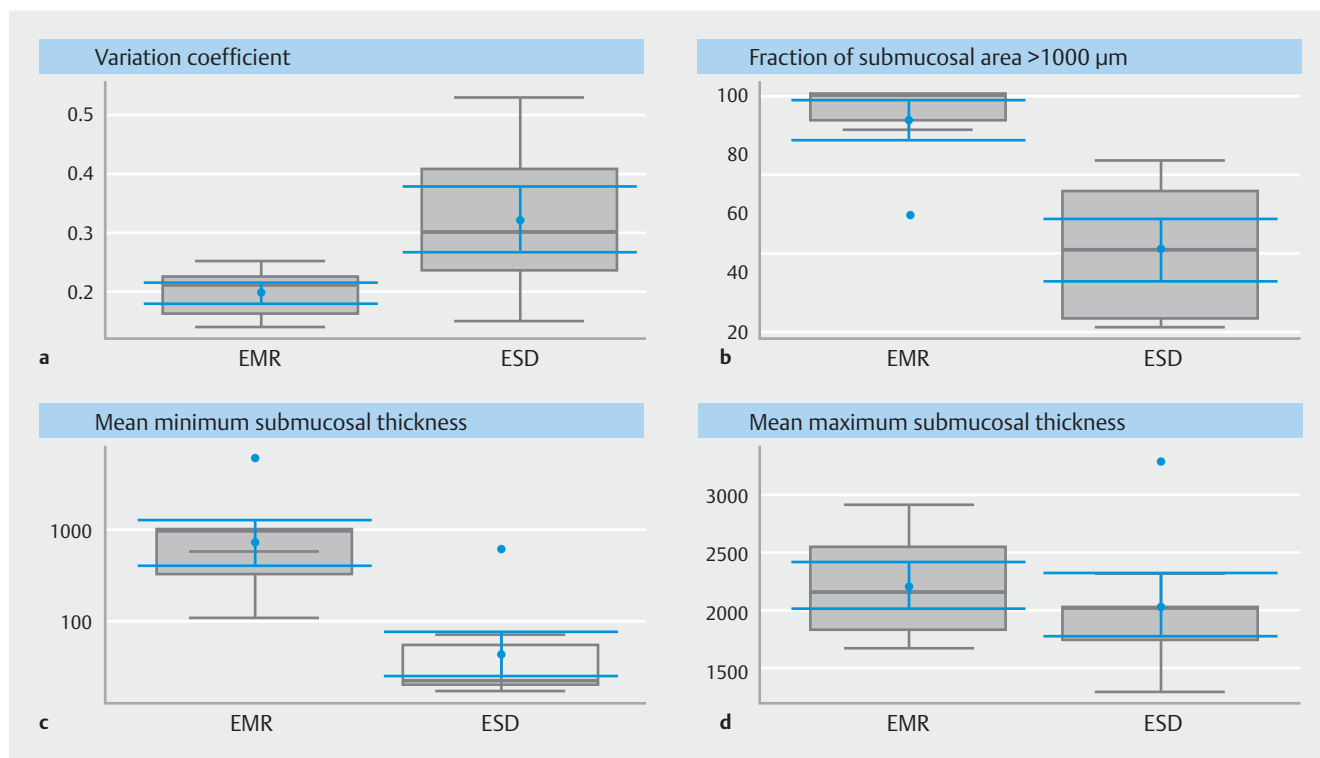
This pilot study has obvious limitations. The design was retrospective and the study comprised only a small sample size. Therefore, the quality of routine specimens was not optimal for morphometric analysis. Moreover, optimal matching of samples was not possible and, given the small sample size, differences therefore might be overestimated or underestimated.



► **Fig. 1** Representative examples of digital measurements from analyzed slices (H&E stain). **a** Measurement of submucosal thickness from an EMR specimen. **b** Measurement of submucosal thickness from an ESD specimen. **c** Measurement of submucosal area from an EMR specimen. **d** Measurement of submucosal area from an ESD specimen.

► **Table 3** Comparison of semi-quantitative measurements.

	EMR (n=6)	ESD (n=6)	P value
Variation coefficient	0.20±0.02	0.32±0.06	0.064 (n.s.)
Minimum submucosal thickness (µm)	933.67±125.12	319.00±123.62	0.009
Maximum submucosal thickness (µm)	2218.33±203.72	2055.00±274.21	0.70 (n.s.)
Submucosal area fraction ≥ 1000 µm (%)	91.20±6.65	47.13±10.62	0.018



► **Fig. 2** Results of digital measurements of specimens by EMR vs. ESD given as box and whisker plots, **a** variation coefficient, **b** fraction of submucosal area > 1000 µm, **c** mean minimum submucosal thickness, **d** mean maximum submucosal thickness.

Moreover, most procedures were done on lesions not suspected of harboring cancer. Thus, the dissection plane for ESD might have been directed toward the mucosal layer to avoid propria muscle injury, which might explain the submucosal layer was thinner in these specimens.

Conclusions

In summary, in this small pilot study of submucosa thickness, specimens obtained using EMR rather than ESD appeared to be better suited for histological analysis of submucosal infiltration. On the other hand, ESD allows better control of lateral resection margins. An ideal endoscopic resection technique should combine both optimal control of lateral resection margins and resection of the largest possible amount of submucosal tissue without increasing perforation risk. Notwithstanding the above-mentioned limitations, we think that the data will be a useful starting point for further studies of the submucosal

layer in tissue specimens obtained using different endoscopic resection techniques.

Competing interests

The authors declare that they have no conflict of interest.

References

- [1] Pimentel-Nunes P, Dinis-Ribeiro M, Ponchon T et al. Endoscopic submucosal dissection: European Society of Gastrointestinal Endoscopy (ESGE) Guideline. *Endoscopy* 2015; 47: 829–854
- [2] Tanaka S, Kashida H, Saito Y et al. Japan Gastroenterological Endoscopy Society guidelines for colorectal endoscopic submucosal dissection/endoscopic mucosal resection. *Dig Endosc* 2020; 32: 219–239

- [3] Draganov PV, Wang AY, Othman MO et al. AGA Institute Clinical Practice Update: Endoscopic Submucosal Dissection in the United States. *Clin Gastroenterol Hepatol* 2019; 17: 16–25.e11
- [4] Ichimasa K, Kudo SE, Miyachi H et al. Risk stratification of T1 colorectal cancer metastasis to lymph nodes: current status and perspective. *Gut Liver* 2021; 15: 818–826
- [5] Kouyama Y, Kudo SE, Miyachi H et al. Risk factors of recurrence in T1 colorectal cancers treated by endoscopic resection alone or surgical resection with lymph node dissection. *Int J Colorectal Dis* 2018; 33: 1029–1038
- [6] Ferlitsch M, Moss A, Hassan C et al. Colorectal polypectomy and endoscopic mucosal resection (EMR): European Society of Gastrointestinal Endoscopy (ESGE) Clinical Guideline. *Endoscopy* 2017; 49: 270–297
- [7] Kaltenbach T, Anderson JC, Burke CA et al. Endoscopic removal of colorectal lesions-recommendations by the US Multi-Society Task Force on Colorectal Cancer. *Gastroenterology* 2020; 158: 1095–1129
- [8] Russo P, Barbeiro S, Awadie H et al. Management of colorectal laterally spreading tumors: a systematic review and meta-analysis. *Endosc Int Open* 2019; 7: E239–E259
- [9] Meier B, Stritzke B, Kuellmer A et al. Efficacy and safety of endoscopic full-thickness resection in the colorectum: results from the German Colonic FTRD Registry. *Am J Gastroenterol* 2020; 115: 1998–2006
- [10] Gölder SK, Schaller T, Farin G et al. Partially insulated cutting instruments for hybrid endoscopic submucosal dissection - the Flat Adenoma Resection Instruments (FARIn). *Endoscopy* 2016; 48: E218–E219
- [11] Metter K, Aepli P, Dumoulin FL et al. Endoscopic submucosal resection (ESR) – a technique using novel devices for incision and resection of neoplastic lesions. *Endoscopy* 2021: doi:10.1055/a-1723-3194