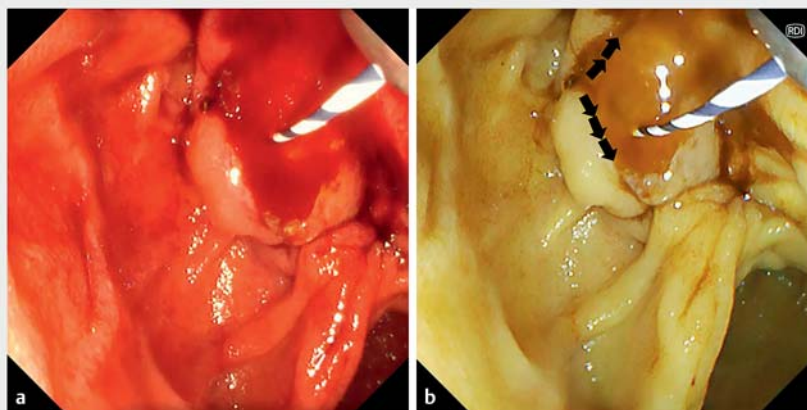


Usefulness of red dichromatic imaging for post-endoscopic sphincterotomy bleeding

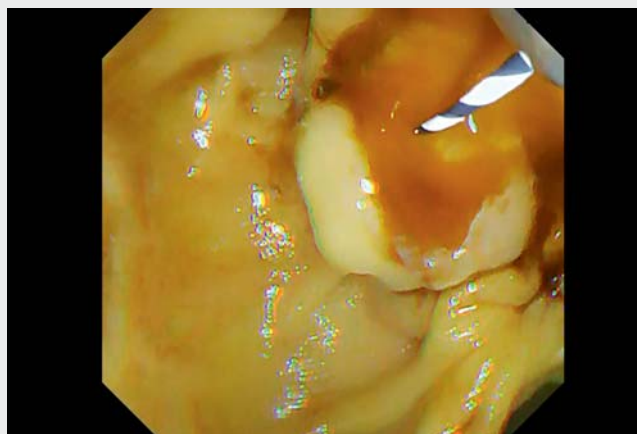


Endoscopic sphincterotomy (ES) is a crucial procedure in the treatment of biliary disease, but post-ES bleeding is an occasional adverse event [1]. Massive bleeding makes it difficult to continue the procedure, including hemostasis, because of poor visibility due to coagulum, the narrowness of the duodenum, and technical difficulty of using a side-viewing endoscope. Red dichromatic imaging, a recently developed novel image-enhanced endoscopy technology with good visualization of bleeding points and deep vessels, has been reported to be useful in various situations during upper and lower gastrointestinal endoscopy [2–5]. Herein we present a case in which red dichromatic imaging was useful for hemostasis of massive post-ES bleeding.

A 75-year-old man developed cholangitis due to bile duct stones. Endoscopic retrograde cholangiography was performed with a TJF-Q290V scope with the EVIS X1 system (Olympus Medical Systems, Tokyo, Japan). After biliary cannulation, ES was conducted with a standard sphincterotome. However, massive persistent bleeding occurred immediately. The endoscopic views of the duodenal papilla and the surroundings became red with blood, and it was impossible to identify the bleeding point clearly. The white-light imaging was therefore switched to red dichromatic imaging. The accumulated residual blood became inconspicuous, and the active blood stream and bleeding point could be visualized in darker yellow (► **Fig. 1**, ► **Video 1**). Hemostasis was achieved with a local epinephrine injection near the identified bleeding point on red dichromatic imaging. No adverse events and no re-bleeding were observed after the procedure. Red dichromatic imaging confers better visualization of bleeding points and active fresh bleeding, which appears as darker yellow in color. Moreover, pooled residual blood surrounding the active bleeding is less noticeable in red dichro-



► **Fig. 1** White-light versus red dichromatic imaging. **a** Clear endoscopic view could not be obtained with white-light imaging due to massive post-endoscopic sphincterotomy bleeding and hematoma. **b** After switching to red dichromatic imaging, the accumulated residual blood became inconspicuous, and the active blood stream (arrow) could be visualized in darker yellow, which enabled the identification of the bleeding point.



► **Video 1** Successful hemostasis of massive post-endoscopic sphincterotomy bleeding with red dichromatic imaging.


matic imaging; thus, a clear field of view can be obtained compared to white-light imaging. These features can aid hemostatic procedures and in checking whether the bleeding has stopped, even with a side-viewing endoscope and when treating post-ES bleeding.

Endoscopy_UCTN_Code_TTT_1AR_2AK

Competing interests

The authors declare that they have no conflict of interest.

The authors

Tadahisa Inoue,  **Mayu Ibusuki, Rena Kitano, Yuji Kobayashi, Kiyooki Ito, Masashi Yoneda**
Department of Gastroenterology, Aichi Medical University, Aichi, Japan

Corresponding author

Tadahisa Inoue, MD

Department of Gastroenterology, Aichi Medical University, 1-1 Yazakokarimata, Nagakute, Aichi 480-1195, Japan
Fax: +81 561 63 3208
tinoue-tag@umin.ac.jp

References

- [1] Freeman ML, Nelson DB, Sherman S et al. Complications of endoscopic biliary sphincterotomy. *N Engl J Med* 1996; 335: 909–918
- [2] Yahagi N, Fujimoto A, Horii J et al. Dual red imaging: a novel endoscopic imaging technology visualizing thick blood vessels in the gastrointestinal wall. *Endosc Int Open* 2019; 7: E1632–E1635
- [3] Miyamoto S, Ohya TR, Nishi K et al. Effectiveness of red dichromatic imaging for

dissection of the submucosal layer when hematoma is encountered. *Endoscopy* 2021; 53: E413–E414

- [4] Saino M, Aoyama T, Fukumoto A et al. Tracking the target in colonic diverticular bleeding using red dichromatic imaging. *Endoscopy* 2021; 53: E425–E426
- [5] Miyamoto S, Sugiura R, Abiko S et al. Red dichromatic imaging helps in detecting exposed blood vessels in gastric ulcer induced by endoscopic submucosal dissection. *Endoscopy* 2021; 53: E403–E404

Bibliography

Endoscopy 2022; 54: E778–E779

DOI 10.1055/a-1806-1605

ISSN 0013-726X

published online 8.4.2022

© 2022. The Author(s).

This is an open access article published by Thieme under the terms of the Creative Commons Attribution-NonDerivative-NonCommercial License, permitting copying and reproduction so long as the original work is given appropriate credit. Contents may not be used for commercial purposes, or adapted, remixed, transformed or built upon. (<https://creativecommons.org/licenses/by-nc-nd/4.0/>)

Georg Thieme Verlag KG, Rüdigerstraße 14, 70469 Stuttgart, Germany



ENDOSCOPY E-VIDEOS

<https://eref.thieme.de/e-videos>



Endoscopy E-Videos is an open access online section, reporting on interesting cases and new techniques in gastroenterological endoscopy. All papers include a high quality video and all contributions are freely accessible online. Processing charges apply (currently EUR 375), discounts and waivers acc. to HINARI are available.

This section has its own submission website at

<https://mc.manuscriptcentral.com/e-videos>