
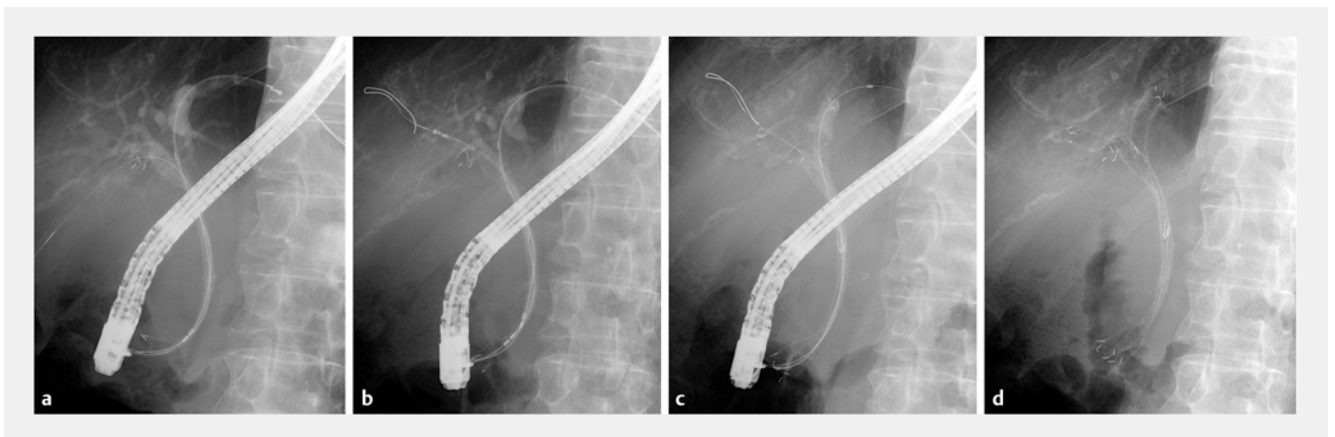


Combined stent-by-stent and stent-in-stent deployment for malignant hilar biliary obstruction using a novel metal stent with flexible cell and slim delivery

OPEN
ACCESS



► **Fig. 1** **a, b** A novel uncovered metal stent (Niti-S Multi-Purpose Type; Taewoong Medical, Seoul, Korea) has a small size cell but it is flexible, can expand markedly, which can facilitate easy passage of the stent cell in the stent-in-stent method and preventing ingrowth as much as possible. **c** The stent is mounted on a 6F slim delivery system with an ultra-tapered tip, which enables the simultaneous stent-by-stent method.

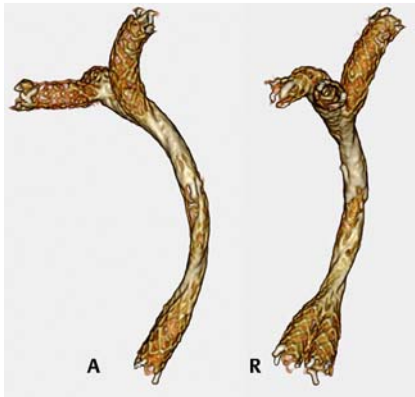


► **Fig. 2** **a** After simultaneous delivery of two insertions into the right posterior and left hepatic ducts, the posterior stent (8 × 120 mm) was deployed. **b** The posterior guidewire was subsequently advanced to the right anterior hepatic duct through the stent cell, and an additional metal stent (8 × 80 mm) was inserted and deployed into the anterior duct using the stent-in-stent method. **c, d** Finally, the left stent (8 × 120 mm) was deployed in the stent-by-stent configuration with its distal end at the same level as that of the posterior stent.

A novel uncovered metal stent (Niti-S Multi-Purpose Type; Taewoong Medical, Seoul, Korea) designed specifically for multi-stenting in patients with malig-

nant hilar biliary obstruction recently has been developed. This stent has a small size cell; however, it is flexible, can expand markedly, and has a 6-F slim de-

livery system (► **Fig. 1**). Therefore, the stent makes passing stent cells easier in the stent-in-stent (SIS) method, while possibly preventing tumor ingrowth bet-



► **Fig. 3** Three-dimensional reconstruction after the combined stent-by-stent and stent-in-stent deployment.

ter than larger-cell stents. Moreover, the stent enables simultaneous insertion of two delivery systems, making the stent-by-stent (SBS) method straightforward [1]. Therefore, this novel stent is “multi-purpose,” i. e., it can be suitable for both SBS and SIS; thus, it can also be particularly useful for the combined SBS and SIS technique [2–5].

An 88-year-old man developed obstructive jaundice due to extrahepatic cholangiocarcinoma. Endoscopic retrograde cholangiography revealed severe Bismuth type IIIa stricture, which extended to the lower bile duct. After two guidewire placements into the right posterior and left hepatic ducts, two delivery systems of the novel stent were simultaneously inserted through the stricture. Subsequently, the posterior stent was deployed transpapillary across the stricture, and a catheter was progressively advanced over the posterior guidewire. The guidewire was inserted into the right anterior hepatic duct through the stent cell, and an additional stent was inserted and subsequently deployed in the SIS method. Finally, the left stent was deployed in the SBS configuration, with its distal end at the same level as that of the posterior stent (► **Fig. 2**, ► **Fig. 3**, ► **Video 1**). The patient’s symptoms improved without the occurrence of adverse events, and recurrent biliary obstruction was not observed during the follow-up period.

This study described the use of a multi-purpose metal stent for malignant hilar biliary obstruction. This novel stent can

► **VIDEO**

Combined stent-by-stent and stent-in-stent deployment for malignant hilar biliary obstruction using a novel metal stent with dual lumen and slim delivery

Tadahisa Inoue, Mayu Ibusuki, Rena Kitano, Yuji Kobayashi, Kiyooki Ito, Masashi Yoneda
Department of Gastroenterology, Aichi Medical University, Aichi, Japan

► **Video 1** Combined stent-by-stent and stent-in-stent method using a novel multi-purpose metal stent for a patient with malignant hilar biliary obstruction.

serve as a useful option while using any multi-stenting method.

Competing interests

The authors declare that they have no conflict of interest.

The authors

Tadahisa Inoue, Mayu Ibusuki, Rena Kitano, Yuji Kobayashi, Kiyooki Ito, Masashi Yoneda
Department of Gastroenterology, Aichi Medical University, Aichi, Japan

Corresponding author

Tadahisa Inoue, MD, PhD, FJGES
Department of Gastroenterology, Aichi Medical University, Yazakokarimata, Nagakute, Aichi 480-1195, Japan
Fax: +81 561 63 3208
tinoue-tag@umin.ac.jp

References

- [1] Inoue T, Ishii N, Kobayashi Y et al. Simultaneous versus sequential side-by-side bilateral metal stent placement for malignant hilar biliary obstructions. *Dig Dis Sci* 2017; 62: 2542–2549
- [2] Maruki Y, Hijioka S, Wu SYS et al. Novel endoscopic technique for trisegment drainage in patients with unresectable hilar malignant biliary strictures (with video). *Gastrointest Endosc* 2020; 92: 763–769

- [3] Saito T, Kanai S, Hamada T et al. Combined stent-in-stent and side-by-side stenting for hilar cholangiocarcinoma using a novel braided and weaving metal stent. *Endoscopy* 2020; 52: E150–E151
- [4] Inoue T, Ibusuki M, Kitano R et al. Combined side-by-side and stent-in-stent method for triple metal stenting in patients with malignant hilar biliary obstruction. *Dig Endosc* 2019; 31: 698–705
- [5] Inoue T, Kitano R, Yoneda M. Modified combined stent-by-stent and stent-in-stent method for tri-sectoral metal stenting in patients with malignant hilar biliary obstruction. *Dig Endosc* 2020; 32: e167–e168

Bibliography

Endosc Int Open 2022; 10: E917–E918

DOI 10.1055/a-1793-9775

ISSN 2364-3722

© 2022. The Author(s).

This is an open access article published by Thieme under the terms of the Creative Commons Attribution-NonDerivative-NonCommercial License, permitting copying and reproduction so long as the original work is given appropriate credit. Contents may not be used for commercial purposes, or adapted, remixed, transformed or built upon. (<https://creativecommons.org/licenses/by-nc-nd/4.0/>)

Georg Thieme Verlag KG, Rüdigerstraße 14, 70469 Stuttgart, Germany

