

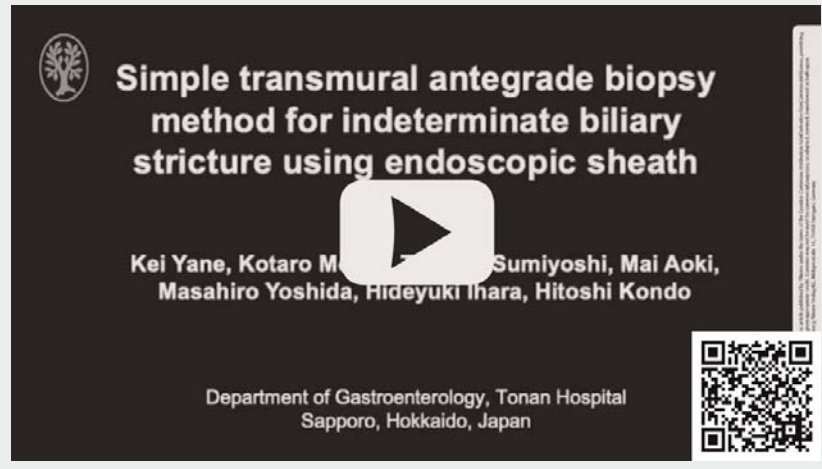## Simple transmural antegrade biopsy method for indeterminate biliary stricture using endoscopic sheath ▶

OPEN  
ACCESS

Histological examination is necessary to determine the treatment strategy for indeterminate bile duct stricture. In cases of surgically altered anatomy, balloon enteroscopy-assisted endoscopic retrograde cholangiopancreatography (ERCP) is useful. However, its success rate is limited in cases with malignant stricture [1]. Although transmural antegrade biopsy has been reported, it requires a special biopsy forceps and a mature hepaticogastrostomy fistula [2]. Recently, the usefulness of an endoscopic sheath has been reported for selective biliary biopsy (▶ Fig. 1) [3,4]. Herein, we describe a successful simple and one-step transmural antegrade biopsy method for indeterminate biliary stricture using this endoscopic sheath.

A 70-year-old man who underwent gastric jejunal bypass for benign duodenal stricture due to a duodenal ulcer scar was admitted for obstructive jaundice. Although computed tomography showed bile duct and pancreatic duct dilation, no obvious tumor could be identified (▶ Fig. 2). Simultaneous endoscopic ultrasound (EUS)-guided transmural bile duct biopsy with biliary stenting was attempted. After puncturing the intrahepatic bile duct using a 22-gauge FNA needle, the distal bile duct stricture was confirmed. Following guidewire placement using a double-lumen catheter (Uneven Double Lumen Cannula; Piolax Medical Devices, Kanagawa, Japan), an endoscopic sheath (Endosheather; Piolax Medical Devices) was inserted and advanced directly above the stricture (▶ Fig. 3). A biopsy forceps (Radial Jaw 4 Pediatric; Boston Scientific, Natick, Massachusetts, United States) was inserted, and five biopsies were performed (▶ Fig. 4, ▶ Video 1). All five biopsies were performed within 5 minutes after the Endosheather insertion. Finally, a 7F, 14-cm plastic stent (Through and Pass, TYPE-IT, Gadelius Medical Co. Ltd., Tokyo, Japan) was placed (▶ Fig. 5). Histological examina-

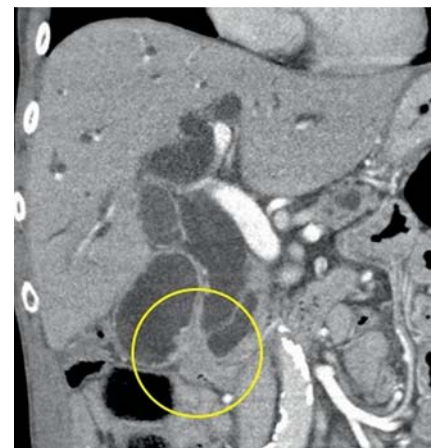### ▶ VIDEO



▶ **Video 1** Transmural antegrade biopsy was performed using an endoscopic sheath. After puncturing the intrahepatic bile duct using a 22-gauge FNA needle, a distal bile duct stricture was confirmed. The endoscopic sheath was inserted and advanced directly above the stricture. The biopsy forceps was inserted, and five biopsies were performed. All five biopsies were performed within 5 minutes after the endoscopic sheath insertion. Finally, a 7F, 14-cm plastic stent was placed.

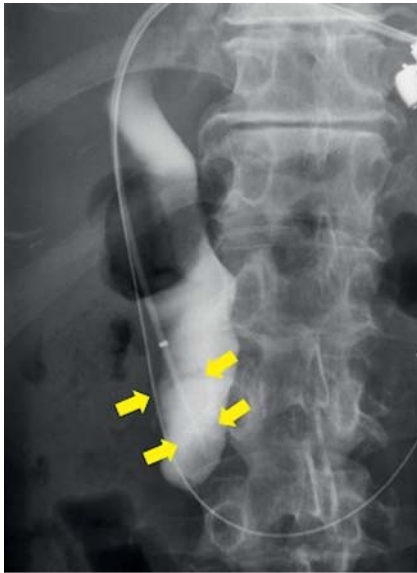

▶ **Fig. 1** The biopsy forceps (Radial Jaw 4 Pediatric; Boston Scientific, Natick, Massachusetts, United States; inner diameter 1.8 mm) inserted into an endoscopic sheath (Endosheather; Piolax Medical Devices; outer diameter 7.2F (2.4 mm); inner diameter 2.06 mm).

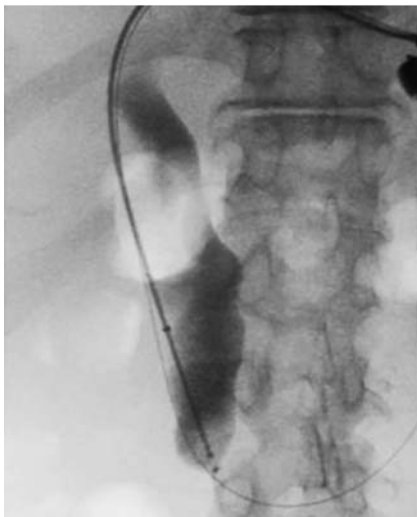

▶ **Fig. 2** Computed tomography showed bile duct and pancreatic duct dilation. However, no obvious tumor could be identified (yellow circle).

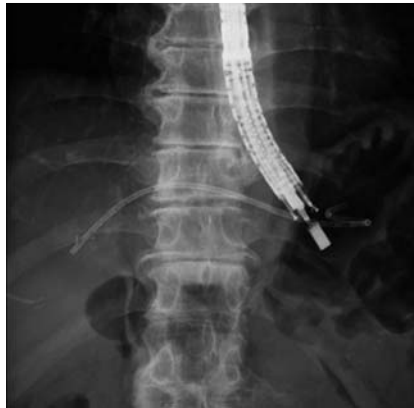tion revealed adenocarcinoma. After malignancy confirmation, we placed metal stents via a hepaticogastrostomy fistula (▶ Fig. 6). This method is promising because it is simple, and it is easy to perform multiple biopsies during EUS-guided hepaticogastrostomy with little concern for bile leakage.



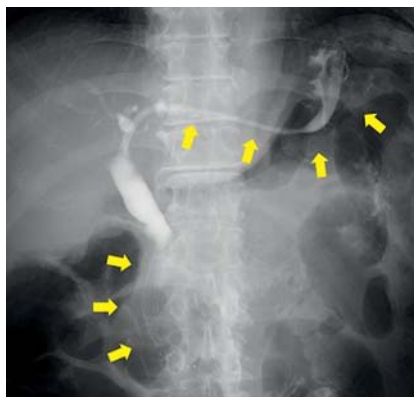
► **Fig. 3** The endoscopic sheath was inserted into the bile duct and advanced directly above the stricture (yellow arrows).



► **Fig. 4** The biopsy forceps (Radial Jaw 4 Pediatric; Boston Scientific, Natick, Massachusetts, United States) was inserted, and five biopsies were performed.



► **Fig. 5** A 7F 14-cm plastic stent was placed.



► **Fig. 6** Following diagnosis, we performed antegrade stent placement across the papilla and hepaticogastrostomy stent placement via a hepaticogastrostomy fistula (yellow arrows).

- [3] Matsumori T, Uza N, Shiokawa M et al. Mapping biopsy for bile duct cancer using a novel device delivery system. *Endoscopy* 2021; doi:10.1055/a-1479-1969
- [4] Yane K, Sumiyoshi T, Kondo H. Transpapillary gallbladder biopsy using newly designed endoscopic sheath. *Dig Endosc* 2021; doi:10.1111/den.14095

#### Bibliography

*Endosc Int Open* 2022; 10: E1309–E1310

DOI 10.1055/a-1793-9454

ISSN 2364-3722

published online 10.3.2022

© 2022. The Author(s).

This is an open access article published by Thieme under the terms of the Creative Commons Attribution-NonDerivative-NonCommercial License, permitting copying and reproduction so long as the original work is given appropriate credit. Contents may not be used for commercial purposes, or adapted, remixed, transformed or built upon. (<https://creativecommons.org/licenses/by-nc-nd/4.0/>)

Georg Thieme Verlag KG, Rüdigerstraße 14, 70469 Stuttgart, Germany



#### Corresponding author

##### Kei Yane, MD

Department of Gastroenterology, Tonan Hospital, 3-8 Kita-4 Nishi-7, Chuo-ku, Sapporo 060-0004, Japan  
Fax: +81-11-231-5000  
k.yane3@gmail.com

#### Competing interests

The authors declare that they have no conflict of interest.

#### The authors

Kei Yane<sup>1</sup>, Kotaro Morita<sup>1</sup>, Tetsuya Sumiyoshi<sup>1</sup>, Mai Aoki<sup>1</sup>, Masahiro Yoshida<sup>1</sup>, Hideyuki Ihara<sup>1</sup>, Hitoshi Kondo<sup>1</sup>

<sup>1</sup> Department of Gastroenterology, Tonan Hospital, Sapporo, Hokkaido, Japan

#### References

- [1] Tanisaka Y, Ryozaawa S, Mizuide M et al. Analysis of the factors involved in procedural failure: Endoscopic retrograde cholangiopancreatography using a short-type single-balloon enteroscope for patients with surgically altered gastrointestinal anatomy. *Dig Endosc* 2019; 31: 682–689
- [2] Ogura T, Okuda A, Nishioka N et al. Transluminal antegrade biopsy using a novel forceps biopsy device for hepaticojejunostomy stricture. *Endoscopy* 2021; 53: E269–E270