

# Improved detection of early gastric cancer with linked color imaging using an ultrathin endoscope: a video-based analysis




## Authors

Tsevelnorov Khurelbaatar<sup>1,2</sup>, Yoshimasa Miura<sup>1</sup>, Hiroyuki Osawa<sup>1</sup>, Yuji Ino<sup>1</sup>, Takahito Takezawa<sup>1</sup>, Chihiro Iwashita<sup>1</sup>, Yoshie Nomoto<sup>1</sup>, Masato Tsunoda<sup>1</sup>, Takashi Ueno<sup>1</sup>, Haruo Takahashi<sup>1</sup>, Manabu Nagayama<sup>1</sup>, Hisashi Fukuda<sup>1</sup>, Alan Kawarai Lefor<sup>3</sup>, Hironori Yamamoto<sup>1</sup>

## Institutions

- 1 Division of Gastroenterology, Department of Medicine, Jichi Medical University, Shimotsuke, Tochigi, Japan
- 2 Mongolia-Japan Hospital, Mongolian National University of Medical Sciences, Ulaanbaatar, Mongolia
- 3 Department of Surgery, Jichi Medical University, Shimotsuke, Tochigi, Japan

submitted 30.8.2021

accepted after revision 20.12.2021

## Bibliography

Endosc Int Open 2022; 10: E644–E652

DOI 10.1055/a-1793-9414

ISSN 2364-3722


© 2022. The Author(s).

This is an open access article published by Thieme under the terms of the Creative Commons Attribution-NonDerivative-NonCommercial License, permitting copying and reproduction so long as the original work is given appropriate credit. Contents may not be used for commercial purposes, or adapted, remixed, transformed or built upon. (<https://creativecommons.org/licenses/by-nc-nd/4.0/>)

Georg Thieme Verlag KG, Rüdigerstraße 14,  
70469 Stuttgart, Germany

## Corresponding author

Hiroyuki Osawa, Division of Gastroenterology, Department of Medicine, Jichi Medical University, 3311-1 Yakushiji, Shimotsuke, Tochigi 329-0498, Japan  
Fax: +81-285-44-0047  
[osawa@jichi.ac.jp](mailto:osawa@jichi.ac.jp)

 Supplementary material is available under  
<https://doi.org/10.1055/a-1793-9414>

## ABSTRACT

**Background and study aims** Ultrathin endoscopy causes a minimal gag reflex and has minimal effects on cardiopulmonary function. Linked color imaging (LCI) is useful for detection of malignancies in the digestive tract. The aim of this study was to clarify whether LCI with ultrathin endoscopy facilitates detection of early gastric cancer (EGC) despite its lower resolution compared with high-resolution white light imaging (WLI) with standard endoscopy.

**Patients and methods** This was a retrospective analysis with prospectively collected video, including consecutive 166 cases of EGC or gastric atrophy alone. Ninety seconds of screening video was collected using standard and ultrathin endoscopes with both WLI and LCI for each case. Three expert endoscopists assessed each video and the sensitivity of detecting EGC calculated. Color difference calculations were performed.

**Results** Sensitivities using ultrathin WLI, ultrathin LCI, standard WLI, and standard LCI for the identification of cancer were 66.0%, 80.3%, 69.9%, and 84.0%, respectively. The color difference between malignant lesions and surrounding mucosa with ultrathin LCI and standard LCI were significantly higher than using ultrathin WLI or standard WLI, supported subjectively by the visibility score. Ultrathin LCI color difference and visibility score were significantly higher than standard WLI.

**Conclusions** LCI with a low-resolution ultrathin endoscope is superior to WLI with a high-resolution standard endoscope for gastric cancer screening. This suggests that the high color contrast between EGC and the surrounding mucosa is more important than high-resolution images.

## Introduction

Gastric cancer screening endoscopy was established using white light imaging (WLI) and standard endoscopy via the transoral route. Ultrathin endoscopy ( $\leq 6$  mm diameter) has

been used mainly via the transnasal route since the early 2000s because of minimal pain and gag reflex during the examination [1, 2]. It is well tolerated without sedation and is less costly [3–5]. Ultrathin endoscopy via the transnasal route is considered a safer procedure with less effect on the cardiopul-

monary function of elderly patients including blood pressure and pulse rate [2, 6, 7]. Therefore, ultrathin endoscopy is used mainly in private clinics and for routine health evaluations in Japan [8]. However, there is a trade-off between the resolution of the images and the smaller caliber endoscope using WLI. The diagnostic accuracy using an ultrathin endoscope and WLI is lower than with a standard endoscope and WLI for the detection of gastric neoplasms [9]. There is concern that lower-quality images may result in the inability to diagnose malignant lesions of the upper gastrointestinal tract in routine outpatient practice, which has resulted in hesitation to use this modality [8, 10–13]. Improvements in optical quality and the incorporation of additional procedures including chromoendoscopy have been required to enhance visualization [9].

Recently, while standard WLI (that is, a standard-size endoscope using WLI) provides high-resolution images, image-enhanced endoscopy has progressed for both detailed examinations and screening for gastrointestinal malignancies. Linked color imaging (LCI) has been reported to enhance the visibility of early gastric cancer (EGC), esophageal cancer, and flat colorectal lesions. A prospective multicenter study revealed that LCI could detect upper gastrointestinal cancers that were missed using WLI [14]. LCI produces enough light to illuminate an area with a large lumen such as in the stomach and improves the color contrast between a lesion and the surrounding mucosa. If LCI with an ultrathin endoscope provides a similar advantage, it would be ideal for gastric cancer screening especially in the elderly and/or patients with cardiopulmonary dysfunction. Many endoscopists may consider that high-resolution standard endoscopy is superior to ultrathin endoscopy, to avoid missing EGCs. However, together with the high color contrast produced by LCI, it is unknown how significant the lower resolution images obtained with ultrathin endoscopy actually is when compared with standard endoscopy. It is necessary to determine which is more important during the short amount of time allotted to screening endoscopy, high-resolution images or high color contrast using LCI.

This point of uncertainty led to the conduct of this study using prospectively collected videos using both WLI and LCI modes of EGCs and atrophic gastritis using standard and ultrathin endoscopes. We designed this study to assess the sensitivity and specificity for the detection of EGCs with each mode by expert endoscopists as well as visibility. The objective color differences between malignant lesions and the surrounding mucosa were then calculated comparing WLI and LCI with both ultrathin and standard endoscopes.

## Patients and methods

### Study design

The current study was registered as a clinical trial (University Hospital Medical Information Network Clinical Trials Registry number UMIN 000028328). The study protocol and its revision (adding an author) were reviewed and approved by the Institutional Review Board of Jichi Medical University Hospital (Numbers A15–241 and A20–032, respectively). This was a retrospective analysis of prospectively collected video data including

malignant gastric lesions with chronic gastritis and chronic gastritis alone from June 2016 to July 2017.

The purpose of this study was to evaluate LCI with ultrathin and standard endoscopy and its ability to facilitate the detection of EGCs compared with WLI endoscopy.

### Study outcome and sample size

The primary endpoint of this study was the sensitivity of EGC detection using LCI with ultrathin and standard endoscopy. The secondary endpoints included: (1) the color difference between EGC and surrounding mucosa using WLI and LCI; (2) visibility differences for EGC comparing images from an ultrathin endoscope and a standard endoscope using WLI and LCI.

Based on an expected 25% difference in the endoscopic detection of EGC with WLI versus LCI using G power ( $\alpha=0.05$ ,  $\beta=0.2$ ), we estimated that a sample size of 56 patients with EGC would be sufficient to demonstrate a significant difference using StatFlex version 6.0 software (Artech) [9]. Considering 30% synchronous lesions and 10% excluded cases we sought to collect 95 gastric cancer cases. There were 95 EGC cases accrued from June 2016 to July 2017. We collected consecutive screening videos taken with WLI and LCI including non-cancer cases.

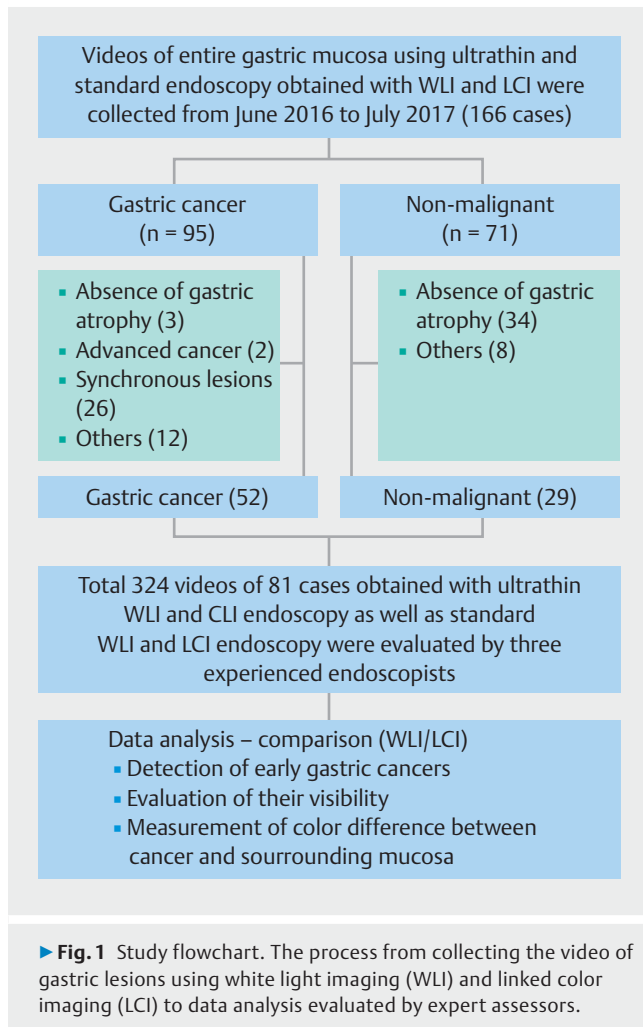
### Patients and endoscopic procedure

One hundred sixty-six consecutive patients requiring detailed upper gastrointestinal endoscopic examinations referred from smaller clinics or hospitals were enrolled except patients with a history of gastric surgery. Written informed consent was obtained from each patient before the procedure. Inclusion criteria included: (1) patients with a single EGC in the background mucosa with atrophy; and (2) patients with atrophic gastritis but without a malignant lesion in the stomach. We have excluded cases with synchronous cancers, advanced cancer, non-atrophic stomach, inadequate video and no report of ESD pathology.

Repeat informed consent was deemed necessary and eight participants could not be contacted or chose not to be included in the study. Finally, a total of 81 cases with 52 EGCs and 29 with atrophic gastritis alone were included in the final analysis (► Fig. 1).

Four experienced endoscopists (HO, YI, YM, and TT) performed gastric screening endoscopy under the same protocol with an ultrathin endoscope (EG-L580NW, 5.9 mm in diameter), and a standard endoscope (EG-L590WR, 9.6 mm). Videos were taken with standard WLI, standard LCI, ultrathin WLI, and ultrathin LCI in order. First, endoscopists observed from the gastric body to the pyloric ring in an antegrade view followed by antrum to fornix and inversely in a retrograde view, and subsequently from antrum to upper body in an antegrade view by withdrawing the endoscope within 90 seconds. Still images were not taken to decrease the bias of highlighting lesions depending on the location [15].

Approximately 90 seconds of gastric screening videos (► Video 1) in each mode were obtained without still images (a total of 4 videos/patient) to be reviewed later by expert assessors. Subsequently, precise endoscopic examinations were

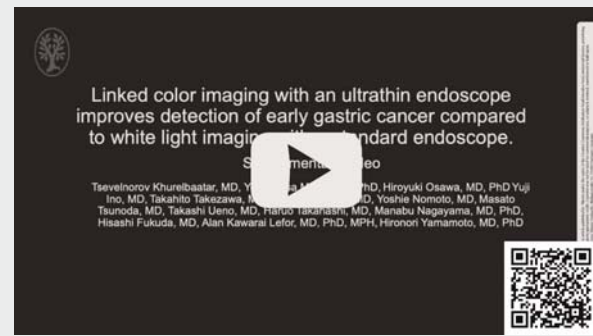


carried out with the equipment necessary for detailed diagnosis such as a magnifying endoscope and endoscopic ultrasound. The procedure was carried out under conscious sedation with intravenous midazolam and pethidine hydrochloride injection.

### Evaluation of endoscopic videos

Endoscopic videos were arranged in random order with a wash-out period of 3 weeks for the same case. Three expert endoscopists with at least 2 years of detailed endoscopic examination experience using laser endoscopy with no prior knowledge of the study cases evaluated the videos only once without a time limit with free review. They were asked to check whether EGC was present and complete a case report form. If they suspected or detected a malignant lesion, a visibility score was assigned as follows: score 3, excellent (video was viewed one time); score 2, good (video was viewed two times); score 1, fair (video was viewed three times or more) in reference to a previously described procedure for the evaluation of endoscopic videos [16]. To make the score descriptions accurate, endoscopists were asked to stop the video, record the time, and draw the location of the lesion on the screen simulation area in the case report form. All suspected lesions were carefully double-checked with corresponding pathology reports and ESD reports. If the

### VIDEO



► **Video 1** Representative videos of early gastric cancers obtained using white light imaging (WLI) and linked color imaging (LCI) by ultrathin endoscope and standard endoscope.

lesion was missed the visibility score was scored as “0”. Representative endoscopic videos are shown in ► **Video 1**.

Endoscopic findings of malignant lesions were defined based on the Japanese gastric cancer treatment guidelines and the Japanese Classification of Gastric Carcinoma. Well- and moderately-differentiated tubular adenocarcinoma and papillary adenocarcinoma were classified as the differentiated type, and poorly differentiated adenocarcinoma and signet ring cell carcinoma as the undifferentiated type. The locations were classified according to the trisected portions of the stomach: proximal, middle and distal portions. The macroscopic classification was as follows: 0-I and/or 0-IIa as elevated type, 0-IIb flat type, 0-IIc and/or 0-III depressed type. Successful eradication was determined by a history of *Helicobacter pylori* eradication and confirmed either by serum immunoglobulin level or stool antigen test. Depth is recorded based on the final pathology report of the resected specimen, tumor confined to the mucosa or invasion into the muscularis mucosa as M, tumor invasion within 0.5 mm into the submucosa as SM1 and tumor invasion of 0.5 mm or more deep into the submucosa as SM2.

### Color difference calculations

Similar images of EGCs were captured from the videos and analyzed objectively based on the  $L^*a^*b^*$  ( $L^*$  = light/dark;  $a^*$  = red-green;  $b^*$  = yellow-blue) color values in the CIELAB system using Adobe Photoshop CC2019 as previously reported [17–19]. The five regions of interest (ROI; 20x20 pixels) were selected at random from malignant lesions and then their adjacent surrounding mucosae from standard WLI, standard LCI, ultrathin WLI and ultrathin LCI images. To avoid selection bias as much as possible, these selections and calculations were performed by a single operator who can recognize malignant lesions on endoscopic images. The average of five median RGB values for five sample points was calculated in each region. The  $L^*a^*b^*$  values were calculated from the average RGB values. The color difference ( $\Delta E^* = [(\Delta L^*)^2 + (\Delta a^*)^2 + (\Delta b^*)^2]^{1/2}$ ) of the pixel values was analyzed to evaluate color contrast between malignant lesions and surrounding mucosa using ultrathin WLI, ultrathin LCI,

standard WLI and standard LCI, respectively. Color differences were classified based on the size of the malignant lesion, morphology, location, *H. pylori* status, histology and depth of lesions histologically evaluated using the resected specimens.

## Resolution measurement of ultrathin and standard endoscopes

The resolution using ultrathin endoscopy compared with standard endoscopy has not been studied in detail. As an initial investigation, we compared the resolution between a standard endoscope (EG-L590WR) and an ultrathin endoscope (EG-L580NW) because the data associated with gastric screening have not been objectively reviewed. The standard industry testing protocols for image resolution (United States Air Force-1951 test target) were used to confirm differences in resolution [20, 21]. The ratios of resolution were measured at a near view of 10 mm, mid-distant view of 20 mm, and a far-distant view of 50 mm from the resolution chart, simulating the distance between the endoscope and target gastric mucosa during screening endoscopy (**Supplementary Materials**).

## Statistical analysis

Statistical analyses were carried out using Stata 16 (version for Windows, StataCorp, Texas, United States) and Graphpad Prism Version 9 software (Graphpad software, La Jolla, California, United States). Levels of color differences and values of  $L^*$ ,  $a^*$  and  $b^*$  were expressed as the mean ( $\pm$ standard deviation). Comparisons between four modes were made using the one-way Analysis of Variance (ANOVA) with Bonferroni post-hoc test for significance between paired groups. Significant differences were assumed if  $P < 0.05$  was obtained. The distribution of visibility scores was compared between WLI and LCI using the linear-by-linear chi-squared test.  $P < 0.05$  was considered significant.

## Results

### Patients

Patient baseline and lesion characteristics are shown in **Table 1**. There were 52 patients with single EGC lesions with atrophic gastritis. Of the 29 patients without gastric malignancy but with gastric atrophy, eight had esophageal lesions, seven had duodenal lesions, six had gastric submucosal tumors and eight had atrophic gastritis alone.

### Sensitivities and specificities of LCI and WLI for detecting EGC

Ultrathin WLI, ultrathin LCI, standard WLI, and standard LCI showed sensitivities of 66.0%, 80.3%, 69.9% and 84.0% and specificities of 67.8%, 59.3%, 59.8% and 50.6%, respectively for the detection of EGCs (**Table 2**). Sensitivity with ultrathin WLI was slightly lower than with standard WLI similar to a previous report [9]. Sensitivities with LCI were higher than those with WLI using both ultrathin and standard endoscopes for all three endoscopists. Sensitivities with ultrathin LCI were also higher than those with standard WLI for all three endoscopists. Specificities were lower for LCI than those with WLI and were different among the three endoscopists. **Fig. 2** shows repre-

**Table 1** Baseline characteristics of study patients.

Number of patients, n	81
Gender (male/female)	64/17
Age, median (range)	70 (44–89)
Early gastric cancer, n	52
Location	
▪ Proximal/middle/distal	5/14/33
Morphology	
▪ Elevated/flat/depressed	12/4/36
Size	
▪ $\leq 10$ mm/11–20 mm/21–30 mm/30 mm <	14/14/9/15
<i>H. pylori</i> status	
▪ Positive/eradicated/unknown	32/14/6
Histology	
▪ Differentiated/Undifferentiated	48/4
Depth	
▪ M/SM1/SM2	41/4/7
Non-malignant, n	
▪ Atrophic gastritis	8
▪ Esophageal lesion	8
▪ Duodenal lesion	7
▪ Gastric submucosal tumor	6
Atrophy, n	
▪ Closed/open	14/67
M, tumor confined to the muscularis mucosa or invasion into the muscularis mucosa; SM1, tumor invasion within 0.5 mm into the submucosa; SM2, tumor invasion of 0.5 mm or more deep into the submucosa.	

sentative images of EGCs using WLI and LCI, which are captured from the respective video recordings. The interobserver agreement was measured using the kappa statistics. The interobserver agreement for standard WLI was 0.51, for standard LCI was 0.28, for ultrathin WLI was 0.47, and for ultrathin LCI was 0.31 and judged to have “fair to moderate agreement”.

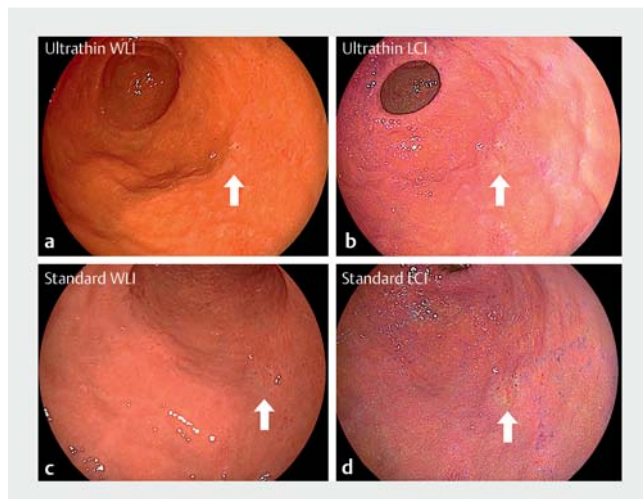### Visibility scores for malignant lesions

Mean visibility scores for malignant lesions ( $n = 52$ ) were  $1.76 \pm 1.15$  and  $2.32 \pm 0.98$  for ultrathin WLI and LCI, and  $1.94 \pm 1.09$  and  $2.49 \pm 0.84$  for standard WLI and LCI, respectively. The distributions of visibility scores were compared using each mode and evaluated using the linear-by-linear association chi square test (**Fig. 3**). Visibility scores were higher with LCI than with WLI for both ultrathin ( $P < 0.001$ ) and standard endoscopes ( $P < 0.001$ ). LCI with an ultrathin endoscope resulted in a significantly higher visibility score than WLI with a standard endoscope ( $P = 0.001$ ).

► **Table 2** Sensitivity and specificity of white light imaging and linked color imaging with standard and ultrathin endoscopes.

	Ultrathin WLI	Ultrathin LCI	Standard WLI	Standard LCI
Sensitivity (%)	66.0%	80.3%	69.9%	84.0%
Specificity (%)	67.8%	59.3%	59.8%	50.6%
Expert endoscopist 1				
Sensitivity (%)	75.0%	84.6%	78.8%	88.5%
Specificity (%)	55.2%	41.4%	48.3%	27.6%
Expert endoscopist 2				
Sensitivity (%)	65.4%	81.1%	71.2%	82.7%
Specificity (%)	58.6%	50.0%	44.8%	41.4%
Expert endoscopist 3				
Sensitivity (%)	57.7%	75.0%	59.6%	80.8%
Specificity (%)	89.7%	86.2%	86.2%	82.8%

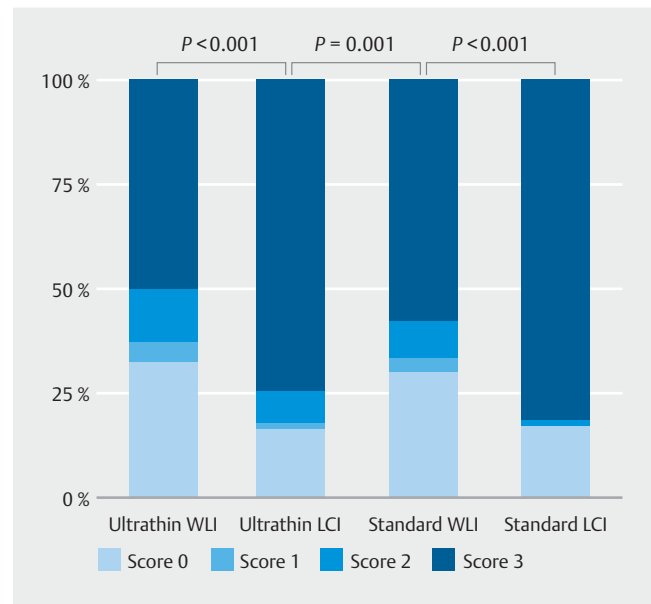
WLI, white light imaging; LCI, linked color imaging.



► **Fig. 2** Representative images of early gastric cancers obtained using white light imaging (WLI) and linked color imaging (LCI). **a** Compared with WLI using an ultrathin endoscope, **b** LCI produces image with a high color contrast (white arrow) between the malignant lesion and the surrounding mucosa. Similar images are found using **c** WLI and **d** LCI using a standard endoscope.

### Color differences between malignant lesion and surrounding mucosa

Color differences with LCI were significantly higher than those with WLI for both ultrathin and standard endoscopes ( $P < 0.001$ ) (► **Table 3**). LCI with an ultrathin endoscope resulted in significantly higher color differences than WLI with a standard endoscope ( $P < 0.001$ ). Significantly higher color difference using ultrathin LCI were found regardless of *H. pylori* status and the size of the malignant lesion (► **Table 3**). In the mid- and distal stomach, elevated and depressed type, differentiated type, depth within mucosa, the color difference with ultrathin LCI mode was significantly higher than with standard WLI (► **Table 3**).



► **Fig. 3** Distribution of visibility scores showing the superiority of linked color imaging (LCI) compared to white light imaging (WLI) as assessed by expert endoscopists. Scores from 0 to 3 indicate missed, fair, good, and excellent visibility, respectively. Statistical values are calculated by the linear-by-linear association chi square test.

The purple surrounding mucosae, mainly corresponding to intestinal metaplasia, are considered to influence the color difference [17, 18] and we therefore evaluated the ratio of purple color to the entire circumference of the malignant lesion. The number of lesions with ratios  $\leq 50\%$ ,  $50\%$  to  $75\%$  and  $\geq 75\%$  was 31, 3, and 18, respectively. We assessed three cases with gastric cancers missed using standard WLI by more than two endoscopists but detected by ultrathin LCI (► **Fig. 4**). The first case had an inflammatory map-like redness near a small, depressed cancer on the lesser curvature of the gastric midbody. The sec-

► **Table 3** Comparison of color differences between malignant lesions and the surrounding mucosa with white light imaging (WLI) and linked color imaging (LCI) (n = 51).

	Ultrathin WLI	Ultrathin LCI	Standard WLI	Standard LCI	P value	Ultrathin WLI vs Ultrathin LCI	Standard WLI vs Standard LCI	Ultrathin LCI vs Standard WLI
Total lesions (n = 51)								
ΔE	6.9 (3.6)	11 (4.5)	6.6 (3.7)	12 (4.9)	<0.001 <sup>1</sup>	<0.001 <sup>1</sup>	<0.001 <sup>1</sup>	<0.001 <sup>1</sup>
▪ ΔL	-0.6 (3.6)	-0.1 (4.7)	-0.01 (3.4)	-0.6 (4.8)	ns			
– Malignant lesion	143.5 (21.1)	159.5 (17.6)	138 (18)	157.2 (17.7)				
– Surrounding lesion	145.1 (20.5)	159.5 (16.9)	138,4 (18.4)	158.6 (19.2)				
Δa	3.2 (3.9)	4.2 (6.3)	2.8 (4.4)	5.6 (6.3)	<0.001 <sup>1</sup>	ns	<0.001 <sup>1</sup>	ns
– Malignant lesion	169.6 (6.1)	165.1 (6.3)	165.9 (6.2)	162.7 (6.9)				
– Surrounding lesion	166.4 (6.1)	161 (6.2)	163.1 (5.7)	157.1 (7.4)				
Δb	2.5 (4.3)	1.3 (8.4)	2.7 (3.3)	2.1 (8.3)	ns			
– Malignant lesion	175.5 (7.4)	151.6 (7.6)	163.1 (7.5)	147.5 (7.3)				
– Surrounding lesion	173 (7)	150.2 (6.7)	160.3 (7.9)	145.4 (7.3)				
Location ΔE								
▪ Proximal (n = 5)	10.6 (2.5)	13.1 (2.8)	9.6 (2.6)	14.1 (6.8)	ns			
▪ Middle (n = 13)	6.4 (3.9)	11.3 (4.4)	6.9 (4.6)	11.1 (4.2)	0.0002 <sup>1</sup>	0.0032 <sup>1</sup>	0.007 <sup>1</sup>	0.0158 <sup>1</sup>
▪ Distal (n = 33)	6.6 (3.4)	11 (4.8)	6 (3.3)	11.9 (4.9)	<0.001 <sup>1</sup>	<0.001 <sup>1</sup>	<0.001 <sup>1</sup>	<0.001 <sup>1</sup>
Morphology ΔE								
▪ Elevated (n = 12)	6.5 (3.7)	11.2 (3.9)	7 (4.5)	12.7 (4.6)	0.0002 <sup>1</sup>	0.0265 <sup>1</sup>	0.0052 <sup>1</sup>	0.0287 <sup>1</sup>
▪ Flat (n = 4)	7.1 (5.7)	13.3 (5.2)	6.2 (3.7)	14.2 (4.5)	ns			
▪ Depressed (n = 35)	7.1 (3.4)	11.1 (4.7)	6.4 (3.5)	11.4 (5)	<0.001 <sup>1</sup>	<0.001 <sup>1</sup>	<0.001 <sup>1</sup>	<0.001 <sup>1</sup>
Size ΔE								
▪ ≤ 10 mm (n = 13)	7.3 (3.4)	11.8 (4.8)	6.4 (2.9)	12.3 (5.3)	0.0002 <sup>1</sup>	0.0009 <sup>1</sup>	0.0023 <sup>1</sup>	0.0006 <sup>1</sup>
▪ 11–20 mm (n = 14)	7.1 (4.5)	9.7 (3.9)	6 (3.8)	10.2 (3.8)	0.0015 <sup>1</sup>	0.039 <sup>1</sup>	0.0075 <sup>1</sup>	0.0288 <sup>1</sup>
▪ 21–30 mm (n = 9)	6.1 (2.7)	11.3 (5.3)	6.4 (4.8)	12.2 (5)	0.0006 <sup>1</sup>	ns	0.02 <sup>1</sup>	0.0441 <sup>1</sup>
▪ > 30 mm (n = 15)	7.1 (3.5)	12.4 (4.4)	7.4 (3.8)	13 (5.4)	<0.001 <sup>1</sup>	0.0013 <sup>1</sup>	0.004 <sup>1</sup>	0.0008 <sup>1</sup>
<i>H. pylori</i> status ΔE								
▪ Positive (n = 32)	6.7 (3.5)	11.5 (4.9)	6.5 (4)	12.5 (5.5)	<0.001 <sup>1</sup>	<0.001 <sup>1</sup>	<0.001 <sup>1</sup>	<0.001 <sup>1</sup>
▪ Eradicated (n = 13)	7.6 (4.2)	10.9 (4.6)	6.6 (3.7)	11.2 (3.8)	0.0004 <sup>1</sup>	0.0139 <sup>1</sup>	0.0027 <sup>1</sup>	0.0019 <sup>1</sup>
Histology ΔE								
▪ Differentiated (n = 47)	6.9 (3.5)	11.4 (4.6)	6.6 (3.7)	12.2 (4.8)	<0.001 <sup>1</sup>	<0.001 <sup>1</sup>	<0.001 <sup>1</sup>	<0.001 <sup>1</sup>
▪ Undifferentiated (n = 4)	7.5 (5.5)	9.9 (4.9)	6.6 (5.0)	8.0 (4.3)	0.0447 <sup>1</sup>	ns	ns	ns
Depth ΔE								
▪ M (n = 40)	6.4 (3.5)	10.7 (4.6)	5.9 (3.4)	11.5 (5)	<0.001 <sup>1</sup>	<0.001 <sup>1</sup>	<0.001 <sup>1</sup>	<0.001 <sup>1</sup>
▪ SM1 (n = 4)	7.3 (4.4)	13.6 (4.7)	8.0 (3.2)	14.7 (1.9)	ns			
▪ SM2 (n = 7)	9.7 (2.5)	13.4 (3.6)	9.6 (4.3)	12.5 (5.2)	0.0265 <sup>1</sup>	ns	ns	0.0258 <sup>1</sup>

► **Table 3** (Continuation)

One lesion was excluded from analysis because of minute size. Data are shown as mean (standard deviation).

$\Delta E$  shows color difference and is calculated from the following formula:  $[(\Delta L^*)^2 + (\Delta a^*)^2 + (\Delta b^*)^2]^{1/2}$ .

$L$  is defined as lightness,  $a$  as the red–green component and  $b$  as the yellow–blue component.

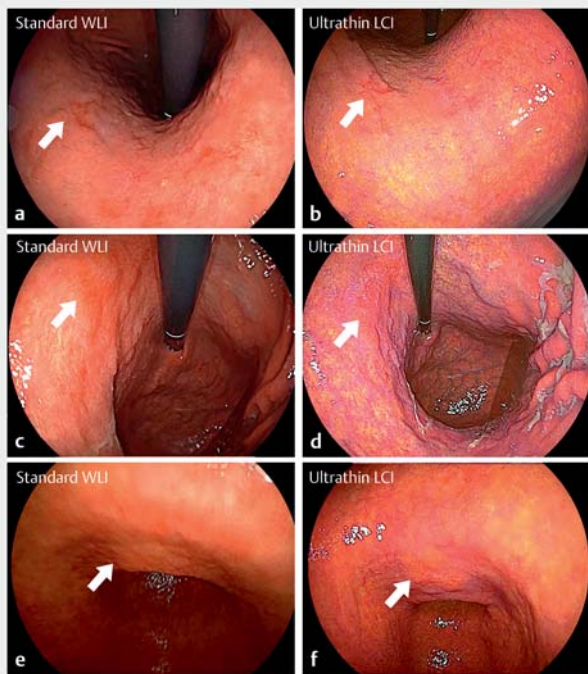
$\Delta L$  is obtained from a formula: (absolute  $L$  of malignant lesion - absolute  $L$  of surrounding mucosa)  $\times$  100/255.

Values ( $\Delta a$ ,  $\Delta b$ ) were obtained by subtracting the value for the surrounding mucosa from the value for the malignant lesion.

WLI, white light image; LCI, linked color imaging; ns, not significant.

Comparisons between four modes were made using the one-way Analysis of Variance (ANOVA) with Bonferroni post-hoc test for significance between paired groups.

<sup>1</sup> Statistically significant.

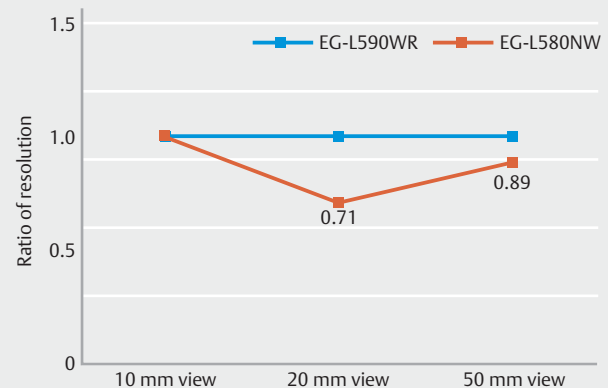


► **Fig. 4** EGCs missed using standard white light imaging (WLI) by more than two endoscopists but detected by ultrathin linked color imaging (LCI). **a** Small, depressed cancer (white arrow) near inflammatory map-like redness using standard endoscope, WLI, **b** ultrathin endoscope, LCI. **c, e** Standard WLI, **d, f** ultrathin LCI of flat-elevated and flat lesion respectively.

ond and third cases were flat and flat-elevated lesion, respectively. These malignant and benign lesions could not be identified or differentiated by WLI but were visualized as orange-red malignant lesions and purple inflammatory lesions by LCI.

### Difference of resolution between standard and ultrathin endoscope

The resolution using an ultrathin endoscope was compared with that of a standard endoscope and expressed as a ratio to the value obtained using the standard endoscope (arbitrary units). The resolution using the ultrathin endoscope was the same as that using the standard endoscope at a 10-mm view from the resolution chart but was lower at 20-mm (0.71) and 50-mm (0.89) views simulating the distance between the endoscopic tip and target gastric mucosa during screening (► **Fig. 5**).



► **Fig. 5** Ratio of resolution of the ultrathin endoscope (EG-L580NW) to the standard endoscope (EG-L590WR) at each distance between the endoscope tip and the resolution chart. The resolution using the ultrathin endoscope is lower than when using a standard endoscope at the 20-mm and 50-mm distances, simulating the distance between the endoscope tip and the target gastric mucosa at screening.

## Discussion

This is the first report to demonstrate that the color contrast between a malignant lesion and its surrounding mucosa is more important than high-resolution images when screening for EGCs. These results show both ultrathin LCI and standard LCI improve the ability to detect EGCs compared with ultrathin WLI and standard WLI, respectively. Ultrathin LCI had a higher diagnostic sensitivity, significantly higher visibility scores, and color difference than standard WLI. This suggests that color contrast is more important than resolution for the identification of EGC. The introduction of ultrathin LCI seems to be suitable for EGC screening in clinical practice including routine health examinations.

Ultrathin endoscopy is generally considered to yield low-resolution images compared with standard endoscopy. Our test of resolution using industry-standard testing protocols showed that ultrathin endoscopy results in images with a lower resolution at a distant view. However, sensitivity for detection of EGCs was highest using standard LCI, followed by ultrathin LCI, standard WLI, and ultrathin WLI. This order implies that endoscopists are aware of the color contrast between malignant lesions and the surrounding mucosa as previously reported using ultrathin endoscopy with flexible spectral imaging color enhancement (FICE) [22, 23]. LCI accelerates the ability for the early detection

of gastric cancers, with the superiority of ultrathin LCI compared to standard WLI.

The specificity of LCI was lower than WLI both with ultrathin and standard endoscopes. Most non-malignant gastric lesions such as intestinal metaplasia, erosions and regenerative epithelium exhibit mucosal changes with lower color contrast to the surrounding mucosa on WLI, but with high color contrast on LCI, which may result in lower specificity of LCI compared with WLI. Using LCI, suspicious lesions may increase but blue light imaging allows endoscopists to differentiate the malignant lesion due to better visualization of surface patterns without magnification [24, 25]. The final diagnosis is made by target biopsy. In our experience, we use LCI in routine clinical practice as the optimal mode for detection of EGC, but not as the final endoscopic diagnosis tool.

Older age groups have a high risk for gastric cancer even after *H. pylori* eradication due to atrophy and intestinal metaplasia in the background mucosa [26]. However, establishing this diagnosis is challenging due to non-neoplastic epithelium covering the malignant tissue which makes the cancer border indistinct and diminishes the obvious characteristics of cancer [27]. The current data show that color differences between malignant lesions and the surrounding mucosa of EGC is significantly higher with ultrathin LCI than standard WLI regardless of *H. pylori* infection status. Ultrathin endoscopy reduces pain and panic during the procedure and is advantageous especially for elderly patients with cardiopulmonary dysfunction [6, 7]. Together with the previously reported superiority of LCI for screening in the upper gastrointestinal tract [14], ultrathin LCI can be suggested as the first choice for gastric screening in the elderly and/or high-risk patients with cardiopulmonary dysfunction.

Ultrathin endoscopy has been shown to result in poor visibility of malignant lesions in the proximal stomach using a xenon endoscope [9], but not using laser endoscopy, although it has good visibility around the lesser curvature of the angle [28, 29]. In this study, ultrathin LCI showed high visibility scores and significantly higher color differences in the proximal stomach compared with standard WLI. Of five malignant lesions in the lesser curvature near the angle, at least two assessors missed malignant lesions with standard WLI whereas all assessors identified all lesions with ultrathin LCI. Ultrathin endoscopy has advantages such as allowing direct visualization of these areas due to a shorter radius at the tip and has the potential to observe the entire stomach with fewer blind spots. However, all assessors identified all these lesions even with standard LCI endoscopy, which may suggest the true efficacy of LCI rather than the physical flexibility of the ultrathin endoscope. Additional studies are necessary to conclusively evaluate this matter.

We have previously reported that LCI provides images with high color contrast to the surrounding mucosa for EGC [18]. LCI increased the  $a^*$  value in the red-green component and/or  $b^*$  values in the yellow-blue component in the color space when evaluating color differences between malignant lesions and the surrounding mucosa [17, 18]. In this study, most malignant lesions were surrounded by purple mucosa only in a partial cir-

cumferential area (or not at all). The malignant areas and surrounding mucosa were mostly orange-red and light orange, respectively, resulting in the possibility to influence  $a^*$  value in the red-green component rather than  $b^*$  values related to purple.

Recent advances in endoscopic treatment such as endoscopic submucosal dissection improves the prognosis of patients with EGCs and allows patients to maintain a high quality of life after therapy. It is beneficial to detect cancers when they are as small as possible to allow the use of endoscopic therapy. The current study showed that the color difference with ultrathin LCI is higher than with standard WLI even with lesions at a diameter  $\leq 10$  mm, suggesting that the advantage was found regardless of lesion size.

This study has several acknowledged limitations. First, this is a single-center study with a small number of assessors. Second, the evaluated videos may not be representative of live endoscopic screening for gastric cancer. Third, the endoscopists who performed EGC to create the videos were not blinded to patient data or the type of endoscopes. Multicenter prospective clinical trials are needed to confirm these results. Fourth, diagnosing EGC in 90 seconds is challenging and thus only expert endoscopists participated.

## Conclusions

In conclusion, LCI facilitates the early detection of gastric cancers by providing high color contrast to the surrounding mucosa regardless of using standard or ultrathin endoscopes. LCI with a low-resolution ultrathin endoscope is superior to WLI with a high-resolution standard endoscope for gastric cancer screening. This suggests that color contrast between malignant lesions and the surrounding mucosa is more important than high-resolution imaging.

## Competing interests

Dr. Yamamoto has patents for ESD devices and double-balloon endoscopy produced by Fujifilm Corporation. He has a consultant relationship with the Fujifilm Corporation and has received honoraria, grants, and royalties from the company. Drs. Osawa and Miura have received honoraria from Fujifilm Corporation.

## References

- [1] Yagi J, Adachi K, Arima N et al. A prospective randomized comparative study on the safety and tolerability of transnasal esophagogastroduodenoscopy. *Endoscopy* 2005; 37: 1226–1231
- [2] Murata A, Akahoshi K, Sumida Y et al. Prospective randomized trial of transnasal versus peroral endoscopy using an ultrathin videoendoscope in unsedated patients. *J Gastroenterol Hepatol* 2007; 22: 482–485
- [3] Garcia RT, Cello JP, Nguyen MH et al. Unsedated ultrathin EGD is well accepted when compared with conventional sedated EGD: a multicenter randomized trial. *Gastroenterology* 2003; 125: 1606–1612
- [4] Thota PN, Zuccaro GJr, Vargo JJ 2nd et al. A randomized prospective trial comparing unsedated esophagoscopy via transnasal and trans-



- oral routes using a 4-mm video endoscope with conventional endoscopy with sedation. *Endoscopy* 2005; 37: 559–565
- [5] Preiss C, Charton JP, Schumacher B et al. A randomized trial of unседated transnasal small-caliber esophagogastroduodenoscopy (EGD) versus peroral small-caliber EGD versus conventional EGD. *Endoscopy* 2003; 35: 641–646
- [6] Mori A, Ohashi N, Tatebe H et al. Autonomic nervous function in upper gastrointestinal endoscopy: A prospective randomized comparison between transnasal and oral procedures. *J Gastroenterol* 2008; 43: 38–44
- [7] Mori A, Ohashi N, Maruyama T et al. Cardiovascular tolerance in upper gastrointestinal endoscopy using an ultrathin scope: prospective randomized comparison between transnasal and transoral procedures. *Digest Endosc* 2008; 20: 79–83
- [8] Tatsumi Y, Harada A, Matsumoto T et al. Current status and evaluation of transnasal esophagogastroduodenoscopy. *Digest Endosc* 2009; 21: 141–146
- [9] Toyozumi H, Kaise M, Arakawa H et al. Ultrathin endoscopy versus high-resolution endoscopy for diagnosing superficial gastric neoplasia. *Gastrointest Endosc* 2009; 70: 240–245
- [10] Zaman A, Hahn M, Hapke R et al. A randomized trial of peroral versus transnasal unседated endoscopy using an ultrathin videoendoscope. *Gastrointest Endosc* 1999; 49: 279–284
- [11] Faulx AL, Catanzaro A, Zyzanski S et al. Patient tolerance and acceptance of unседated ultrathin esophagoscopy. *Gastrointest Endosc* 2002; 55: 620–623
- [12] Birkner B, Fritz N, Schatke W et al. A prospective randomized comparison of unседated ultrathin versus standard esophagogastroduodenoscopy in routine outpatient gastroenterology practice: does it work better through the nose? *Endoscopy* 2003; 35: 647–651
- [13] Yoshida Y, Hayami Y, Matuoka M et al. Comparison of endoscopic detection rate of early gastric cancer and gastric adenoma using transnasal egd with that of transoral EGD. *Digest Endosc* 2008; 20: 184–189
- [14] Ono S, Kawada K, Dohi O et al. Linked color imaging focused on neoplasm detection in the upper gastrointestinal tract: a randomized trial. *Ann Internal Med* 2021; 174: 18–24
- [15] Gotoda T, Uedo N, Yoshinaga S et al. Basic principles and practice of gastric cancer screening using high-definition white-light gastroscopy: Eyes can only see what the brain knows. *Dig Endosc* 2016; 28: 2–15
- [16] Yoshida N, Naito Y, Murakami T et al. Linked color imaging improves the visibility of colorectal polyps: a video study. *Endosc Int Open* 2017; 5: E518–E525
- [17] Kanzaki H, Takenaka R, Kawahara Y et al. Linked color imaging (LCI), a novel image-enhanced endoscopy technology, emphasizes the color of early gastric cancer. *Endosc Int Open* 2017; 5: E1005–e1013
- [18] Fukuda H, Miura Y, Osawa H et al. Linked color imaging can enhance recognition of early gastric cancer by high color contrast to surrounding gastric intestinal metaplasia. *J Gastroenterol* 2019; 54: 396–406
- [19] Takeda T, Nagahara A, Ishizuka K et al. Improved Visibility of Barrett's esophagus with linked color imaging: inter- and intra-rater reliability and quantitative analysis. *Digestion* 2018; 97: 183–194
- [20] Pierre SA, Ferrandino MN, Simmons WN et al. High definition laparoscopy: objective assessment of performance characteristics and comparison with standard laparoscopy. *J Endourol* 2009; 23: 523–528
- [21] Yabe H. Magnifying ratio and resolution of electronic endoscopes. *Digest Endosc* 2002; 14: S88–S90
- [22] Osawa H, Yamamoto H, Miura Y et al. Diagnosis of depressed-type early gastric cancer using small-caliber endoscopy with flexible spectral imaging color enhancement. *Digest Endosc* 2012; 24: 231–236
- [23] Osawa H, Yamamoto H, Yamada N et al. Diagnosis of endoscopic Barrett's esophagus by transnasal flexible spectral imaging color enhancement. *J Gastroenterol* 2009; 44: 1125–1132
- [24] Osawa H, Yamamoto H, Miura Y et al. Blue laser imaging provides excellent endoscopic images of upper gastrointestinal lesions. *Video J Encycloped GI Endosc* 2014; 1: 607–610
- [25] Osawa H, Miura Y, Takezawa T et al. Linked color imaging and blue laser imaging for upper gastrointestinal screening. *Clin Endosc* 2018; 51: 513–526
- [26] Chen HN, Wang Z, Li X et al. Helicobacter pylori eradication cannot reduce the risk of gastric cancer in patients with intestinal metaplasia and dysplasia: evidence from a meta-analysis. *Gastric Cancer* 2016; 19: 166–175
- [27] Saka A, Yagi K, Nimura S. Endoscopic and histological features of gastric cancers after successful Helicobacter pylori eradication therapy. *Gastric Cancer* 2016; 19: 524–530
- [28] Takahashi H, Miura Y, Osawa H et al. Blue laser imaging with a small-caliber endoscope facilitates detection of early gastric cancer. *Clin Endosc* 2019; 52: 273–277
- [29] Toma S, Osawa H, Yoshizawa M et al. Diagnosis of small flat early gastric cancer by flexible spectral imaging color enhancement. *Clin J Gastroenterol* 2010; 3: 88–91