

## Novel method to remove deeply migrated pancreatic duct stent

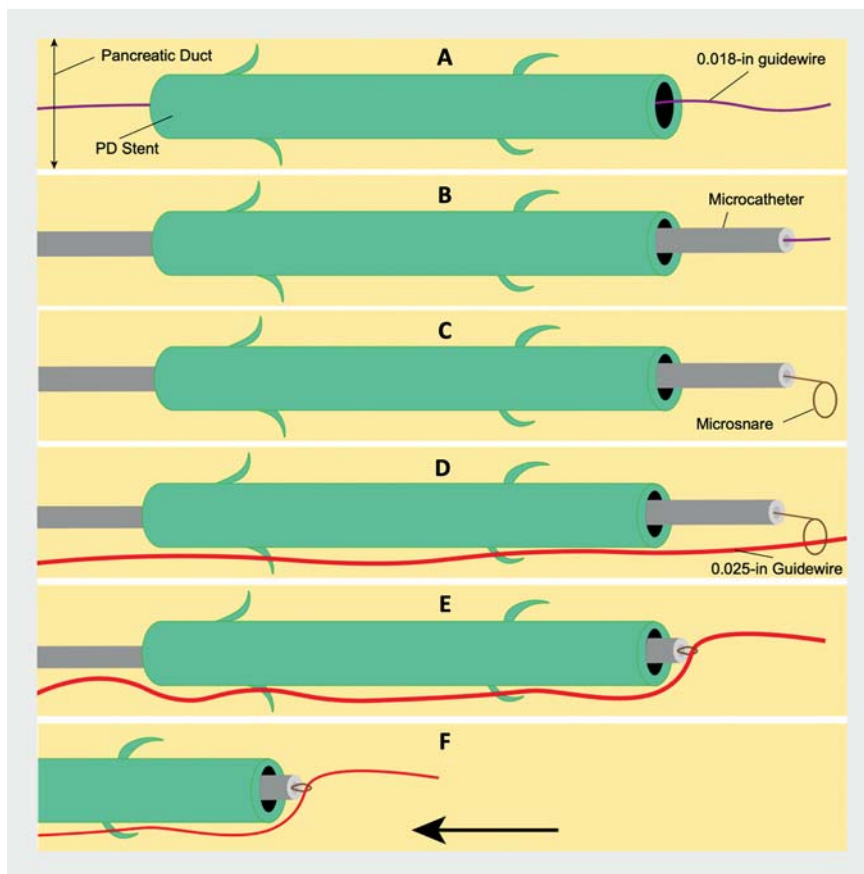
Many techniques have been described for the removal of proximally migrated pancreatic duct (PD) stents, with a reported success rate of 80% [1]. Success depends on the location of the stent and caliber of PD. In general, it is more difficult if the PD is narrow or not dilated and the stent is located in the pancreatic tail.

A 64-year-old woman underwent a routine endoscopic retrograde cholangiopancreatography (ERCP) for choledocholithiasis and received a straight 5-Fr plastic PD stent placement owing to difficult biliary cannulation. Unfortunately, the PD stent migrated to the pancreatic genu and attempts at removal using a Dormia basket and rat tooth forceps pushed the stent deeper beyond the genu.

Owing to the COVID-19 situation, a conventional wire-guided Soehendra stent retriever was not available in our country and would have needed a few months for delivery. Balloon and grasping devices were again unsuccessfully used in an attempt to remove the PD stent. A third ERCP was performed 2 days later. The plan to snare the distal end of the PD stent using a “lasso-over-the-guidewire” technique [2] was unsuccessful because the distal stent edge abutted the PD wall, preventing the snare wire from looping around the migrated PD stent.

With the use of Hi-Torque Command 0.018-inch guidewire (Abbott Laboratories, Chicago, Illinois, USA), a VisiGlide 2 0.025-inch straight-tip guidewire (Olympus Medical, Tokyo, Japan), and a 4-mm microsnare and microcatheter, we report this novel “closed-loop” method of removing a migrated PD stent in the tail of the pancreas, where conventional techniques failed and the wire-guided stent retriever was not available (► Fig. 1, ► Video 1). This method securely removes the impacted stent with minimal trauma to the pancreatic duct.

Endoscopy\_UCTN\_Code\_TTT\_1AR\_2AZ



► **Fig. 1** The novel “closed-loop” method is demonstrated in six steps. **a** The 0.018-in guidewire (purple) was passed into the pancreatic duct (PD) through the migrated PD stent (green). **b** The microcatheter (grey) was then railroaded through an 0.018-in guidewire into the PD stent. **c** The 0.018-in guidewire was then exchanged for a microsnare (brown). **d** A 0.025-inch guidewire (red) was then passed externally alongside the PD stent and maneuvered through the microsnare loop at the proximal end of the PD stent. **e** The microsnare was used to snare the non-hydrophilic portion of the guidewire to minimize slipping and the microcatheter was pulled back to the proximal end of the PD stent to form a closed loop. **f** With this closed loop system, the PD stent was removed successfully.

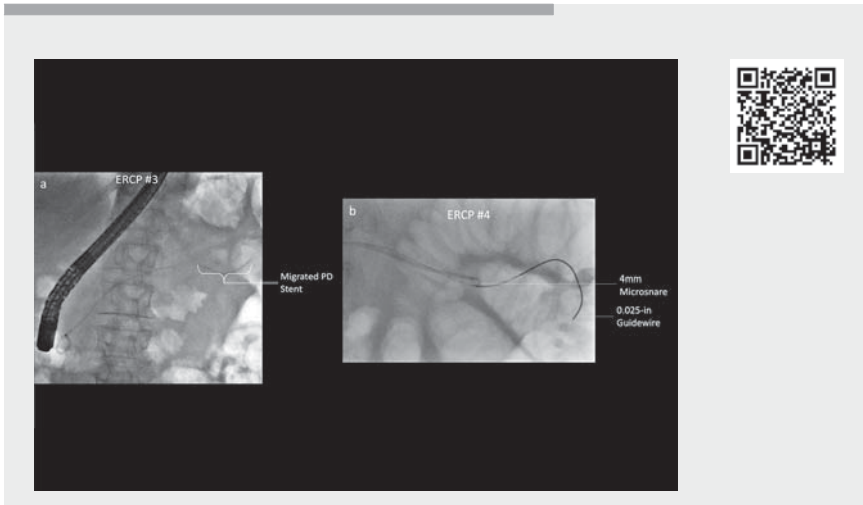
### Competing interests

The authors declare that they have no conflict of interest.

### The authors

Wee Khoon Ng<sup>1</sup>, Quan Rui Tan<sup>2</sup>, Sundeep Jaywantraj Punamiya<sup>3</sup>, Paul Jau Lueng Ong<sup>4</sup>, Charles Kien Fong Vu<sup>1</sup>

- 1 Department of Gastroenterology and Hepatology, Tan Tock Seng Hospital, Singapore
- 2 Lee Kong Chian School of Medicine, Singapore



**Video 1** Novel “closed-loop” method to retrieve proximally migrated pancreatic duct stent.

- 3 Department of Diagnostic Radiology, Tan Tock Seng Hospital, Singapore
- 4 Heart Specialist International, Singapore

### Corresponding author

**Wee Khoon Ng, MBBS, MRCP**  
 Department of Gastroenterology and Hepatology, Tan Tock Seng Hospital, 11 Jalan Tan Tock Seng, Singapore 308433  
 wee\_khoon\_ng@ttsh.com.sg

### References

- [1] Price LH, Brandabur JJ, Kozarek RA et al. Good stents gone bad: endoscopic treatment of proximally migrated pancreatic duct stents. *Gastrointest Endosc* 2009; 70: 174–179
- [2] Vila JJ, Ruiz-Clavijo D, Fernandez-Urien I et al. Endoscopic retrieval of a proximally migrated pancreatic stent: variation of the lasso technique. *Endoscopy* 2010; 42: E5–E6

### Bibliography

*Endoscopy* 2022; 54: E748–E749  
**DOI** 10.1055/a-1792-2469  
**ISSN** 0013-726X  
**published online** 31.3.2022  
 © 2022. Thieme. All rights reserved.  
 Georg Thieme Verlag KG, Rüdigerstraße 14,  
 70469 Stuttgart, Germany

### ENDOSCOPY E-VIDEOS

<https://eref.thieme.de/e-videos>



*Endoscopy E-Videos* is an open access online section, reporting on interesting cases and new techniques in gastroenterological endoscopy. All papers include a high quality video and all contributions are freely accessible online. Processing charges apply (currently EUR 375), discounts and waivers acc. to HINARI are available.

This section has its own submission website at <https://mc.manuscriptcentral.com/e-videos>