

# Laparoscopic Surgery for Ovarian Neoplasms – What is Possible, What is Useful?

## Laparoskopische Chirurgie bei ovariellen Neoplasien – was ist möglich, was ist sinnvoll?



### Authors

Annika Droste<sup>1</sup>, Katharina Anic<sup>1</sup>, Annette Hasenburg<sup>1</sup>

### Affiliations

<sup>1</sup> Department of Gynecology and Obstetrics, University Medical Center Mainz, Mainz, Germany

### Key words

benign ovarian tumors, ovarian malignancy, laparoscopy

### Schlüsselwörter

benigne Ovariumtumoren, Ovarialmalignom, Laparoskopie

received 27.6.2022

accepted after revision 21.10.2022

### Bibliography

Geburtsh Frauenheilk 2022; 82: 1368–1377

DOI 10.1055/a-1787-9144

ISSN 0016-5751

© 2022. The Author(s).

This is an open access article published by Thieme under the terms of the Creative Commons Attribution-NonDerivative-NonCommercial-License, permitting copying and reproduction so long as the original work is given appropriate credit. Contents may not be used for commercial purposes, or adapted, remixed, transformed or built upon. (<https://creativecommons.org/licenses/by-nc-nd/4.0/>).

Georg Thieme Verlag KG, Rüdigerstraße 14, 70469 Stuttgart, Germany

### Correspondence

Dr. med. univ. Annika Droste  
Universitätsmedizin der Johannes Gutenberg-Universität  
Mainz, Klinik und Poliklinik für Geburtshilfe  
und Frauengesundheit  
Langenbeckstraße 1  
55131 Mainz, Germany  
[annika.droste@unimedizin-mainz.de](mailto:annika.droste@unimedizin-mainz.de)

Deutsche Version unter:  
<https://doi.org/10.1055/a-1787-9144>.

### ABSTRACT

The use of minimally invasive surgical techniques is becoming increasingly important in gynecologic oncology due to technical advances and the increasing level of surgical expertise. In addition to laparoscopic approaches for the treatment of be-

nign neoplasms, minimally invasive surgical methods have also become established in some areas for treating gynecologic malignancies. For tumor entities such as endometrial and cervical carcinoma, there are conclusive studies emphasizing the role of laparoscopy in surgical therapy. By contrast, due to a lack of prospective data with survival analyses, no clear conclusions can be drawn on the significance of laparoscopy in the surgical treatment of ovarian carcinoma. However, some smaller, mostly retrospective case-control studies and cohort studies open the way for a discussion, positing the possibility that laparoscopic surgical procedures, particularly for early ovarian carcinoma, are technically feasible and of a quality equivalent to that of conventional longitudinal laparotomy, and may also be associated with lower perioperative morbidity.

In this article we discuss the most important aspects of using minimally invasive surgical techniques for ovarian carcinoma based on the current literature. In particular we look at the relevance of laparoscopy as a primary approach for surgical staging of early ovarian carcinoma, and we evaluate the role of diagnostic laparoscopy in assessing the operability of advanced ovarian carcinoma.

### ZUSAMMENFASSUNG

Durch den technischen Fortschritt und die zunehmende chirurgische Expertise gewinnt der Einsatz minimalinvasiver Operationstechniken auch in der gynäkologischen Onkologie zunehmend an Stellenwert. Neben dem Einsatzgebiet der Laparoskopie bei der Behandlung benigner Neoplasien haben sich minimalinvasive Operationsmethoden auch in einigen Bereichen der Behandlung gynäkologischer Malignome etabliert. Bei Tumorentitäten wie dem Endometrium- und Zervixkarzinom liegen bereits aussagekräftige Studien zum Stellenwert der Laparoskopie in der operativen Therapie vor. Im Gegensatz dazu kann bei der operativen Therapie des Ovarialkarzinoms aufgrund fehlender prospektiver Daten mit Überlebenszeitanalysen keine eindeutige Aussage zum Stellenwert des laparoskopischen Zugangswegs getroffen werden. Einige kleinere und größtenteils retrospektive Fallkontroll- und Kohortenstudien lassen jedoch die Diskussion zu, dass laparoskopische Operationsverfahren, vor allem beim frühen Ovarialkarzinom,

einerseits technisch durchführbar sowie qualitativ gleichwertig und andererseits mit einer geringeren perioperativen Morbidität im Vergleich zur klassischen offen-chirurgischen Längslaparotomie assoziiert sein könnten.

In dem vorliegenden Artikel werden auf der Basis der aktuellen Literatur die wichtigsten Gesichtspunkte in Bezug auf den Einsatz minimalinvasiver Operationstechniken beim Ovarialkarzi-

nom diskutiert. Dabei wird insbesondere auf den Stellenwert der Laparoskopie als primären Zugangsweg für das operative Staging beim frühen Ovarialkarzinom eingegangen und die Rolle der diagnostischen Laparoskopie zur Operabilitäts-einschätzung beim fortgeschrittenen Ovarialkarzinom bewertet.

---

## Introduction

Minimally invasive surgical techniques are considered the clinical standard for most gynecological diseases that are primarily treated with surgery, because perioperative morbidity is low and the postoperative cosmetic results are better. Minimally invasive surgery is also becoming more and more relevant in treating gynecological malignancies. However, it is currently unclear how important laparoscopy is for the treatment of ovarian carcinoma. In accordance with the guidelines, primary debulking surgery is performed with a midline longitudinal laparotomy [1]. However, there is considerable debate around a possible laparoscopic treatment approach; this is due both to ongoing development of this surgical technique, and to the potential it brings for reasonable de-escalation of surgery, particularly in early ovarian carcinoma. Some studies indicate that the feasibility of the laparoscopic approach for this tumor entity does not seem to be inferior to that of laparotomy; also, the rate of perioperative and postoperative complications is lower [2, 3, 4, 5]. There are currently no controlled randomized studies on this question that compare the treatment approach of minimally invasive surgery for (early) ovarian carcinoma with the outcome after a conventional open operation; accordingly, no conclusive statement can be made on the importance of laparoscopy in the treatment of ovarian carcinoma [6].

In the following we provide an overview of the most common, and in some cases controversial, points of discussion regarding the use of laparoscopy in ovarian neoplasms.

## Benign Ovarian Tumors and Neoplasms of Unclear Dignity

Among the most common reasons for undergoing a pelvic examination are nonspecific complaints triggered by adnexal cysts. In addition, ovarian tumors are frequently detected as an incidental finding during a transvaginal ultrasound [7, 8]. This affects premenopausal patients in particular [9]. The highest priority during diagnosis is to differentiate benign from malignant findings in the ovary. The preoperative assessment is essential here, also with regard to choosing the surgical approach. For benign ovarian tumors, laparoscopy is the gold standard for surgical therapy. As well as better cosmetic results after the operation due to the smaller incisions, the benefits of laparoscopy compared to laparotomy include less blood loss during surgery and a reduction in formation of adhesions, as well as less postoperative pain and quicker mobilization and reconvalescence; this is associated with a significant reduction in the time spent in hospital, and with fewer perioperative

complications overall [10, 11, 12, 13]. In order to differentiate ovarian neoplasms, it is necessary to take into account the patient's medical history, genetic predisposition, clinical and laboratory findings, and imaging results. The first important criterion in assessing the tumor dignity is the age and menopausal status of the patient, as the incidence of malignant ovarian tumors in women of a reproductive age is considered very low [14, 15, 16]. The likelihood of a premenopausal patient being incidentally diagnosed with ovarian carcinoma during laparoscopy is less than one percent [17, 18]. What is more difficult is the preoperative classification of adnexal findings in postmenopausal women. The screening criteria of the International Ovarian Tumor Analysis (IOTA) working group have been established as a tool for decision-making and to better assess the risk for this cohort of patients [19]. The patient's age and CA-125 serum level and whether or not the examination was performed at a center specializing in gynecologic oncology are essential criteria for interpreting the ultrasound findings. In addition, six ultrasound-specific criteria (maximum diameter, number of solid parts, number of cysts and papillary extensions, and presence of acoustic shadows and/or ascites) are also used in the evaluation [20, 21, 22]. A preoperative risk assessment is intended to avoid the incidental discovery of an ovarian malignancy during surgery, and hence a scenario in which the patient cannot be operated on in accordance with the guidelines, due for example to a lack of informed consent, or to structural deficits that could have been avoided prior to surgery. If before surgery there is reason to suspect that the ovarian findings are malignant, a primary laparoscopic treatment approach should be avoided [1]. If necessary further diagnostics should be carried out in order to clarify the suspected diagnosis, such as an MRI of the pelvis or a CT scan for diagnostic evaluation of the adjacent structures [1]. If the dignity of the ovarian findings is unclear and a treatment approach with primary laparoscopy is discussed with the patient, the patient must be advised that there is a higher rate of perioperative complications if a malignant tumor is present compared to a benign lesion, and if evidence of malignancy is found during the surgery, for example from an intraoperative histological examination, it will be necessary to expand the operation, including conversion to a midline longitudinal laparotomy, in order to perform adequate staging and tumor debulking in accordance with the guidelines [23].

For ovarian tumors, it is vital that a preoperative risk assessment is carried out by an experienced surgeon, as this allows laparotomy to be avoided if benign ovarian findings indicate the use of a primary laparoscopic treatment approach, which in turn lowers the rate of perioperative complications; however it must be

ensured that patients with malignant ovarian findings are operated on in accordance with the guidelines [24, 25, 26].

## Laparoscopic Procedures for Treating Ovarian Carcinoma

### The role of laparoscopy in early ovarian carcinoma

The spread of “early” ovarian carcinoma is limited to the lesser pelvis and is classified according to the International Federation of Gynaecology and Obstetrics (FIGO) in the stages I to IIA [1]. In primary situations, the standard therapy in accordance with the guidelines includes surgical staging through midline longitudinal laparotomy with the primary aim of macroscopically complete tumor resection. During surgical staging, the entire abdominal cavity should be inspected and palpated, including the adnexa on both sides, the uterus, the diaphragmatic cupolae, the surface of the liver, the gallbladder, spleen, stomach, pancreas, and kidneys, the greater and lesser omentum, the small intestine from the Treitz ligament to the ileocecal valve including the mesenteric root, the paracolic gutters, the colon from the cecum to the rectum, the pelvic and para-aortic lymph nodes, and the peritoneum [1]. The scope of surgical staging (including taking systematic biopsies and performing peritoneal cytology) is crucial; if staging is incomplete, there is a risk that tumor manifestations may go undetected and the patient may not be treated according to the correct stage [27, 28, 29, 30]. Multiple studies have proven how relevant the completeness of surgical staging is for the prognosis [31, 32]. For example, the results of the ACTION study (Adjuvant Chemotherapy in Ovarian Neoplasm) by the European Organization for Research and Treatment of Cancer show that completeness of surgical staging was an independent prognostic factor for a significantly better postoperative oncological outcome in patients with early ovarian carcinoma [31, 32]. In this context, it is also important to highlight the importance of being treated at a specialist center. Du Bois et al. showed in a systematic review that the treatment adherence in accordance with the guidelines, particularly with regard to the completeness of surgical staging, was significantly higher if the operation was performed by a gynecologist compared to a surgeon with a different sub-specialization [33]. Furthermore, there was evidence that the operation being performed by a gynecologic oncologist was associated with a better surgical result in terms of higher rates of optimal cytoreduction [33].

With regard to the suitable approach for surgical staging, it has been fiercely debated for many years whether laparoscopy in the surgical treatment of (early) ovarian carcinoma could be a suitable alternative to the conventional longitudinal laparotomy. Laparoscopic treatment approaches were described in literature back in the 1970s [34, 35]. In 1975, Rosenoff et al. proved that diagnostic peritoneoscopy could detect occult tumor manifestations, which resulted in a higher classification of tumor stage [34]. In 1976, Spinelli et al. also described for the first time the diagnostic benefit of systematically inspecting the diaphragm by laparoscopy [35]. Despite the long history of using laparoscopic procedures in ovarian carcinoma, to date there have been no controlled randomized studies that compare surgical staging by laparoscopy with

staging by laparotomy [6, 36]. Individual case-control studies, case reports, and cohort studies indicate that laparoscopic staging seems to be technically feasible for early ovarian carcinoma and does not seem to be inferior to laparotomy in terms of the oncological outcome and surgical safety [2, 3, 4, 5, 10]. This means that primary laparoscopic staging could be an alternative to laparotomy in the future. Due to the benefits already mentioned, laparoscopic surgery is increasingly being used in certain centers to treat early ovarian carcinoma, despite the lack of high-quality evidence. This approach is also supported by a published survey among the members of the Society of Gynecologic Oncologists, USA, in which approx. 50% of respondents stated that a minimally invasive procedure almost always or in most cases is an appropriate approach as part of the primary therapy for early ovarian carcinoma [37]. In line with this, a retrospective analysis by Matsuo et al. showed an increase in the number of minimally invasive operations for early ovarian carcinoma in the USA from 3.9% in 2001 to 13.5% in 2011 [38].

Below we discuss the role of laparoscopy vs. laparotomy in early ovarian carcinoma.

1. Surgical staging: Both the technical feasibility of laparoscopy compared to laparotomy and its equivalence for inspecting all of the abdominal structures, particularly with regard to potentially invasive implants on the small intestine, the upper abdominal organs, and the retroperitoneum, are debatable [1, 5, 39]. In particular, exploration of Gerota's fascia, the mesenteric root, the lesser omentum, the omental bursa, and the omental foramen is much more difficult or cannot be adequately assured using a laparoscopic treatment approach, even though inspection of these structures is of crucial importance for the completeness of surgical staging. Laparoscopy also does not allow for digital palpation of the abdominal structures. On the other hand, with laparoscopy, smaller structures, such as peritoneal implants or micrometastases, can be better visualized due to optical magnification using zoom functions or high-resolution 3D techniques. Furthermore, it allows for better visual access, for example when exploring the diaphragm, as the camera angle can be changed [23, 40]. To assess the technical feasibility in terms of equivalence compared to open surgery, various studies have looked at factors including the number of excised lymph nodes or the size of material excised from the omentum as measurement parameters; however, the studies conducted did not find any significant differences between the two surgical methods [5, 36, 41]. Another assessment criterion was the rate of higher classifications of the tumor stage as a result of discovering occult tumor manifestations [10, 40, 42, 43, 44]. Here it was suggested that laparoscopic staging would result in a higher classification at least as often as with access by laparotomy. In summary, these largely retrospective studies, mostly involving a small, highly selective number of cases, point to equivalence of these two approaches in terms of oncological safety [10, 40, 42, 43]. The validity of this conclusion needs to be critically assessed. In addition to the largely retrospective quality of the data from the available studies, the operations were not all performed in certified cancer centers, and the impact of the surgical approach on the survival outcomes was only evaluated in a few studies with

small case numbers. In general, the question of the technical feasibility and oncological safety of a laparoscopic approach when operating on ovarian carcinoma cannot be definitively answered due to the sparse and inadequate quality of the data.

2. Iatrogenic spread of tumor cells: Does the laparoscopic resection of ovarian tumors increase the risk of iatrogenic spread of malignant cells? This discussion is based on publications in which the rate of iatrogenic capsule rupture of ovarian tumors was found to be higher during a laparoscopic surgical procedure compared to laparotomy [45, 46, 47, 48]. In the event of cyst rupture, the tumor stages IA and IB become stage IC, with a poorer prognosis, and necessitating adjuvant chemotherapy [18, 48, 49, 50]. Matsuo et al. showed in a retrospective survey of patients with early ovarian carcinoma (stage I) that the minimally invasive approach compared to laparotomy was an independent risk factor for a significantly higher rate of iatrogenic capsule rupture [45]. The capsule rupture was associated with poorer overall survival [45]. When comparing the two surgical approaches, other studies showed no significant differences in rupture rates if a distinction was made between a primary approach to preserve the ovary or primarily pursuing an adnexectomy – with higher rupture rates when attempting to preserve the ovary [51]. Therefore, with suspected malignant tumors, an adnexectomy should always be chosen over cyst extirpation so as to avoid potential iatrogenic spread of malignant tumor cells [36]. Furthermore, it is common practice to use endobags to extract resected tissue of unclear dignity [52]. This is to prevent the spread of malignant cells, due for example to intra-abdominal cyst rupture, and the development of implantation metastases [41].
3. Operating time: the data on operating time also varies. Some studies showed a significantly shorter operating time if the surgical staging was performed by laparoscopy, while other studies showed a longer operating time [5, 40, 41, 53]. The authors of the studies also raised for discussion the question of whether the differences measured could be due to the experience of the surgeon rather than the surgical approach used [5, 40, 41, 53].
4. Fewer perioperative and postoperative complications: one argument for the laparoscopic surgical approach is the lower rate of perioperative and postoperative complications. Several case-control studies have shown significantly fewer postoperative complications after laparoscopy compared to laparotomy [10, 43, 53]. In particular, intraoperative blood loss and the need for blood transfusions was significantly lower in the laparoscopy arms of some studies [5, 40, 41, 43].
5. Iatrogenic influence factors: one of the iatrogenic influence factors under discussion is the effect of carbon dioxide, one of the main components of the gas used during laparoscopy, on the malignant cells. To date, it has only been demonstrated in cell cultures that carbon dioxide has a favorable effect on the growth of ovarian cancer cells [54]. Similarly, the suspicion that positive intra-abdominal pressure and the generation of pneumoperitoneum could disseminate tumor cells has only been observed in animal experiments to date [55]. The question of whether the carbon dioxide used changes the intra-abdominal pH, or whether positive pressure could damage the mesothelial cells, is also under discussion. It is possible that both factors would have a negative impact on the tumor [56, 57, 58]. However, based on the available clinical data, it cannot be demonstrated that possible dissemination of tumor cells as a result of pneumoperitoneum has any relevant influence on cancer survival rates [59, 60].
6. Implantation metastases: one reservation with regard to the laparoscopic surgical technique is based on the concern that metastases will form at the trocar insertion sites [61, 62]. Study results to date have not shown frequent formation of implantation metastases after laparoscopic operations in early ovarian carcinoma; accordingly, based on the currently available information, implantation metastases are more of a problem in advanced ovarian carcinoma with consecutive formation of ascites [3, 5, 53]. By contrast, Vergote et al. examined the development of implantation metastases after laparoscopies in advanced ovarian carcinoma, and were able to demonstrate implantation metastases occurring in 17% of the patients [63]. In another study by Heitz et al., implantation metastases occurred after diagnostic laparoscopy in advanced ovarian carcinoma in up to 47% of cases [64]. The etiology, possible preventive measures, and in particular the prognostic relevance of implantation metastases are debatable and require further research [60, 63]. The trocar insertion sites should always be placed in the midline below and above the navel so that any implantation metastases that may occur can then be resected in a longitudinal interval laparotomy.
7. Pathological evaluation: this could be more difficult with laparoscopic procedures (e.g., differentiating between FIGO stage IA and IC in the event of uncertain capsule/serosal rupture) if malignant structures are made smaller so as to remove them during the operation and this is not clearly documented.
8. Length of stay in hospital: studies on the length of stay in hospital have shown significantly fewer postoperative days in hospital in patients who underwent laparoscopy [36]. The laparoscopic approach is also associated with an expected reduction in time between the primary operation and the start of the adjuvant systemic therapy [3, 40, 52]. Due to the shorter postoperative convalescence time and lower rates of postoperative complications, it is likely that adjuvant systematic treatment can begin earlier due to the better general condition of the patient. However, it remains debatable whether this time saving has an influence on the overall prognosis.
9. Economics: looking at the economic factors, no clear conclusion can be drawn on whether either of the two surgical methods has an advantage over the other [36]. While costs are higher with a laparoscopic operation, due in particular to high material costs, laparotomy surgery results in longer postoperative stays in hospital.

In addition to the points mentioned here, there are currently no randomized controlled studies that provide information on the effect of the surgical approach on survival rates. In a current meta-analysis, Knisely et al. evaluated the available data on this topic from observational studies and randomized controlled studies [65]. The studies included in the analysis showed no differences in progression-free survival and in overall survival when comparing

the two surgical approaches [65]. However, the authors postulated that the results must be questioned critically due to the weaknesses in the methodology of the studies included, as well as the frequent lack of adjustment to different influence factors; as a result, no generally valid statements can be made [65].

In summary, no general recommendation for or against minimally invasive surgery in early ovarian carcinoma can be made based on the current state of knowledge due to lack of scientific data, and with some of the available data being contradictory [60]. According to the current German S3 guideline on diagnostics, therapy, and follow-up of malignant ovarian tumors, it is recommended to avoid laparoscopy if there are suspected malignant ovarian findings, even if it appears to be technically feasible to perform [1]. Until there are results from prospective studies that review laparoscopy in the treatment of ovarian carcinoma, and in particular that allow conclusions to be made regarding its influence on progression-free and overall survival, minimally invasive approaches should only be performed as part of studies [1].

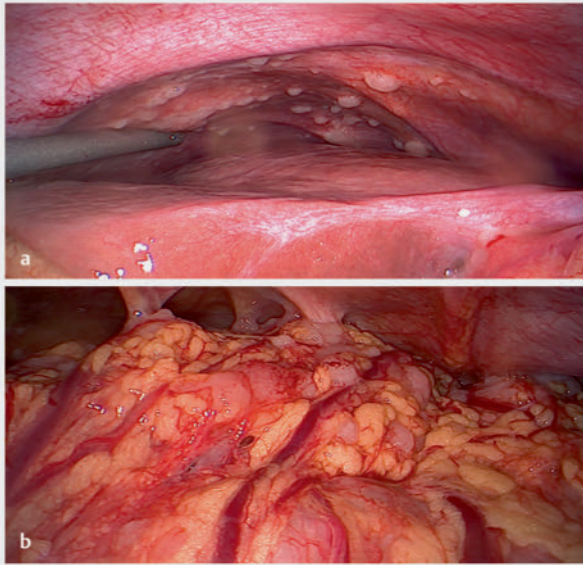
### The use of laparoscopic procedures in advanced ovarian carcinoma

The aim of the primary therapy in advanced ovarian carcinoma is macroscopic complete resection, i.e., the full surgical removal of all visible tumor manifestations during a tumor debulking operation [49, 66, 67, 68]. Results of prospective studies have shown that optimal cytoreduction is the most important influenceable prognosis factor for patients with ovarian carcinoma [49, 66]. Surgical debulking for advanced ovarian carcinoma is performed in the same way as surgical staging for early ovarian carcinoma, with the exception that standard systematic pelvic and para-aortic lymphonectomy is not performed in lymph nodes that are normal both macroscopically and in preoperative imaging [69]. Multi-visceral resections should be performed if this enables a macroscopic complete resection to be achieved [1]. In terms of surgical approach, midline longitudinal laparotomy is considered to be the gold standard. However, the question of when is the best time to operate – neoadjuvantly or adjuvantly – is a subject of heated debate. According to the current German S3 guideline, the primary operation followed by adjuvant systemic treatment is considered the standard treatment if it is likely that an optimum surgical result will be achieved [70, 71, 72]. The question of whether the malignancy can be fully resected becomes more complicated the more advanced the ovarian carcinoma is at the time of diagnosis (from FIGO stage IIIC to IV). Furthermore, a poor general condition or the presence of multiple comorbidities, as well as the patient's age, are all factors that may make it more difficult to achieve the optimum surgical result of completely resecting the tumor [73, 74]. Patients who have a high perioperative risk or for whom the likelihood of an optimal tumor debulking operation is very low can first receive neoadjuvant chemotherapy before subsequently undergoing interval debulking surgery [75]. In very advanced tumor stages, complete surgical resection was achieved significantly more frequently after neoadjuvant chemotherapy than with a primary operation [70, 76, 77]. Vergote et al. demonstrated that neoadjuvant chemotherapy with subsequent interval debulking was not inferior compared to a primary debulking operation in ad-

vanced ovarian carcinoma with regard to progression-free and overall survival [70]. Furthermore, a lower rate of perioperative and postoperative complications was observed in interval debulking operations compared to primary debulking operations [70]. Specifically, postoperative mortality (0.7% vs. 2.5%), bleeding complications (4.1% vs. 7.4%), and rates of infection were lower with interval debulking [70]. However, subanalyses also demonstrated that optimal cytoreduction by primary debulking operation was associated with a survival benefit compared to optimal cytoreduction by interval debulking surgery [70, 78, 79]. To further clarify the role of neoadjuvant chemotherapy, the current prospective randomized Trial of Radical Upfront Surgical Therapy in advanced ovarian cancer (TRUST) by the working group for gynecologic oncology is examining the influence of neoadjuvant vs. adjuvant chemotherapy on the overall survival in this patient cohort (FIGO stage IIIB–IVB). In summary, the initial assessment of whether or not surgery will be successful is crucial in order to be able to offer a primary debulking operation to patients with advanced ovarian carcinoma; however, it is also important to identify patients who would benefit from neoadjuvant chemotherapy to reduce perioperative and postoperative morbidity.

The question of operability and whether complete resection can be technically achieved is the key problem with advanced ovarian carcinoma. At an advanced stage of the disease, in addition to noninvasive imaging methods and histological confirmation of the diagnosis, diagnostic laparoscopy can be performed to assess the spread of the tumor and whether it is operable [63, 80, 81]. This means patients in whom optimal tumor debulking does not appear technically feasible can be identified, which can reduce the rate of suboptimal tumor debulking operations (postoperative tumor manifestations > 1 cm) [82, 83, 84, 85]. A key issue with assessing operability by laparoscopy is that some anatomical structures, particularly in the retroperitoneal region, are difficult to access, especially the mesenteric root, Gerota's fascia, and the omental bursa. An inadequate view of these structures may result in the operability being incorrectly assessed. ▶ **Fig. 1** shows intraoperative findings from diagnostic laparoscopy in a patient with advanced ovarian carcinoma in whom a complete resection was classified as possible, despite the fact that it had spread extensively. Other factors against diagnostic laparoscopy are the additional perioperative risk, the occurrence of implantation metastases, and the associated additional costs [85].

One of the most relevant randomized controlled studies examining the importance of diagnostic laparoscopy in advanced ovarian carcinoma was conducted in the Netherlands by Rutten et al. [83]. The study group evaluated the influence of diagnostic laparoscopy in assessing the operability for optimal tumor debulking. It was shown that in 90% of cases, an optimal surgical result could be achieved by laparotomy if the site was classified as operable (postoperative residual tumor ≤ 1 cm in diameter) beforehand by laparoscopy. In the control group, laparotomy was performed without prior laparoscopy and the complete resection was only successful in 61% of cases [83]. Several studies found that an optimal surgical result could be achieved in 80–96% of cases if the site was classified as operable beforehand by diagnostic laparoscopy [80, 81, 84, 86, 87]. The working group of Fagotti et al. also developed the “Predictive Index Value (PIV)”, a validatable points sys-



► **Fig. 1** Fig. Diagnostic laparoscopy findings, a perihepatic, nodular implants; b omental cake with adhesions on the abdominal wall.

tem with objectifiable parameters, which is used as a basis to predict the likelihood of a successful complete resection of ovarian carcinoma during a laparotomy procedure [88]. The points system is based on the presence or absence of the eight laparoscopy findings listed in ► **Table 1** [88]. In the validation study conducted by the working group, a score of  $\geq 8$  was associated with a suboptimal operation result with a specificity of 100%, a positive predictive value (PPV) of 100%, and a negative predictive value (NPV) of 70% [88]. Another study by Brun et al., which aimed to validate the described scoring system, showed a specificity of only 89%, with a PPV of 89%, and an NPV of 44% [89, 90]. Other validation studies are still currently pending. Despite the proven predictive power of diagnostic laparoscopy with regard to the achievable operation result, to date no positive influence on survival rates has been proven. Although diagnostic laparoscopy could significantly reduce the rate of suboptimal operation results, a study by Rutten et al. did not show an improvement of the mean progression-free survival or overall survival compared to the control group of patients in whom a primary debulking operation was performed without prior assessment of operability by laparoscopy [83]. According to the current state of science, the rationale behind diagnostic laparoscopy is not to improve survival rates, but to reduce perioperative morbidity by avoiding suboptimal debulking operations in patients who have been correctly classified as inoperable by diagnostic laparoscopy. This seems to be highly relevant, especially with frail patients [73, 91]. Unlike the American guideline, which has included diagnostic laparoscopy in the recommended treatment algorithm, the current German S3 guideline on diagnostics, therapy and follow-up of malignant ovarian tumors makes no statement with regard to diagnostic laparoscopy [1, 92].

There are only a few studies investigating whether a tumor debulking operation can be performed primarily by laparoscopy in

► **Table 1** Laparoscopy parameters for determining the PIV (based on Fagotti et al., 2006).

Laparoscopy parameters	Score
Ovarian tumor (unilateral or bilateral)	0
Omental cake	2
Peritoneal carcinosis	2
Diaphragmatic carcinosis	2
Mesenteric retraction	2
Infiltration of the stomach	2
Infiltration of the bowel	2
Liver metastases	2

advanced ovarian carcinoma. Ceccaroni et al. conducted purely laparoscopic tumor debulking in 21 patients and achieved complete macroscopic resection in 95%, whereas in the study group in which tumor debulking was performed via laparotomy, complete macroscopic resection could only be achieved in 88% of the operations [93]. The rates of perioperative and postoperative complications were higher in the laparotomy arm, and the mean time before starting adjuvant systemic therapy was 15 days in the laparoscopy arm vs. 28 days in the laparotomy arm [93]. When interpreting these data, it must be stated that the inclusion criteria for the study were highly selective, the case number was very small, and the characteristics and tumor-specific factors of the patients in the laparoscopy arm were different to those in the laparotomy arm. The patients were first divided up into one of the two study arms based on diagnostic laparoscopy, and only 21 of the 66 patients (31.8%) were classified as suitable for a laparoscopic operation – for the rest of the patients, the tumor debulking operation was performed after conversion to laparotomy [93]. Exclusion criteria for laparoscopic debulking included the presence of more than two liver metastases or requiring more than two small intestinal resections, presence of multiple or bilateral diaphragmatic infiltrations, or the presence of “omental cake” [93]. As a result, the tumor spread was considerably larger in the patients in the laparotomy arm [93]. In the analysis of the patient characteristics, the patients in the laparoscopic arm had a lower body mass index and lower American Society of Anesthesiologists (ASA) scores [93]. Despite the significant limitations, the study results provide indications that a highly selected patient cohort could benefit from laparoscopic treatment approaches, even if the ovarian carcinoma is advanced [94]. The available case descriptions in the literature must be subjected to a highly critical assessment, particularly with regard to advanced ovarian carcinoma. These case reports cannot be used to make general statements. More studies are needed, in particular prospective randomized studies.

### Second-look operation

A second-look operation by laparoscopy or laparotomy served to determine the presence of residual tumors if there were no correlates in noninvasive imaging procedures, and to evaluate whether

the tumor had responded fully to the treatment after the primary therapy was completed. This concept gained in significance for ovarian carcinoma in the 1970s and 1980s [95, 96, 97]. During this time, various studies have been conducted to investigate whether the detection and resection of these residual tumor manifestations after the primary operation and subsequent adjuvant systemic therapy is beneficial for the patient. However, no improvement in the oncological prognosis could be determined; therefore, according to the current guideline, second-look operations should not be performed [1, 95, 96, 97].

## Summary and Outlook

Over the last few decades minimally invasive surgical methods have become more and more common in clinical daily practice, including in gynecology. Laparoscopy has become the gold standard for surgical treatment of benign ovarian tumors due to the lower rates of perioperative complications and earlier mobilization. Laparoscopy is also gaining importance in gynecologic oncology and has been convincingly validated in prospective studies, e.g., for early endometrial carcinoma. The current studies on ovarian carcinoma are less clear. Initial data indicate that complete surgical staging by laparoscopy in early ovarian carcinoma does not appear to be inferior to laparotomy, and patients could benefit from the advantages of minimally invasive surgical methods. However, it is necessary to question critically whether surgical staging is technically feasible with laparoscopy. There are currently no prospective randomized controlled studies to evaluate the influence of the chosen surgical approach on progression-free and overall survival [36]. Available studies that discuss the topic often only included a small number of subjects, the reported follow-up times vary greatly, and the effects of the surgical method on the survival rates were often not presented [36]. The studies that examined progression-free and overall survival showed different results, partially in favor of laparoscopy and partially in favor of laparotomy [10, 40, 41, 98]. Due to the widely varying patient cohort and follow-up times, the individual studies cannot be adequately compared with each other [36]. It is also more difficult to validate laparoscopy as a surgical method for (early) ovarian carcinoma due to the relatively low incidence of ovarian carcinoma being diagnosed in the early stage. Until other scientific findings are available, the German S3 guideline on diagnostics, therapy, and follow-up of malignant ovarian tumors recommends avoiding laparoscopic surgical procedures if there is suspicion of a malignant manifestation in the ovary [1]. However, based on the available studies it can be hypothesized that highly selected patient cohorts could benefit from laparoscopic staging in early ovarian carcinoma, particularly in view of the lower rate of perioperative morbidity. The guidelines of the National Comprehensive Cancer Network (NCCN) point out that a minimally invasive procedure performed by a highly experienced surgeon may be considered in selected patients [92]. With regard to the diagnostic benefit of laparoscopy, several studies have shown that the operability could be predicted, but they did not show a benefit in terms of the survival rates [70]. Nevertheless, diagnostic laparoscopy can help reduce perioperative and postoperative complications by identifying inoperable patients who can benefit from neoadjuvant systemic

treatment and subsequent interval debulking. Overall, it remains to be seen whether over the next few years there will be a paradigm shift in the surgical treatment of ovarian carcinoma, and whether diagnostic laparoscopy will become established in the treatment algorithm for ovarian carcinoma. Interesting insights on these topics can be expected over the coming decades, including from the field of robotic surgery.

## Conflict of Interest

The authors declare that they have no conflict of interest.

## References/Literatur

- [1] Wagner U, Reuß A. S3-Leitlinie „Diagnostik, Therapie und Nachsorge maligner Ovarialtumoren“: Leitlinienprogramm Onkologie, Deutsche Krebsgesellschaft, Deutsche Krebshilfe, AWMF: Langversion 3.0, 2019, AWMF-Registernummer: 032/035OL. Forum 2019; 34: 413–415. doi:10.1007/s12312-019-00671-4
- [2] Colomer AT, Jiménez AM, Bover Barceló MI. Laparoscopic treatment and staging of early ovarian cancer. *J Minim Invasive Gynecol* 2008; 15: 414–419. doi:10.1016/j.jmig.2008.04.002
- [3] Nezhat FR, Ezzati M, Chuang L et al. Laparoscopic management of early ovarian and fallopian tube cancers: surgical and survival outcome. *Am J Obstet Gynecol* 2009; 200: 83.e1–83.e6. doi:10.1016/j.ajog.2008.08.013
- [4] Pomel C, Provencher D, Dauplat J et al. Laparoscopic staging of early ovarian cancer. *Gynecol Oncol* 1995; 58: 301–306. doi:10.1006/gyno.1995.1234
- [5] Chi DS, Abu-Rustum NR, Sonoda Y et al. The safety and efficacy of laparoscopic surgical staging of apparent stage I ovarian and fallopian tube cancers. *Am J Obstet Gynecol* 2005; 192: 1614–1619. doi:10.1016/j.ajog.2004.11.018
- [6] Lawrie TA, Medeiros LRF, Rosa DD et al. Laparoscopy versus laparotomy for FIGO stage I ovarian cancer. *Cochrane Database Syst Rev* 2013(2): CD005344. doi:10.1002/14651858.CD005344.pub3
- [7] Borgfeldt C, Andolf E. Transvaginal sonographic ovarian findings in a random sample of women 25–40 years old. *Ultrasound Obstet Gynecol* 1999; 13: 345–350. doi:10.1046/j.1469-0705.1999.13050345.x
- [8] Padilla LA, Radosevich DM, Milad MP. Accuracy of the pelvic examination in detecting adnexal masses. *Obstet Gynecol* 2000; 96: 593–598. doi:10.1016/s0029-7844(00)00970-4
- [9] Wolf SI, Gosink BB, Feldesman MR et al. Prevalence of simple adnexal cysts in postmenopausal women. *Radiology* 1991; 180: 65–71. doi:10.1148/radiology.180.1.2052725
- [10] Park JY, Kim DY, Suh DS et al. Comparison of laparoscopy and laparotomy in surgical staging of early-stage ovarian and fallopian tubal cancer. *Ann Surg Oncol* 2008; 15: 2012–2019. doi:10.1245/s10434-008-9893-2
- [11] Pados G, Tsolakidis D, Bontis J. Laparoscopic management of the adnexal mass. *Ann N Y Acad Sci* 2006; 1092: 211–228. doi:10.1196/annals.1365.018
- [12] Leng J, Lang J, Zhang J et al. Role of laparoscopy in the diagnosis and treatment of adnexal masses. *Chin Med J (Engl)* 2006; 119: 202–206
- [13] Lee JW, Kim CJ, Lee JE et al. Selected adnexal cystic masses in postmenopausal women can be safely managed by laparoscopy. *J Korean Med Sci* 2005; 20: 468–472. doi:10.3346/jkms.2005.20.3.468

- [14] Nezhat F, Nezhat C, Welander CE et al. Four ovarian cancers diagnosed during laparoscopic management of 1011 women with adnexal masses. *Am J Obstet Gynecol* 1992; 167: 790–796. doi:10.1016/s0002-9378(19)1591-9
- [15] Mecke H, Lehmann-Willenbrock E, Ibrahim M et al. Pelvicoscopic treatment of ovarian cysts in premenopausal women. *Gynecol Obstet Invest* 1992; 34: 36–42. doi:10.1159/000292722
- [16] Fishman DA, Cohen L, Blank SV et al. The role of ultrasound evaluation in the detection of early-stage epithelial ovarian cancer. *Am J Obstet Gynecol* 2005; 192: 1214–1221. doi:10.1016/j.ajog.2005.01.041
- [17] Wenzl R, Lehner R, Husslein P et al. Laparoscopic surgery in cases of ovarian malignancies: an Austria-wide survey. *Gynecol Oncol* 1996; 63: 57–61. doi:10.1006/gyno.1996.0278
- [18] Muzii L, Angioli R, Zullo M et al. The unexpected ovarian malignancy found during operative laparoscopy: incidence, management, and implications for prognosis. *J Minim Invasive Gynecol* 2005; 12: 81–89. doi:10.1016/j.jmig.2004.12.019
- [19] Nohuz E, De Simone L, Chêne G. Reliability of IOTA score and ADNEX model in the screening of ovarian malignancy in postmenopausal women. *J Gynecol Obstet Hum Reprod* 2019; 48: 103–107. doi:10.1016/j.jogoh.2018.04.012
- [20] Van Calster B, Van Hoorde K, Valentin L et al. Evaluating the risk of ovarian cancer before surgery using the ADNEX model to differentiate between benign, borderline, early and advanced stage invasive, and secondary metastatic tumours: prospective multicentre diagnostic study. *BMJ* 2014; 349: g5920. doi:10.1136/bmj.g5920
- [21] Araujo KG, Jales RM, Pereira PN et al. Performance of the IOTA ADNEX model in preoperative discrimination of adnexal masses in a gynecological oncology center. *Ultrasound Obstet Gynecol* 2017; 49: 778–783. doi:10.1002/uog.15963
- [22] Szubert S, Wojtowicz A, Moczynski R et al. External validation of the IOTA ADNEX model performed by two independent gynecologic centers. *Gynecol Oncol* 2016; 142: 490–495. doi:10.1016/j.ygyno.2016.06.020
- [23] Gad MS, El Khoully NI, Soto E et al. Differences in perioperative outcomes after laparoscopic management of benign and malignant adnexal masses. *J Gynecol Oncol* 2011; 22: 18–24. doi:10.3802/jgo.2011.22.1.18
- [24] Canis M, Pouly JL, Wattiez A et al. Laparoscopic management of adnexal masses suspicious at ultrasound. *Obstet Gynecol* 1997; 89: 679–683. doi:10.1016/S0029-7844(97)81436-6
- [25] Biran G, Golan A, Sagiv R et al. Conversion of laparoscopy to laparotomy due to adnexal malignancy. *Eur J Gynaecol Oncol* 2002; 23: 157–160
- [26] Dottino PR, Levine DA, Ripley DL et al. Laparoscopic management of adnexal masses in premenopausal and postmenopausal women. *Obstet Gynecol* 1999; 93: 223–228. doi:10.1016/s0029-7844(98)00425-6
- [27] Stier EA, Barakat RR, Curtin JP et al. Laparotomy to complete staging of presumed early ovarian cancer. *Obstet Gynecol* 1996; 87: 737–740. doi:10.1016/0029-7844(96)00021-x
- [28] Soper JT, Johnson P, Johnson V et al. Comprehensive restaging laparotomy in women with apparent early ovarian carcinoma. *Obstet Gynecol* 1992; 80: 949–953
- [29] Young RC, Decker DG, Wharton JT et al. Staging laparotomy in early ovarian cancer. *JAMA* 1983; 250: 3072–3076
- [30] Grabowski JP, Harter P, Buhrmann C et al. Re-operation outcome in patients referred to a gynecologic oncology center with presumed ovarian cancer FIGO I-IIIa after sub-standard initial surgery. *Surg Oncol* 2012; 21: 31–35. doi:10.1016/j.suronc.2010.08.006
- [31] Trimbos JB, Vergote I, Bolis G et al. Impact of adjuvant chemotherapy and surgical staging in early-stage ovarian carcinoma: European Organisation for Research and Treatment of Cancer-Adjuvant Chemotherapy in Ovarian Neoplasm trial. *J Natl Cancer Inst* 2003; 95: 113–125
- [32] Trimbos B, Timmers P, Pecorelli S et al. Surgical staging and treatment of early ovarian cancer: long-term analysis from a randomized trial. *J Natl Cancer Inst* 2010; 102: 982–987. doi:10.1093/jnci/djq149
- [33] du Bois A, Rochon J, Pfisterer J et al. Variations in institutional infrastructure, physician specialization and experience, and outcome in ovarian cancer: a systematic review. *Gynecol Oncol* 2009; 112: 422–436. doi:10.1016/j.ygyno.2008.09.036
- [34] Rosenoff SH, Young RC, Anderson T et al. Peritoneoscopy: a valuable staging tool in ovarian carcinoma. *Ann Intern Med* 1975; 83: 37–41. doi:10.7326/0003-4819-83-1-37
- [35] Spinelli P, Luini A, Pizzetti P et al. Laparoscopy in staging and restaging of 95 patients with ovarian carcinoma. *Tumori* 1976; 62: 493–501. doi:10.1177/030089167606200504
- [36] Medeiros LRF, Rosa DD, Bozzetti MC et al. Laparoscopy versus laparotomy for FIGO Stage I ovarian cancer. *Cochrane Database Syst Rev* 2008(4): CD005344. doi:10.1002/14651858.CD005344.pub2
- [37] Conrad LB, Ramirez PT, Burke W et al. Role of Minimally Invasive Surgery in Gynecologic Oncology: An Updated Survey of Members of the Society of Gynecologic Oncology. *Int J Gynecol Cancer* 2015; 25: 1121–1127. doi:10.1097/IGC.0000000000000450
- [38] Matsuo K, Chang EJ, Matsuzaki S et al. Minimally invasive surgery for early-stage ovarian cancer: Association between hospital surgical volume and short-term perioperative outcomes. *Gynecol Oncol* 2020; 158: 59–65. doi:10.1016/j.ygyno.2020.04.045
- [39] Park HJ, Kim DW, Yim GW et al. Staging laparoscopy for the management of early-stage ovarian cancer: a metaanalysis. *Am J Obstet Gynecol* 2013; 209: 58.e1–58.e8. doi:10.1016/j.ajog.2013.04.013
- [40] Ghezzi F, Cromi A, Uccella S et al. Laparoscopy versus laparotomy for the surgical management of apparent early stage ovarian cancer. *Gynecol Oncol* 2007; 105: 409–413. doi:10.1016/j.ygyno.2006.12.025
- [41] Park JY, Bae J, Lim MC et al. Laparoscopic and laparotomic staging in stage I epithelial ovarian cancer: a comparison of feasibility and safety. *Int J Gynecol Cancer* 2008; 18: 1202–1209. doi:10.1111/j.1525-1438.2008.01190.x
- [42] Weber S, McCann CK, Boruta DM et al. Laparoscopic Surgical Staging of Early Ovarian Cancer. *Rev Obstet Gynecol* 2011; 4: 117–122
- [43] Hua K, Jin F, Xu H et al. Evaluation of laparoscopic surgery in the early stage-malignant tumor of ovary with lower risk. *Zhonghua Yi Xue Za Zhi* 2005; 85: 169–172
- [44] Minig L, Saadi J, Patrono MG et al. Laparoscopic surgical staging in women with early stage epithelial ovarian cancer performed by recently certified gynecologic oncologists. *Eur J Obstet Gynecol Reprod Biol* 2016; 201: 94–100. doi:10.1016/j.ejogrb.2016.03.029
- [45] Matsuo K, Huang Y, Matsuzaki S et al. Minimally Invasive Surgery and Risk of Capsule Rupture for Women With Early-Stage Ovarian Cancer. *JAMA Oncol* 2020; 6: 1110–1113. doi:10.1001/jamaoncol.2020.1702
- [46] Matsuo K, Machida H, Yamagami W et al. Intraoperative Capsule Rupture, Postoperative Chemotherapy, and Survival of Women With Stage I Epithelial Ovarian Cancer. *Obstet Gynecol* 2019; 134: 1017–1026. doi:10.1097/AOG.00000000000003507
- [47] Kim HS, Ahn JH, Chung HH et al. Impact of intraoperative rupture of the ovarian capsule on prognosis in patients with early-stage epithelial ovarian cancer: a meta-analysis. *Eur J Surg Oncol* 2013; 39: 279–289. doi:10.1016/j.ejso.2012.12.003
- [48] Vergote I, De Brabanter J, Fyles A et al. Prognostic importance of degree of differentiation and cyst rupture in stage I invasive epithelial ovarian carcinoma. *Lancet* 2001; 357: 176–182. doi:10.1016/S0140-6736(00)3590-X
- [49] Ataseven B, Grimm C, Harter P et al. Prognostic impact of debulking surgery and residual tumor in patients with epithelial ovarian cancer FIGO stage IV. *Gynecol Oncol* 2016; 140: 215–220. doi:10.1016/j.ygyno.2015.12.007
- [50] Sjövall K, Nilsson B, Einhorn N. Different types of rupture of the tumor capsule and the impact on survival in early ovarian carcinoma. *Int J Gynecol Cancer* 1994; 4: 333–336. doi:10.1046/j.1525-1438.1994.04050333.x



- [51] Gal D, Lind L, Lovecchio JL et al. Comparative study of laparoscopy vs. laparotomy for adnexal surgery: efficacy, safety, and cyst rupture. *J Gynecol Surg* 1995; 11: 153–158. doi:10.1089/gyn.1995.11.153
- [52] Tozzi R, Köhler C, Ferrara A et al. Laparoscopic treatment of early ovarian cancer: surgical and survival outcomes. *Gynecol Oncol* 2004; 93: 199–203. doi:10.1016/j.ygyno.2004.01.004
- [53] Lee M, Kim SW, Paek J et al. Comparisons of surgical outcomes, complications, and costs between laparotomy and laparoscopy in early-stage ovarian cancer. *Int J Gynecol Cancer* 2011; 21: 251–256. doi:10.1097/IGC.0b013e318208c71c
- [54] Smidt VJ, Singh DM, Hurteau JA et al. Effect of carbon dioxide on human ovarian carcinoma cell growth. *Am J Obstet Gynecol* 2001; 185: 1314–1317. doi:10.1067/mob.2001.119079
- [55] Dorrance HR, Oien K, O'Dwyer PJ. Effects of laparoscopy on intraperitoneal tumor growth and distant metastases in an animal model. *Surgery* 1999; 126: 35–40. doi:10.1067/msy.1999.99056
- [56] Bergström M, Falk P, Park P-O et al. Peritoneal and systemic pH during pneumoperitoneum with CO<sub>2</sub> and helium in a pig model. *Surg Endosc* 2008; 22: 359–364. doi:10.1007/s00464-007-9409-3
- [57] Greene FL. Principles of Cancer Biology in Relation to Minimal Access Surgical Techniques. *Semin Laparosc Surg* 1995; 2: 155–157. doi:10.1053/SLAS00200155
- [58] Volz J, Köster S, Spacek Z et al. The influence of pneumoperitoneum used in laparoscopic surgery on an intraabdominal tumor growth. *Cancer* 1999; 86: 770–774
- [59] Abu-Rustum NR, Sonoda Y, Chi DS et al. The effects of CO<sub>2</sub> pneumoperitoneum on the survival of women with persistent metastatic ovarian cancer. *Gynecol Oncol* 2003; 90: 431–434. doi:10.1016/s0090-8258(03)00330-5
- [60] Liu CS, Nagarsheth NP, Nezhath FR. Laparoscopy and ovarian cancer: a paradigm change in the management of ovarian cancer? *J Minim Invasive Gynecol* 2009; 16: 250–262. doi:10.1016/j.jmig.2009.01.007
- [61] Ramirez PT, Wolf JK, Levenback C. Laparoscopic port-site metastases: etiology and prevention. *Gynecol Oncol* 2003; 91: 179–189. doi:10.1016/s0090-8258(03)00507-9
- [62] Nagarsheth NP, Rahaman J, Cohen CJ et al. The incidence of port-site metastases in gynecologic cancers. *JLS* 2004; 8: 133–139
- [63] Morice P, Camatte S, Larregain-Fournier D et al. Port-site implantation after laparoscopic treatment of borderline ovarian tumors. *Obstet Gynecol* 2004; 104: 1167–1170. doi:10.1097/01.AOG.0000124988.46203.f2
- [64] Heitz F, Ognjenovic D, Harter P et al. Abdominal wall metastases in patients with ovarian cancer after laparoscopic surgery: incidence, risk factors, and complications. *Int J Gynecol Cancer* 2010; 20: 41–46. doi:10.1111/IGC.0b013e3181c443ba
- [65] Knisely A, Gamble CR, St Clair CM et al. The Role of Minimally Invasive Surgery in the Care of Women with Ovarian Cancer: A Systematic Review and Meta-analysis. *J Minim Invasive Gynecol* 2021; 28: 537–543. doi:10.1016/j.jmig.2020.11.007
- [66] du Bois A, Reuss A, Pujade-Lauraine E et al. Role of surgical outcome as prognostic factor in advanced epithelial ovarian cancer: a combined exploratory analysis of 3 prospectively randomized phase 3 multicenter trials: by the Arbeitsgemeinschaft Gynaekologische Onkologie Studien-gruppe Ovarialkarzinom (AGO-OVAR) and the Groupe d'Investigateurs Nationaux Pour les Etudes des Cancers de l'Ovaire (GINECO). *Cancer* 2009; 115: 1234–1244. doi:10.1002/cncr.24149
- [67] Bristow RE, Tomacruz RS, Armstrong DK et al. Survival effect of maximal cytoreductive surgery for advanced ovarian carcinoma during the platinum era: a meta-analysis. *J Clin Oncol* 2002; 20: 1248–1259. doi:10.1200/JCO.2002.20.5.1248
- [68] Chang S-J, Hodeib M, Chang J et al. Survival impact of complete cytoreduction to no gross residual disease for advanced-stage ovarian cancer: a meta-analysis. *Gynecol Oncol* 2013; 130: 493–498. doi:10.1016/j.ygyno.2013.05.040
- [69] Harter P, Sehoul J, Lorusso D et al. A Randomized Trial of Lymphadenectomy in Patients with Advanced Ovarian Neoplasms. *N Engl J Med* 2019; 380: 822–832. doi:10.1056/NEJMoa1808424
- [70] Vergote I, Tropé CG, Amant F et al. Neoadjuvant Chemotherapy or Primary Surgery in Stage IIIC or IV Ovarian Cancer. *N Engl J Med* 2010; 363: 943–953. doi:10.1056/NEJMoa0908806
- [71] van der Burg ME, van Lent M, Buyse M et al. The effect of debulking surgery after induction chemotherapy on the prognosis in advanced epithelial ovarian cancer. Gynecological Cancer Cooperative Group of the European Organization for Research and Treatment of Cancer. *N Engl J Med* 1995; 332: 629–634. doi:10.1056/NEJM199503093321002
- [72] Rose PG, Nerenstone S, Brady MF et al. Secondary surgical cytoreduction for advanced ovarian carcinoma. *N Engl J Med* 2004; 351: 2489–2497. doi:10.1056/NEJMoa041125
- [73] Anic K, Birkert S, Schmidt MW et al. G-8 Geriatric Screening Tool Independently Predicts Progression-Free Survival in Older Ovarian Cancer Patients Irrespective of Maximal Surgical Effort: Results of a Retrospective Cohort Study. *Gerontology* 2022; 68: 1101–1110. doi:10.1159/000520328
- [74] Anic K, Schmidt MW, Schmidt M et al. Impact of perioperative red blood cell transfusion, anemia of cancer and global health status on the prognosis of elderly patients with endometrial and ovarian cancer. *Front Oncol* 2022; 12: 967421. doi:10.3389/fonc.2022.967421
- [75] Wright AA, Bohlke K, Armstrong DK et al. Neoadjuvant Chemotherapy for Newly Diagnosed, Advanced Ovarian Cancer: Society of Gynecologic Oncology and American Society of Clinical Oncology Clinical Practice Guideline. *J Clin Oncol* 2016; 34: 3460–3473. doi:10.1200/JCO.2016.68.6907
- [76] Kang S, Nam BH. Does neoadjuvant chemotherapy increase optimal cytoreduction rate in advanced ovarian cancer? Meta-analysis of 21 studies. *Ann Surg Oncol* 2009; 16: 2315–2320. doi:10.1245/s10434-009-0558-6
- [77] Kehoe S, Hook J, Nankivell M et al. Primary chemotherapy versus primary surgery for newly diagnosed advanced ovarian cancer (CHORUS): an open-label, randomised, controlled, non-inferiority trial. *Lancet* 2015; 386: 249–257. doi:10.1016/S0140-6736(14)62223-6
- [78] Greimel E, Kristensen GB, van der Burg MEL et al. Quality of life of advanced ovarian cancer patients in the randomized phase III study comparing primary debulking surgery versus neo-adjuvant chemotherapy. *Gynecol Oncol* 2013; 131: 437–444. doi:10.1016/j.ygyno.2013.08.014
- [79] Vergote I, Coens C, Nankivell M et al. Neoadjuvant chemotherapy versus debulking surgery in advanced tubo-ovarian cancers: pooled analysis of individual patient data from the EORTC 55971 and CHORUS trials. *Lancet Oncol* 2018; 19: 1680–1687. doi:10.1016/S1470-2045(18)30566-7
- [80] Fagotti A, Fanfani F, Ludovisi M et al. Role of laparoscopy to assess the chance of optimal cytoreductive surgery in advanced ovarian cancer: a pilot study. *Gynecol Oncol* 2005; 96: 729–735. doi:10.1016/j.ygyno.2004.11.031
- [81] Angioli R, Palaia I, Zullo MA et al. Diagnostic open laparoscopy in the management of advanced ovarian cancer. *Gynecol Oncol* 2006; 100: 455–461. doi:10.1016/j.ygyno.2005.09.060
- [82] Gómez-Hidalgo NR, Martínez-Cannon BA, Nick AM et al. Predictors of optimal cytoreduction in patients with newly diagnosed advanced-stage epithelial ovarian cancer: time to incorporate laparoscopic assessment into the standard of care. *Gynecol Oncol* 2015; 137: 553–558. doi:10.1016/j.ygyno.2015.03.049
- [83] Rutten MJ, van Meurs HS, van de Vrie R et al. Laparoscopy to Predict the Result of Primary Cytoreductive Surgery in Patients With Advanced Ovarian Cancer: A Randomized Controlled Trial. *J Clin Oncol* 2017; 35: 613–621. doi:10.1200/JCO.2016.69.2962
- [84] Petrillo M, Vizzielli G, Fanfani F et al. Definition of a dynamic laparoscopic model for the prediction of incomplete cytoreduction in advanced epithelial ovarian cancer: proof of a concept. *Gynecol Oncol* 2015; 139: 5–9. doi:10.1016/j.ygyno.2015.07.095

- [85] Zeff N. Role of laparoscopy in initial tumour staging in advanced epithelial ovarian cancer: A systematic review. *Pleura Peritoneum* 2018; 3: 20180106. doi:10.1515/pp-2018-0106
- [86] Ansquer Y, Leblanc E, Clough K et al. Neoadjuvant chemotherapy for unresectable ovarian carcinoma: a French multicenter study. *Cancer* 2001; 91: 2329–2334
- [87] Deffieux X, Castaigne D, Pomel C. Role of laparoscopy to evaluate candidates for complete cytoreduction in advanced stages of epithelial ovarian cancer. *Int J Gynecol Cancer* 2006; 16 (Suppl 1): 35–40. doi:10.1111/j.1525-1438.2006.00323.x
- [88] Fagotti A, Ferrandina G, Fanfani F et al. A laparoscopy-based score to predict surgical outcome in patients with advanced ovarian carcinoma: a pilot study. *Ann Surg Oncol* 2006; 13: 1156–1161. doi:10.1245/ASO.2006.08.021
- [89] Brun J-L, Rouzier R, Uzan S et al. External validation of a laparoscopic-based score to evaluate resectability of advanced ovarian cancers: clues for a simplified score. *Gynecol Oncol* 2008; 110: 354–359. doi:10.1016/j.ygyno.2008.04.042
- [90] Rutten MJ, Leeflang MMG, Kenter GG et al. Laparoscopy for diagnosing resectability of disease in patients with advanced ovarian cancer. *Cochrane Database Syst Rev* 2014(2): CD009786. doi:10.1002/14651858.CD009786.pub2
- [91] Anic K, Althoefler C, Krajnak S et al. The preoperative G8 geriatric screening tool independently predicts survival in older patients with endometrial cancer: results of a retrospective single-institution cohort study. *J Cancer Res Clin Oncol* 2022. doi:10.1007/s00432-022-03934-1
- [92] Armstrong DK, Alvarez RD, Bakkum-Gamez JN et al. Ovarian Cancer, Version 2.2020, NCCN Clinical Practice Guidelines in Oncology. *J Natl Compr Canc Netw* 2021; 19: 191–226. doi:10.6004/jnccn.2021.0007
- [93] Ceccaroni M, Roviglione G, Bruni F et al. Laparoscopy for primary cytoreduction with multivisceral resections in advanced ovarian cancer: prospective validation. „The times they are a-changin“? *Surg Endosc* 2018; 32: 2026–2037. doi:10.1007/s00464-017-5899-9
- [94] Gueli Alletti S, Capozzi VA, Rosati A et al. Laparoscopy vs. laparotomy for advanced ovarian cancer: a systematic review of the literature. *Minerva Med* 2019; 110: 341–357. doi:10.23736/S0026-4806.19.06132-9
- [95] Nicoletto MO, Tumolo S, Talamini R et al. Surgical second look in ovarian cancer: a randomized study in patients with laparoscopic complete remission—a Northeastern Oncology Cooperative Group-Ovarian Cancer Cooperative Group Study. *J Clin Oncol* 1997; 15: 994–999. doi:10.1200/JCO.1997.15.3.994
- [96] Ott HW, Illmensee K, Zeimet A et al. The evaluation of the second-look operation of patients with ovarian carcinoma and tubal carcinoma by means of a retrospective comparison study. *Gynakol Geburtshilfliche Rundsch* 2002; 42: 217–224. doi:10.1159/000065152
- [97] Greer BE, Bundy BN, Ozols RF et al. Implications of second-look laparotomy in the context of optimally resected stage III ovarian cancer: a non-randomized comparison using an explanatory analysis: a Gynecologic Oncology Group study. *Gynecol Oncol* 2005; 99: 71–79. doi:10.1016/j.ygyno.2005.05.012
- [98] Wu TI, Lee CL, Liao PJ et al. Survival impact of initial surgical approach in stage I ovarian cancer. *Chang Gung Med J* 2010; 33: 558–567