

# Resection depth for small colorectal polyps comparing cold snare polypectomy, hot snare polypectomy and underwater endoscopic mucosal resection



## Authors

Junki Toyosawa<sup>1,2</sup>, Yasushi Yamasaki<sup>1,2</sup>, Tsuyoshi Fujimoto<sup>1</sup>, Shouichi Tanaka<sup>1</sup>, Takehiro Tanaka<sup>3</sup>, Toshiharu Mitsuhashi<sup>4</sup>, Hiroyuki Okada<sup>2</sup>

## Institutions

- 1 Department of Gastroenterology, Iwakuni Clinical Center, Yamaguchi, Japan
- 2 Department of Gastroenterology, Okayama University Hospital, Okayama, Japan
- 3 Department of Pathology, Okayama University Graduate School of Medicine, Dentistry, and Pharmaceutical Sciences, Okayama, Japan
- 4 Center for Innovative Clinical Medicine, Okayama University Hospital, Okayama, Japan

submitted 22.10.2021

accepted after revision 26.11.2021

## Bibliography

Endosc Int Open 2022; 10: E602–E608

DOI 10.1055/a-1785-8616

ISSN 2364-3722

© 2022. The Author(s).

This is an open access article published by Thieme under the terms of the Creative Commons Attribution-NonDerivative-NonCommercial License, permitting copying and reproduction so long as the original work is given appropriate credit. Contents may not be used for commercial purposes, or adapted, remixed, transformed or built upon. (<https://creativecommons.org/licenses/by-nc-nd/4.0/>)

Georg Thieme Verlag KG, Rüdigerstraße 14,  
70469 Stuttgart, Germany

## Corresponding author

Yasushi Yamasaki, Department of Gastroenterology, Okayama University Hospital, 2-5-1 Shikata-cho, Kita-ku, Okayama 700-8558, Japan

Fax: +81-86-225-5991

yasshifive@yahoo.co.jp

Supplementary material is available under  
<https://doi.org/10.1055/a-1785-8616>

## ABSTRACT

**Background and study aims** Small colorectal polyps are removed by various methods, including cold snare polypectomy (CSP), hot snare polypectomy (HSP), and underwater endoscopic mucosal resection (UEMR), but the indications for using these methods are unclear. We retrospectively assessed the efficacy of CSP, HSP, and UEMR for small polyps, focusing on the depth of the resected specimens.

**Patients and methods** Outpatients with non-pedunculated small polyps (endoscopically diagnosed as 6 to 9 mm), resected by two endoscopists between July 2019 and September 2020, were enrolled. We histologically evaluated the specimens resected via CSP, HSP, and UEMR. The main outcome was the containment rate of the muscularis mucosa (MM) and submucosa (SM) tissues.

**Results** Forty polyps resected via CSP (n = 14), HSP (n = 12), or UEMR (n = 14) were enrolled after excluding 13 polyps with resection depths that were difficult to determine. The rates of specimens containing MM and SM tissue differed significantly (57% and 29% for CSP, 92% and 83% for HSP, and 100% and 100% for UEMR, respectively ( $P=0.005$  for MM and  $P<0.001$  for SM tissue)). Multiple logistic regression analysis showed UEMR was an independent factor relating to the containment of SM tissue. The thickness of SM tissue by CSP, HSP, and UEMR were 52  $\mu\text{m}$ , 623  $\mu\text{m}$ , and 1119  $\mu\text{m}$ , respectively ( $P<0.001$ ). The thickness by CSP was significantly less than those by HSP and UEMR ( $P<0.001$ , Bonferroni correction).

**Conclusions** UEMR could be the best method to contain SM tissue without injection. Further studies are needed to evaluate the indication of UEMR for small polyps.

## Introduction

Colorectal cancer (CRC) is the third most commonly diagnosed cancer, and the second most common cause of cancer-related mortality worldwide [1]. Endoscopic detection and removal of colorectal adenomatous polyps is a standard method of preventing CRC because of its well-established efficacy for decreasing CRC incidence and mortality [2–6].

Most polyps detected via colonoscopy (approximately 70% to 80%) are diminutive ( $\leq 5$  mm) or small (6 to 9 mm) [7, 8]; thus, endoscopic management of these polyps is a major task for endoscopists. Recent western guidelines recommend cold snare polypectomy (CSP) for diminutive and small polyps owing to its high complete resection rate and safety profile [9, 10]. From the perspective of biological behavior, diminutive polyps rarely result in high-grade dysplasia ( $< 1\%$  of cases) [7, 8], thus making them good candidates for CSP; however, 1.0% to 3.3% of small polyps result in high-grade dysplasia [7, 8], which cannot be ignored when considering the optimal resection method. Suzuki et al. [11] reported that the resection depth for CSP was less than that for hot snare polypectomy (HSP), and 76% of CSP specimens contained no submucosal (SM) tissue. Thus, considering the behavior of polyps and the characteristics of the resection method, CSP may cure most small polyps, but resection methods with electrical current may be better for resecting some small polyps exhibiting high-grade dysplasia.

Many studies have assessed the safety and efficacy of underwater endoscopic mucosal resection (UEMR), a technique that is easily available without SM injection and may potentially replace HSP [12–14]. However, the efficacy of UEMR for resecting small polyps, considering their resection depth, remains uncertain. Thus, we retrospectively assessed the efficacy of CSP, HSP, and UEMR for treating small polyps without submucosal injection, focusing on the containment of the SM tissue.

## Patients and methods

### Ethics

This study was conducted in accordance with the Declaration of Helsinki. The Institutional Review Board at Iwakuni Clinical Center approved the study protocol on September 4, 2020. Patients provided informed consent through an opt-out on the center's website.

### Patients and study design

We enrolled consecutive outpatients who underwent colonoscopies performed by two endoscopists, in which at least one or more colorectal polyps were removed. The inclusion criteria were that the polyps were: 1) 6 to 9 mm in size on the endoscopy; 2) protruded or flat with elevated morphology; 3) diagnosed as low-grade adenomas or serrated lesions via magnifying narrow-band imaging (NBI) endoscopy; and 4) removed by CSP, HSP, or UEMR. Low-grade adenomas or serrated lesions are diagnosed endoscopically when magnifying NBI findings showed Japan NBI Expert Team (JNET) classification Type 2A or 1 [15]. The exclusion criteria were that the polyps: 1) had pedunculated or depressed morphology; 2) were suspected to be

cancerous; 3) were characteristic of inflammatory bowel disease or familial adenomatous polyposis; or 4) could not be precisely assessed histologically. Antithrombotic drugs were either continued or stopped as per the Japanese guidelines for endoscopy with antithrombotic drugs [16, 17]. The characteristics of each polyp, such as size, location, morphology, and endoscopic findings according to the JNET classification, were prospectively recorded in the database, and the eligible polyps were retrospectively extracted from the database and histologically assessed for the resection depth.

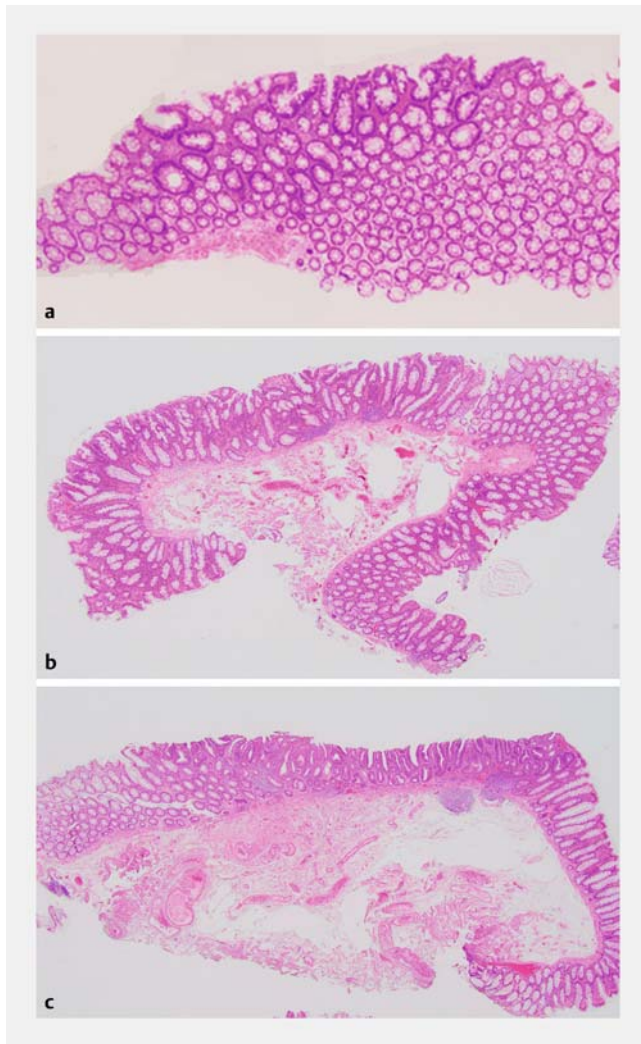
### Endoscopic resection (CSP, HSP, and UEMR)

All patients received standardized instructions for bowel preparation. We used the same high-definition video colonoscope model (Olympus PCF-H290Z1; Olympus Co. Tokyo, Japan) and a round snare (10-mm Snare Master Plus, Olympus, Tokyo, Japan) for the CSP, HSP and UEMR. Endoscopic resection was initiated by inspecting the mucosa during the withdrawal period. Once a target polyp was identified, we carefully recorded its characteristics. After the snare completely opened, the polyp was then captured. For CSP, polyps were resected without electrocautery. For HSP, polyps were resected with an electrosurgical generator (forced coagulation effect 2 40W; VIO300D ERBE 5; Tubingen, Germany) with a short current. For UEMR [12], the colorectal lumen was deflated, then the lumen was filled with normal saline using the water jet function. Finally, the polyps were resected with a short current (effect 40W). All resection techniques were performed without SM injection. After resection, the mucosal defect was washed with the water jet function, and the marginal mucosa was carefully observed using NBI. If remnant colorectal polyps were suspected or present, residual lesions were resected using the same technique. For HSP and UEMR, the mucosal defect was closed with clips to prevent hemostasis. Polyps were suctioned and retrieved for histologic assessment. The resection technique was chosen according to the endoscopists' preference.

### Histological assessment

All collected specimens were fixed in 10% formalin without stretching and sectioned at 2-mm intervals. An expert gastrointestinal pathologist evaluated the specimens according to the Vienna classification (adenomatous or serrated lesion and the lesional margin) [18]. The two endoscopists, with the help of an expert pathologist, then evaluated whether the specimens were appropriate or inappropriate for assessing and calculating the resection depth (► Fig. 1). "Appropriate" specimens were defined as those not destroyed by the retrieval process or inadequate sectioning.

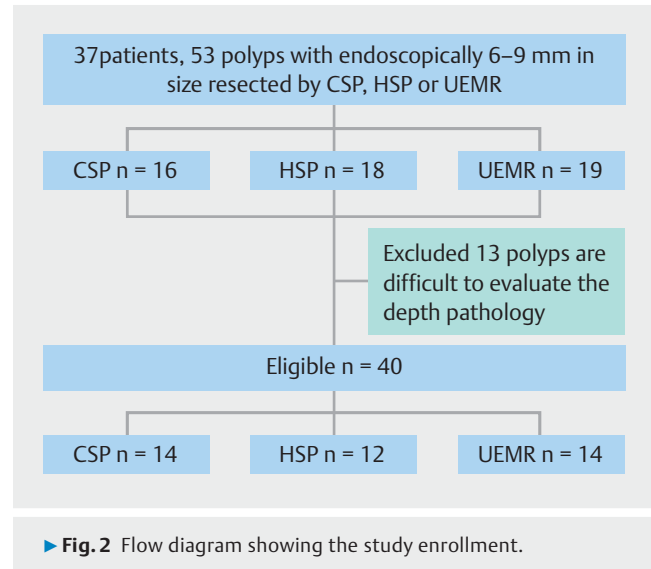
The endoscopists and pathologist (who was blinded to the resection method) evaluated and discussed whether the specimens contained MM and SM tissues, and measured the thickness from the muscularis mucosa (MM) to the vertical resection margin of SM tissue at the center of the resected specimens.



► **Fig. 1** Histopathological specimens taken during CSP, HSP, and UEMR. **a** Specimen resected during CSP containing only muscularis mucosa. **b** Specimen resected during HSP containing muscularis mucosa and SM tissue. **c** Specimen resected during UEMR containing muscularis mucosa and SM tissue.

## Outcome variables

The primary outcome in this study was the rates that MM and SM tissues were contained in the resection. The secondary outcomes were thickness of SM tissue achieved via CSP, HSP, and UEMR, en bloc resection rates, endoscopic and histologic complete resection rates, adverse event (e.g., bleeding, perforation) rates, and the factors relating the containment of MM and SM tissues. En bloc resection was defined as removal of the whole lesion in one piece. Endoscopic complete resection was defined as absence of residual tumor as per endoscopic observation. Histologic complete resection was defined as clear confirmation of normal tissue in the resection margin as per pathological assessment.



## Statistics

Results are presented as the median (range) for continuous variables. Fisher's exact tests were used to compare categorical data; Kruskal-Wallis and Mann-Whitney U tests were used to compare continuous data where appropriate. Multiple logistic regression analysis was used to evaluate the variable factors relating the containment rate of the MM and SM tissues. Because of quasi-complete separation, odds ratios were calculated using a penalized maximum likelihood logistic regression [19] using Stata user-driven command firthlogit. Multiple linear regression analysis was also performed evaluating the relation between thickness of SM tissue and variables.  $P < 0.05$  was considered statistically significant for comparisons between three groups.  $P < 0.05$  was considered statistically significant for comparisons between two groups if  $P < 0.05$  was shown among three groups. The analyses were performed using Stata 17 software (StataCorp LLC, College Station, Texas, United States) and JMP 15 software (SAS Institute, Cary, North Carolina, United States).

## Results

### Participant flow and baseline characteristics

Between July 2019 and September 2020, a total of 87 outpatients with small polyps underwent resection by two endoscopists. Of these, pedunculated polyps, patients with familial adenomatous polyposis or inflammation bowel disease, on whom EMR had been performed, and with insufficient information about lesion characteristics were excluded. Thus, 37 patients with 53 polyps resected via CSP, HSP, or UEMR were evaluated for histology. Thirteen polyps were excluded because they were evaluated as inappropriate for pathologically assessing the depth. Finally, 40 polyps were included in this study. Among these, 14 polyps were resected via CSP, 12 via HSP, and 14 via UEMR (► **Fig. 2**).

► **Table 1** shows baseline characteristic of the patients and lesions. The three groups did not differ significantly in mor-

► **Table 1** Baseline characteristics of the three groups.

	CSP (n = 14)	HSP (n = 12)	UEMR (n = 14)	P value
Age, yr, (range)	73 (46–78)	77 (71–80)	74 (44–87)	0.06
Male/female, n	12/2	6/6	10/4	0.13
Median lesion size, (range) <sup>1</sup>	6 (6–9)	7.5 (6–10)	8 (6–10)	0.02
Morphology, n (%)				
▪ 0-IIa	5 (36)	5 (42)	6 (43)	0.50
▪ 0-Is	9 (64)	7 (58)	8 (57)	
Location, n (%)				
▪ Right	11 (79)	6 (50)	10 (71)	0.28
▪ Left/rectum	3 (21)	6 (50)	4 (29)	
JNET classification				
▪ Type 1	13 (93)	10 (83)	12 (86)	0.72
▪ Type 2A	1 (7)	2 (17)	2 (14)	
Histology, n (%)				
▪ Low-grade adenoma	13 (93)	10 (83)	12 (86)	0.72
▪ Serrated polyp	1 (7)	2 (17)	2 (14)	

CSP, cold snare polypectomy; HSP, hot snare polypectomy; UEMR, underwater endoscopic mucosal resection; JNET classification, Japan NBI Expert Team classification.

<sup>1</sup> Median lesion size showed the histological size after resection.

phology or location. Lesion sizes significantly differed among the three groups ( $P=0.02$ , Kruskal-Wallis test). Lesion size for CSP tended to be smaller than that for HSP ( $P=0.12$ , Mann-Whitney U test) and was significantly smaller than that for UEMR ( $P=0.008$ , Mann-Whitney U test, Bonferroni correction). Thirty-five polyps (83%) were histologically diagnosed as adenomas.

### Treatment results

► **Table 2** shows treatment results. En bloc resection and endoscopic complete resection rates were 100% in all groups. Histologic complete resection rates significantly differed among the three groups ( $P=0.03$ , Fisher's exact test,). The histological complete resection rate tended to be higher for UEMR than for CSP, but not significantly different ( $P=0.04$ , Fisher's exact test, Bonferroni correction).

### Main outcomes

Rates of specimens containing MM and SM tissue differed significantly (57% and 29% for CSP, 92% and 83% for HSP, and 100% and 100% for UEMR, respectively;  $P=0.005$  for MM;  $P\leq 0.001$  for SM, Fisher's exact test). The rate of CSP specimens containing SM tissue was significantly lower than that of UEMR specimens ( $P=0.002$ , Fisher's exact test, Bonferroni correction). The mean thicknesses of SM tissue differed significantly among CSP (52  $\mu\text{m}$ ), HSP (623  $\mu\text{m}$ ), and UEMR (1119  $\mu\text{m}$ ;  $P\leq 0.001$ , Kruskal-Wallis). The thickness of SM tissue resected by

CSP was significantly less than that by HSP and UEMR (both  $P< 0.001$ , Mann-Whitney U test, Bonferroni correction), and the thickness by HSP tended to be less than that by UEMR, but not significantly different ( $P=0.04$ , Mann-Whitney U test, Bonferroni correction; ► **Fig. 3**).

### Factors relating to containment of MM and SM tissues

► **Table 3** shows single and multiple logistic regression analyses of the containment rate of MM and SM tissues. UEMR was a significant factor relating to containment of SM tissue ( $P=0.02$ ). UEMR tended to be a factor relating the containment of MM tissue, but not significant.

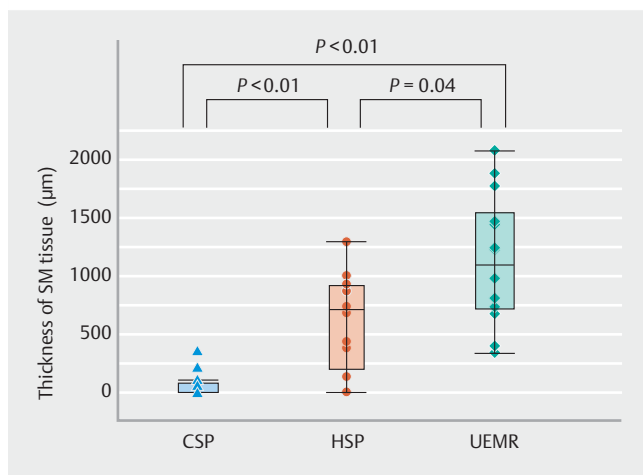
### Multiple linear regression and subgroup analysis regarding the thickness of SM tissue

**Supplementary Table 1** shows the single and multiple regression analyses regarding the thickness of SM tissue. The right-sided colon (cecum and ascending and transverse colon) and CSP were the significant independent factors for a shallower resection depth. Conversely, UEMR was significantly correlated with a deeper resection depth. **Supplementary Fig. 1** shows the thickness of SM tissue considering morphological classification. For UEMR, the thickness tended to be larger, but not significantly, for polyps classified as 0-Is than for those classified as 0-IIa ( $P=0.09$ , Mann-Whitney U test).

► **Table 2** Treatment outcomes of the three groups

	CSP (n = 14)	HSP (n = 12)	UEMR (n = 14)	P value
En bloc resection, n (%)	14 (100)	12 (100)	14 (100)	1.0
Complete resection, n (%)				
▪ Histologic complete resection	9 (64)	10 (83)	14 (100)	0.03
▪ Endoscopic complete resection	14 (100)	12 (100)	14 (100)	1
▪ Containing MM tissue (%)	8 (57)	11 (92)	14 (100)	0.005
▪ Containing SM tissue (%)	4 (29)	10 (83)	14 (100)	<0.001
Thickness of SM tissue, $\mu\text{m}$				<0.001
▪ Mean $\pm$ SD	52 $\pm$ 105	623 $\pm$ 434	1119 $\pm$ 484	
▪ Median (range)	0 (0–353)	706 (0–1287)	1211 (338–1876)	
Adverse events, n				
▪ Perforation	0	0	0	1.0
▪ Delayed bleeding	0	0	0	1.0

CSP, cold snare polypectomy; HSP, hot snare polypectomy; UEMR, underwater endoscopic mucosal resection; MM, muscularis mucosa; SM, submucosa.



► **Fig. 3** Thickness of SM tissue among three groups. The order of the resection depth thickness was CSP < HSP < UEMR.

## Discussion

In this study, we compared containment rates of MM and SM tissues and the thickness of SM tissue for small colorectal polyps resected by CSP, HSP, and UEMR. The rate of CSP specimens containing SM tissue was significantly lower than that of UEMR specimens. The order of resection depth was CSP < HSP < UEMR, and all lesions resected via UEMR contained SM tissue. The pathological complete resection rate tended to be higher for UEMR than for CSP and HSP.

All techniques performed in this study are easily available without SM injection and cost-effective because they require only a polypectomy snare as a resection device. Of the three, CSP is the simplest and safest because it requires no electrical

current or water immersion. Previous reports have shown the efficacy of CSP for completely removing polyps, especially low-grade adenomas [20–22], and a randomized controlled trial demonstrated the non-inferiority of CSP relative to HSP [23]. Similar to previous reports [11, 24], the thickness of SM tissue for CSP in this study was less than those for HSP and UEMR. Further, most CSP-resected specimens contained no submucosa, suggesting that CSP is unsuited for resecting high-grade or higher dysplasia in which tumor-free vertical-margin resection is desirable.

HSP is a conventional technique that requires an electrical current. The rate of HSP specimens containing SM tissue was significantly higher than that of CSP specimens; however, similar to a previous report, approximately 20% of the resected specimens contained no submucosa [11]. During HSP, insufflation increases the luminal extension force and stretches the lesion with the surrounding mucosa, making it difficult to snare at the proper depth and sometimes inducing the snare to slip off the lesion. Further, attempting to use excess deflation or applying too much pressure to hold the snare to prevent it from slipping may cause deeper resection with perforation. Thus, during HSP, capturing the lesion with sufficient submucosa can be difficult.

UEMR has recently gained attention for its efficacy [12–14, 25, 26]. HSP and UEMR differ only in whether the lumen is submerged; however, in this study, the thickness of SM tissue by UEMR tended to be larger than that by HSP, and all UEMR specimens contained the submucosa with histologically complete resections, suggesting that UEMR may be a better technique for lesions needed to be resected with tumor-free vertical-margin such as high-grade dysplasia. When the lesions do not show typical JNET Type 1 or 2A, and the endoscopists have low confidence regarding the diagnosis of JNET, UEMR would be prefer-

► **Table 3** Single and multiple regression analyses for the containment rate of the MM and SM tissues.

	MM tissue						SM tissue					
	Univariate			Multivariate			Univariate			Multivariate		
	Odds ratio	95% CI	P value	Odds ratio	95% CI	P value	Odds ratio	95% CI	P value	Odds ratio	95% CI	P value
Morphology												
▪ 0-IIa	1			1			1			1		
▪ 0-Is	0.92	0.19–4.37	0.92	1.04	0.19–5.64	0.95	0.84	0.22–3.15	0.79	0.9	0.16–5.06	0.9
Lesion size												
▪ 6–7 mm	1			1			1			1		
▪ 8–10 mm	2.33	0.45–12.0	0.31	1.11	0.18–6.64	0.9	3.58	0.85–14.9	0.08	1.85	0.29–11.8	0.51
Lesion location												
▪ Right	1			1			1			1		
▪ Left/rectum	2.51	0.37–16.9	0.34	1.63	0.22–11.9	0.62	5.8	0.91–37.0	0.06	5.14	0.56–1.67	0.14
Procedure												
▪ CSP	1			1			1			1		
▪ HSP	4.78	0.66–34.7	0.12	3.8	0.55–25.8	0.17	7.3	1.28–41.0	0.02	5.64	0.94–33.6	0.05
▪ UEMR	19.8	0.99–394	0.05	13.5	0.69–265	0.08	55.3	2.75–1114	0.009	33.5	1.71–656	0.02

MM, muscularis mucosa; SM, submucosa; CSP, cold snare polypectomy; HSP, hot snare polypectomy; UEMR, underwater endoscopic mucosal resection.

able. Theoretically, water immersion during UEMR decreases the luminal extension force, increases the mucosal and submucosal buoyancy, and causes the lesion with the surrounding mucosa to float upward into the lumen, enabling easy snaring at the proper submucosal depth. In addition, during UEMR, the muscularis propria remains circular behind the submucosa, thus preventing perforation, even if the resected specimen contains thick submucosa.

Although multiple logistic regression analysis regarding containment of SM tissue showed the procedure (CSP, HSP or UEMR) was an independent factor solely, multiple regression analysis regarding the resection depth showed that the right-sided colon was also an independent factor for a shallower resection depth. Why lesions located on the right-sided colon were resected at shallower depths is unknown. However, the wall of the right-sided colon is thought to be thinner than that of the left side [27], which might lead to shallower resection depths on the right side.

Although none of the patients experienced exhibited adverse events, the mucosal defects were closed with clips after HSP and UEMR; thus, evaluating the safety of each procedure was difficult. Previous reports have shown that CSP may be safer than HSP because CSP does not cause electricity-induced tissue damage [28, 29]. Further studies are warranted to evaluate the safety of each procedure, including UEMR.

This study had some limitations. First, this was a single-center retrospective pilot study with a small sample size. Lesion size was different for each technique because it was chosen according to the endoscopists' preference. However, lesion size was not a significant factor related to containment of MM and SM tissues. We have provided real-world data regarding resection depth of each procedure. Second, consecutive patients who were medically examined by two expert endoscopists were recruited into this study because these endoscopists were the only two to use UEMR. A prospectively recorded database was used to reduce the drop-off in eligible polyps; however, there were some excluded cases. Prospective study is warranted in the future. Third, all polyps were not stretched when they were fixed in formalin, thus some polyps that were not cut vertically, resulting in difficulty of pathological assessment, were excluded. This may have led to selection bias. However, because specimens resected by each procedure were evaluated under identical conditions, the influence of bias on the primary endpoint may be small. Fourth, we excluded endoscopic mucosal resection, which requires submucosal injection, because we evaluated the real submucosal depth of the resected specimens only for techniques that do not require submucosal injection [30].

## Conclusions

In conclusion, we showed the containment rate of MM/SM tissue and the thickness of SM tissue of small colorectal polyps resected by CSP, HSP and UEMR using a unified, single polypectomy snare. UEMR was a significant factor containing SM tissue. UEMR may be the best available resection method for containing SM without injection. Further studies are needed to evaluate the indication of UEMR for small polyps.

## Competing interests

Author Y.Y. received honoraria from Olympus, Cor., and FUJIFILM Cor. Author H.O. received honoraria from Otsuka Pharmaceutical Co., Ltd., Takeda Pharmaceutical Co. Ltd., AstraZeneca K.K., Daiichi Sankyo Co., Ltd., Nippon Kayaku Co., Ltd., EA Pharma Co., Ltd., Eisai Co., Ltd., Otsuka Pharmaceutical Factory, Inc., Viartis Inc., Olympus, Cor., FUJIFILM Cor., Miyarisan Pharmaceutical Co., Ltd, Mylan EPD G.K., Chugai Pharmaceutical Co., Ltd., Novartis Pharma K.K., Taiho Pharmaceutical Co., Ltd., and Bayer Yakuhin, Ltd.

## References

- Bray F, Ferlay J, Soerjomataram I et al. Global cancer statistics 2018: GLOBOCAN estimates of incidence and mortality worldwide for 36 cancers in 185 countries. *CA Cancer J Clin* 2018; 68: 394–424
- Winawer SJ, Zauber AG, Ho MN et al. Prevention of colorectal cancer by colonoscopic polypectomy. The National Polyp Study Workgroup. *N Engl J Med* 1993; 329: 1977–1981
- Zauber AG, Winawer SJ, O'Brien MJ et al. Colonoscopic polypectomy and long-term prevention of colorectal-cancer deaths. *N Engl J Med* 2012; 366: 687–696
- Cottet V, Jooste V, Fournel I et al. Long-term risk of colorectal cancer after adenoma removal: a population based cohort study. *Gut* 2012; 61: 1180–1186
- Nishihara R, Wu K, Lochhead P et al. Long-term colorectal-cancer incidence and mortality after lower endoscopy. *N Engl J Med* 2013; 369: 1095–1105
- Løberg M, Kalager M, Holme Ø et al. Long-term colorectal-cancer mortality after adenoma removal. *N Engl J Med* 2014; 371: 799–807
- Lieberman D, Moravec M, Holub J et al. Polyp size and advanced histology in patients undergoing colonoscopy screening: implications for CT colonography. *Gastroenterology* 2008; 135: 1100–1105
- Sakamoto T, Matsuda T, Nakajima T et al. Clinicopathological features of colorectal polyps: evaluation of the 'predict, resect and discard' strategies. *Colorectal Dis* 2013; 15: E295–E300
- Ferlitsch M, Moss A, Hassan C et al. Colorectal polypectomy and endoscopic mucosal resection (EMR): European Society of Gastrointestinal Endoscopy (ESGE) Clinical Guideline. *Endoscopy* 2017; 49: 270–297
- Kaltenbach T, Anderson JC, Burke CA et al. Endoscopic removal of colorectal lesions—recommendations by the US multi-society task force on colorectal cancer. *Gastroenterology* 2020; 158: 1095–1129
- Suzuki S, Gotoda T, Kusano C et al. Width and depth of resection for small colorectal polyps: hot versus cold snare polypectomy. *Gastrointest Endosc* 2018; 87: 1095–1103
- Binmoeller KF, Weilert F, Shah J et al. "Underwater" EMR without submucosal injection for large sessile colorectal polyps (with video). *Gastrointest Endosc* 2012; 75: 1086–1091
- Yamasaki Y, Harada K, Yamamoto S et al. Blue laser imaging and linked color imaging improve the color difference value and visibility of colorectal polyps in underwater conditions. *Dig Endosc* 2020; 32: 791–800
- Yamashina T, Uedo N, Akasaka T et al. Comparison of underwater vs conventional endoscopic mucosal resection of intermediate-size colorectal polyps. *Gastroenterology* 2019; 157: 451–461
- Sano Y, Tanaka S, Kudo S et al. Narrow-band imaging (NBI) magnifying endoscopic classification of colorectal tumors proposed by the Japan NBI Expert Team. *Dig Endosc* 2016; 28: 526–533
- Fujimoto K, Fujishiro M, Kato M et al. Guidelines for gastroenterological endoscopy in patients undergoing antithrombotic treatment. *Dig Endosc* 2014; 26: 1–14
- Kato M, Uedo N, Hokimoto S et al. Guidelines for gastroenterological endoscopy in patients undergoing antithrombotic treatment: 2017 appendix on anticoagulants including direct oral anticoagulants. *Dig Endosc* 2018; 30: 433–440
- Bosman FT, Carneiro F, Hruban RH et al. WHO classification of tumours of the digestive system. 4th ed. Lyon, France: International Agency for Research on Cancer (IARC); 2010
- Firth D. Bias reduction of maximum likelihood estimates. *Biometrika* 1993; 80: 27–38
- Schett B, Wallner J, Weingart V et al. Efficacy and safety of cold snare resection in preventive screening colonoscopy. *Endosc Int Open* 2017; 5: E580–E586
- Fujiya M, Sato H, Ueno N et al. Efficacy and adverse events of cold vs hot polypectomy: a meta-analysis. *World J Gastroenterol* 2016; 22: 5436–5444
- Matsuura N, Takeuchi Y, Yamashina T et al. Incomplete resection rate of cold snare polypectomy: a prospective single-arm observational study. *Endoscopy* 2017; 49: 251–257
- Kawamura T, Takeuchi Y, Asai S et al. A comparison of the resection rate for cold and hot snare polypectomy for 4–9 mm colorectal polyps: a multicentre randomised controlled trial (CRESCENT study). *Gut* 2018; 67: 1950–1957
- Ito A, Suga T, Ota H et al. Resection depth and layer of cold snare polypectomy versus endoscopic mucosal resection. *J Gastroenterol* 2018; 53: 1171–1178
- Zhang Z, Xia Y, Cui H et al. Underwater versus conventional endoscopic mucosal resection for small size non-pedunculated colorectal polyps: a randomized controlled trial (UEMR vs. CEMR for small size non-pedunculated colorectal polyps). *BMC Gastroenterology* 2020; 20: 311
- Choi AY, Moosvi Z, Shah S et al. Underwater versus conventional EMR for colorectal polyps: systematic review and meta-analysis. *Gastrointest Endosc* 2021; 93: 378–389
- Choo WK, Subhani J. Complication rates of colonic polypectomy in relation to polyp characteristics and techniques: a district hospital experience. *J Interv Gastroenterol* 2012; 2: 8–11
- Repici A, Hassan C, Vitetta E et al. Safety of cold polypectomy for <10 mm polyps at colonoscopy: a prospective multicenter study. *Endoscopy* 2012; 44: 27–31
- Yamashina T, Fukuhara M, Maruo T et al. Cold snare polypectomy reduced delayed postpolypectomy bleeding compared with conventional hot polypectomy: a propensity score-matching analysis. *Endosc Int Open* 2017; 5: E587–E594
- Matsushita M, Nishio A, Okazaki K et al. Meaningless comparison of resection depth between cold snare polypectomy and endoscopic mucosal resection. *J Gastroenterol* 2019; 54: 471–472