

Modified line-assisted complete closure of the defect after gastric endoscopic full-thickness resection: a pilot study in porcine models




Authors

Yasushi Yamasaki, Masayasu Ohmori, Junki Toyosawa, Soichiro Ako, Hiroyuki Okada

Institution

Department of Gastroenterology, Okayama University Hospital, Okayama, Japan

submitted 14.10.2021

accepted after revision 26.11.2021

Bibliography

Endosc Int Open 2022; 10: E609–E615

DOI 10.1055/a-1785-8589

ISSN 2364-3722

© 2022. The Author(s).

This is an open access article published by Thieme under the terms of the Creative Commons Attribution-NonDerivative-NonCommercial License, permitting copying and reproduction so long as the original work is given appropriate credit. Contents may not be used for commercial purposes, or adapted, remixed, transformed or built upon. (<https://creativecommons.org/licenses/by-nc-nd/4.0/>)

Georg Thieme Verlag KG, Rüdigerstraße 14,
70469 Stuttgart, Germany

Corresponding author

Yasushi Yamasaki, Department of Gastroenterology, Okayama University Hospital, 2-5-1 Shikata-cho, Kita-ku, Okayama 700-8558, Japan

Fax: +81-86-225-5991

yashshifive@yahoo.co.jp

ABSTRACT

Background and study aims Closure after endoscopic full-thickness resection (EFTR) is challenging. We previously developed a simple endoscopic closure method: line-assisted complete closure (LACC). We performed a pilot study using porcine models to evaluate the feasibility of modified LACC after gastric EFTR.

Patients and methods Six live pigs were included. EFTR (greater curvature of the gastric antrum [n = 3] and anterior wall of the gastric body [n = 3]) was performed under general anesthesia and the defect after EFTR was closed by modified LACC. The pigs were observed until postoperative day 4 (Day 4). The closure site was endoscopically evaluated and the presence or absence of peritonitis and fluid leakage was evaluated. The outcomes were the success rate of modified LACC on the day of the procedure, maintenance of defect closure, presence of peritonitis or leakage, and clinical course.

Results Once complete closure was successfully achieved in all cases, maintenance of closure on Day 4 was not achieved. However, there was neither peritonitis nor fluid leakage. The defect was completely covered by surrounding tissues on Day 4 and the clinical course was good in all cases.

Conclusions The feasibility of modified LACC after gastric EFTR was demonstrated in porcine models. Further improvement is needed to maintain defect closure.

Introduction

Endoscopic full-thickness resection (EFTR) has recently been used for epithelial and subepithelial gastrointestinal lesions [1, 2]. Several reports have been published on use of EFTR in which most lesions measured <3 cm, particularly subepithelial lesions such as gastrointestinal stromal tumors (GISTs), but surgery is the standard for GISTs [3, 4]. To date, in Japan, use of EFTR has been limited to gastric subepithelial lesions <3 cm as an advanced medical treatment, given the feasibility of oral retrieval and security of defect closure using applicable closure devices.

Several endoscopic closure devices and techniques have been developed, such as over-the-scope clip (OTSC) [2, 5, 6], purse-string suturing using endoloop and clips [1, 7, 8], hand suturing [9–11], O-ring and OTSC [12], and OverStitch [13], but these are complicated and require use of specific devices. For widespread use of EFTR, application of easily available and daily-use devices for closure is ideal. We developed a simple closure technique involving only clips and suture line, called line-assisted complete closure (LACC) [14], which can be used to treat mucosal defects after endoscopic submucosal dissection (ESD), and showed high rates of success and efficacy with it [15].

Thus, we conducted a pilot study using porcine models to evaluate the feasibility of modified LACC for defects <3 cm after gastric EFTR as a first step.

Patients and methods

Study approval

This study was conducted after approval from the Animal Care and Use Committee, Okayama University (institutional number: OKU-2020730).

Animal experiment

Six live, three-way crossbred, 3-month-old female pigs were included in this study. After environmental acclimation for 7 days, the pigs were fasted for 24 h before the endoscopic procedures. On the day of the procedure (Day 0), 0.04 mg/kg medetomidine, 0.2 mg/kg midazolam and 5 mg/kg ketamine were injected intramuscularly, followed by tracheal intubation and continuous inhalation anesthesia using 2% to 5% isoflurane. EFTR and modified LACC as described below, were performed at the greater curvature of the gastric antrum in three pigs, and at the anterior wall of the lower gastric body in the other three pigs. The procedures for the greater curvature of the gastric antrum were performed in forward view, and those for the anterior wall of the lower gastric body were performed in retroflex view. After the procedures, the pigs were allowed to drink water and were fed with a regular diet 1 day after the procedure (Day 1). For 3 days including Day 0, an antibiotic (enrofloxacin 2.5 mg/kg) was injected intramuscularly.

Until postoperative day 4 (Day 4), the pigs were observed carefully, and their eating habits, body weight, and general conditions were documented. Blood samples were collected on Days 0 and 4. Under general anesthesia, closure sites were endoscopically observed on Day 4, and 50 mL 1% methylene blue was poured into the closure sites to evaluate leakage. A midline abdominal incision was performed, and the presence or absence of peritonitis and leakage of fluid with methylene blue was evaluated visually. The peritoneal side of the closure sites was also evaluated. All pigs were euthanized using a lethal dose of potassium chloride.

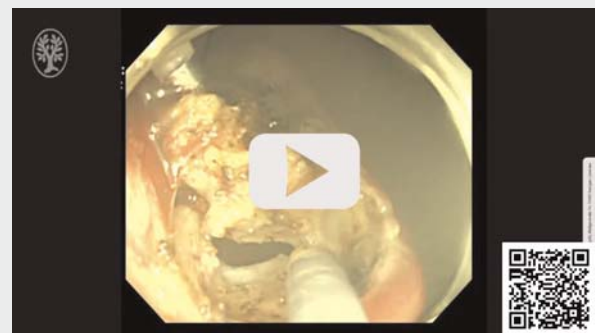Modified LACC for defects after EFTR

The modified LACC and EFTR procedures were performed by three endoscopists who had experience with more than 100 gastrointestinal ESDs. A single-channel endoscope (PCF-Q240ZI; Olympus Tokyo, Japan) and CO₂ insufflation were used, and the endoscope was inserted into the stomach (▶ **Video 1**). After irrigation of the stomach using physiological saline, a circular marking (~3×3 cm) was created using a triangle tip electrosurgical knife (TT knife; Olympus) and submucosal injection of saline was performed. ESD using the TT knife just outside the marking was performed to create a mucosal defect and expose the muscle layer. After endoscope withdrawal, a clip-and-line was applied. The endoscope was reinserted and the center of the exposed muscle layer was captured using a clip-and-line to achieve traction. A muscle layer (~2×2 cm) inside the defect was removed using the TT knife and EFTR was

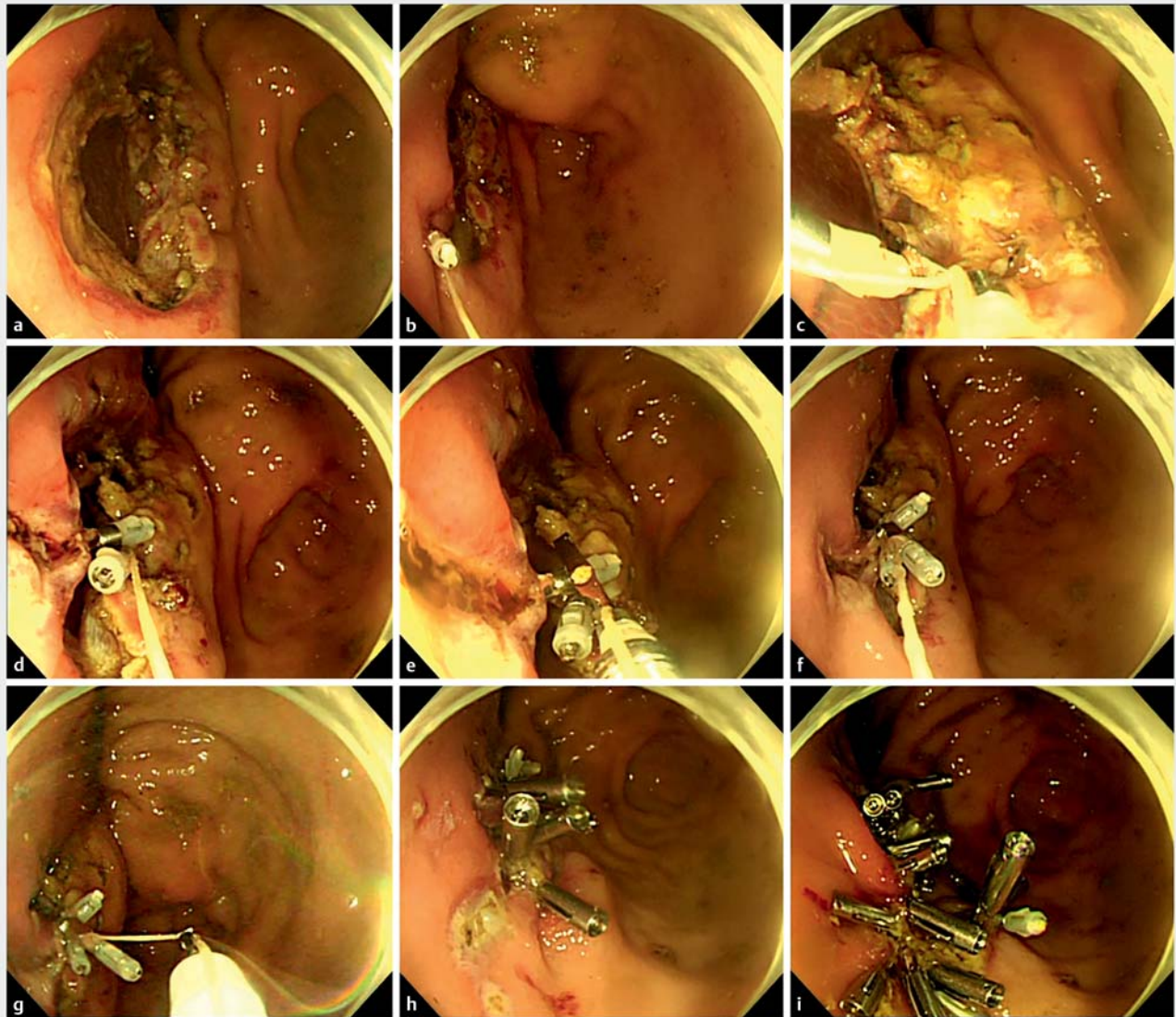
achieved. When excess free air affected the circulation dynamics during EFTR, peritoneal aspiration using a 20-gauge needle was performed.

After completion of EFTR, modified LACC was performed as described below (▶ **Fig. 1**, ▶ **Fig. 2** and ▶ **Video 1**) [14, 15]. Multiple small incisions just outside the defect (precutting method [16]) were made circumferentially using the TT knife as preparation for LACC. Precutting was performed four on each side (in total eight precutting). A 3–0 silk line (Akiyama-Seisakusho Co. Ltd., Tokyo, Japan) was tied to a clip (HX-610–090, EZ clip; Olympus) mounted on an applicator (HX-110LR; Olympus), and the clip was retracted into the applicator and inserted into the accessory channel. The clip tied a line was fully opened, and one side of the claw of the clip was inserted into the incision on the oral side, while the other side of the claw was placed inside the margin of the defect (at the exposed muscle layer), and the claws were closed. Another clip (without a line) was used to anchor the line to the opposite side. One side of the claw of another clip was inserted into the anal-side incision, while the other side of the claw was placed inside the margin (at the exposed muscle layer), and the claws were closed. Finally, both clips were gathered together by gently pulling the line by hand. At this stage, both mucosa and muscle layer were gathered as much as possible. A third clip was inserted while threading a line through the gap at the base of the clip teeth, and the clip was fully opened near the first and second clips, resulting in the line and clips being fixed (locking technique) [17]. The third clip was closed to catch the mucosa. The TT knife was inserted, and the line was cut by forced coagulation mode. The modified LACC procedure using regular clips (EZ clip) was repeated to minimize the defects, and reopenable clips (Sure Clip; MC Medical, Tokyo, Japan) were added to close the defect completely. The modified LACC was a combination of the original LACC and, precutting and locking technique.

▶ VIDEO



▶ **Video 1** Endoscopic full-thickness resection (EFTR) and line-assisted complete closure (LACC) of the defect. First, endoscopic submucosal dissection about 3 cm in size was performed. Second, EFTR 2 cm in size was performed using the traction technique. Third, the precutting method was used. Fourth, LACC was applied to minimize the defect. Fifth, a simple clip was added to achieve complete closure.



► **Fig. 1** Modified line-assisted complete closure (LACC) of the defect after endoscopic full-thickness resection (EFTR). **a** The defect after EFTR. **b** The clip-and-line was applied to catch the mucosa of the oral side. **c** Another clip was used to anchor the line to the opposite side. **d** Both clips were gathered together. **e** The third clip fixed the line. **f** The third clip was closed to catch the mucosa. **g** The line was cut by triangle tip knife. **h** LACC procedure was repeated to minimize the defects. **i** Complete closure was achieved.

Measurement outcomes

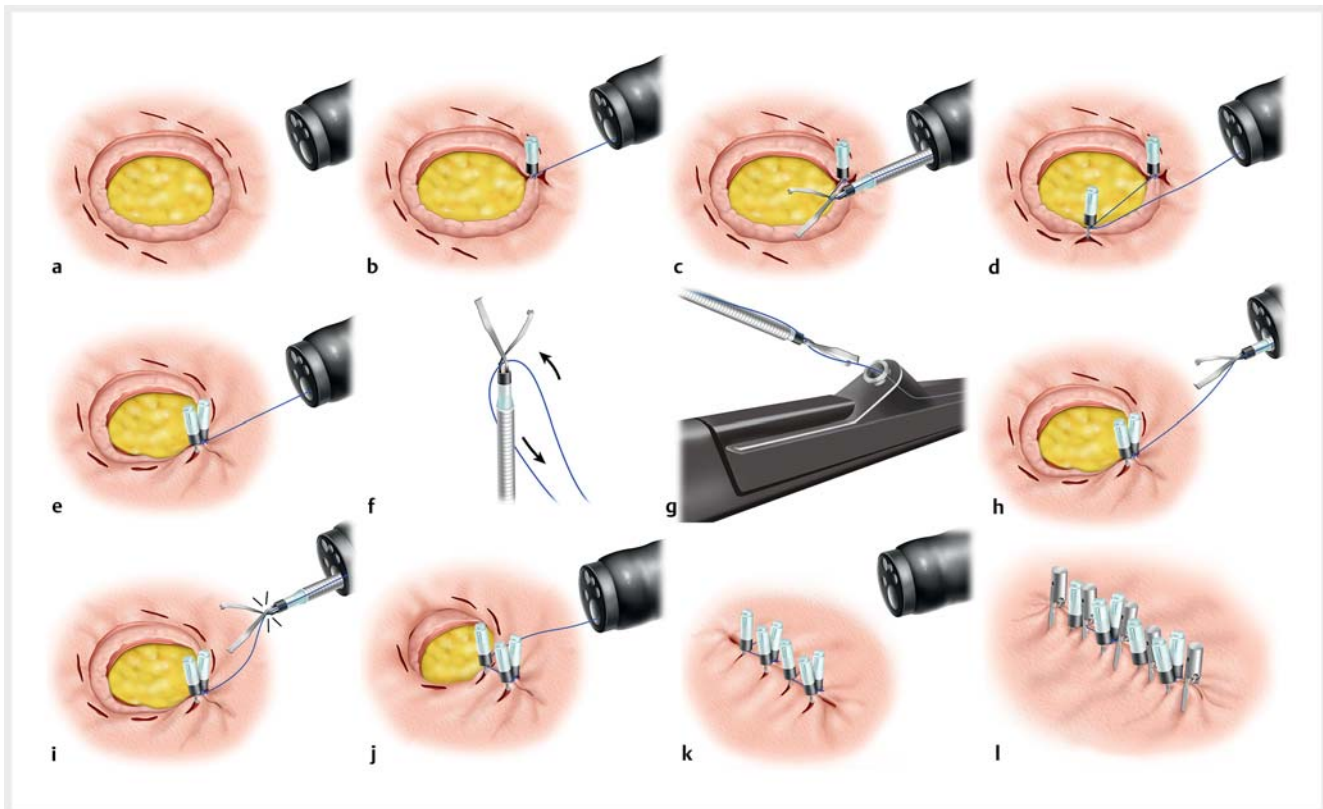
The evaluated outcomes were the success rate of modified LACC, which was defined as complete closure (whole defect was covered by the mucosa) on Day 0, closure procedure time, modified LACC times, maintenance of defect closure on Day 4, presence of peritonitis or leakage on Day 4, change of laboratory test, and clinical course. Clinical course was evaluated on the basis of the weight-loss process and dietary intake.

Results

► **Table 1** shows the location and defect size based on resected specimens and the outcomes of modified LACC. Successful modified LACC of the defect after EFTR was achieved in all six

cases. Median closure procedure time was 43.5 minutes (range 37 to 65). Median number of LACC were 3 times (range 3 to 4 times), and median total number of clips, which included the clip used for modified LACC, was 24.5 (range 20 to 28).

Maintenance of defect closure on Day 4 was not achieved in all cases. Partial dehiscence was observed in three cases at the greater curvature of the gastric antrum and complete dehiscence was observed in the other three cases at the anterior wall of the lower gastric body. However, there was neither peritonitis nor fluid leakage in any case. In the gastric antrum, the defects were covered by greater omentum, and in the gastric body, the defects were covered by adhesion by surrounding tissues including the liver (► **Fig. 3**). All pigs ate well on Day 1 (700 g/day swine diet; Oriental Yeast Co. Ltd. Tokyo.) and body



► **Fig. 2** Schema of modified LACC. **a** Multiple small incisions (basically eight incisions) just outside the defect were made circumferentially. **b** A clip tied a line was applied. One side of the claw was inserted into the incision, while the other side of the claw was placed at the exposed muscle layer, and the claws were closed. **c, d** Another clip was used to anchor the line. One side of the claw was inserted into the anal-side incision, while the other side of the claw was placed at the exposed muscle layer, and the claws were closed. **e** By pulling the line, both clips were gathered. **f, g** A third clip was inserted from the accessory channel while threading a line through the gap of the base of the clip teeth. **h, i** The clip was fully opened, resulting in the line and clips being fixed. **j** The clip was closed to catch the mucosa, and the line was cut by TT knife. **k** The modified LACC procedure was repeated to minimize the defects. **l** Reopenable clips were added to close the defect completely.

weight increased on Day 4. The clinical course progressed well with no delayed adverse events (AEs) (► **Table 2**).

Discussion

Our study using porcine models showed that modified LACC for defect closure after gastric EFTR was feasible without any AEs, but the closure was only partial or entirely dehiscent on Day 4. The clinical course was good in all cases due to the defect being rapidly covered by adhesion from the peritoneal side, but permanent closure was theoretically ideal. Thus, some improvements in LACC are needed to achieve more secure closure after EFTR.

To date, LACC has mainly been used for mucosal defect closure after ESD, although there are several reports of successful application of LACC for large iatrogenic perforations during endoscopic treatment [18, 19]. In this study, we first evaluated the feasibility of modified LACC for defect closure after EFTR. The defect after EFTR was completely closed in all cases on Day 0, but closure was not maintained. There may be several reasons for closure dehiscence. First, the gastric mucosa is thick and has few folds compared with other organs, which exert tension, resulting in disruption of the closure site. Second, dietary

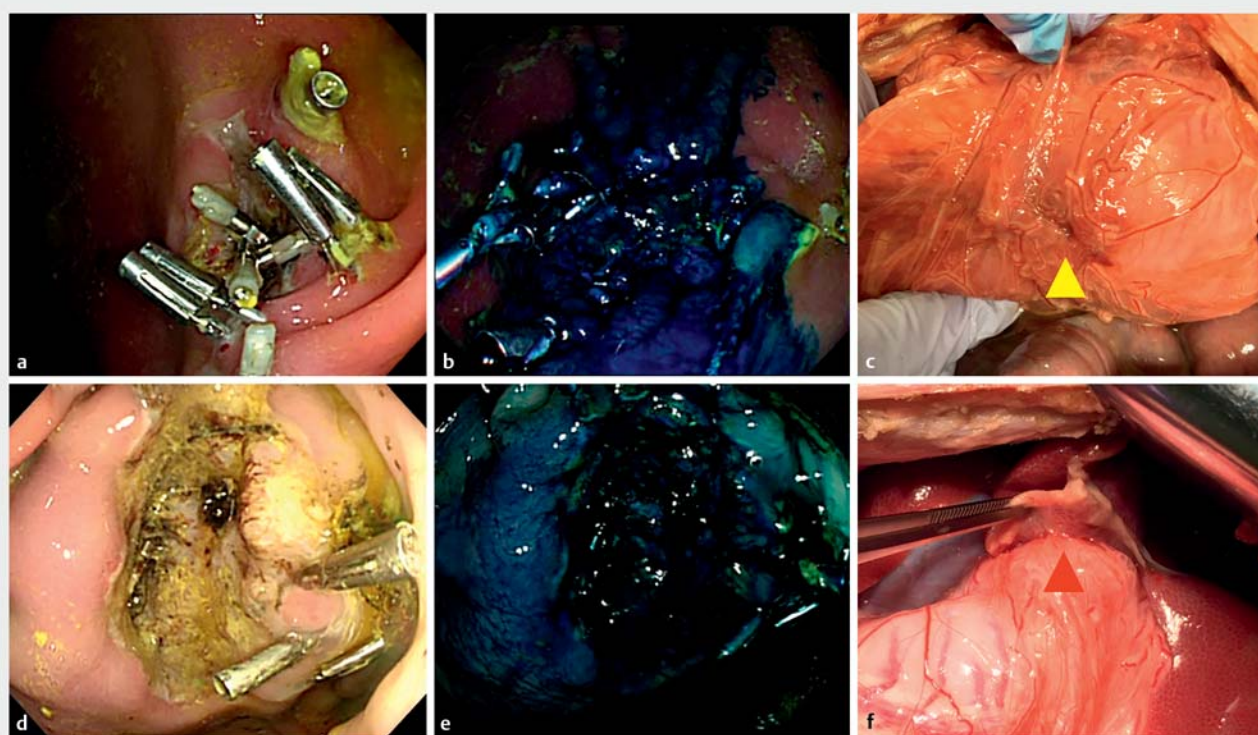
control was impossible in the porcine model. It is usual in clinical practice to fast a few days after EFTR. The fasting period might influence dehiscence. Third, the strength of closure by modified LACC seemed insufficient to maintain closure. A previous study suggested that the closure strength of purse-string suturing using endoloop and simple clip closure was weaker than that of hand suturing [20]. Besides, even if hand suturing were applied, permanent closure in all cases after gastric ESD is difficult [9, 10]. We assumed that the closure strength of modified LACC was equivalent to that of purse-string suturing or simple clip closure; thus, we applied a precutting and locking technique for LACC to reinforce the closure. However, the closure was dehiscent. Maintenance of closure after gastric EFTR is still challenging and the rate of closure maintenance after gastric EFTR has not been fully evaluated for other methods. Improvement in LACC (e. g., application of cinching devices or tissue adhesives) in future might be a good option to strengthen the closure.

In comparison with previously reported methods, modified LACC was easily available without special devices, because hand suturing and purse-string require a two-channel endoscope, and expensive devices are required for OTSC and OverStitch. However, median closure time for modified LACC (43.5

► **Table 1** Outcomes of modified LACC after EFTR.

Case	Location	ESD defect size, mm	EFTR defect size, mm	Complete closure	Closure procedure time, min	Total no. clips	Modified LACC times
1	Antrum, Gre	26 × 25	18 × 16	Yes	45	20	3
2	Antrum, Gre	28 × 26	18 × 17	Yes	65	27	4
3	Antrum, Gre	27 × 25	20 × 19	Yes	38	20	3
4	Lower body, Ant	27 × 26	18 × 18	Yes	42	24	3
5	Lower body, Ant	29 × 28	19 × 18	Yes	62	28	4
6	Lower body, Ant	30 × 28	21 × 19	Yes	37	25	3

LACC, line-assisted complete closure; EFTR, endoscopic full-thickness resection; ESD, endoscopic submucosal dissection.



► **Fig. 3** Closure site on Day 4. **a** Partial dehiscence was observed (greater curvature of the antrum). **b** Methylene blue was poured into the closure sites (luminal side). **c** The defects were covered by greater omentum (peritoneal side). **d** Complete dehiscence was observed (anterior wall of the lower body). **e** Methylene blue was poured into the closure sites (luminal side). **f** The defects were covered by surrounding tissue (peritoneal side).

minutes) was not shorter than that of other reported methods for similar defect size in porcine or human studies: hand suturing, median 25 to 49.5 minutes [9, 10]; O-ring and OTSC, median 35.5 minutes [12]; and pure-string suture, mean 14.6 minutes [8]. Further developments are needed to reduce procedure time.

This study had several limitations. First, small numbers of porcine models were used for the pilot study to minimize animal suffering. Second, the follow-up period was limited to Day 4. Long-term outcome of modified LACC after EFTR was unclear, although most delayed AEs occur within 2 days after

endoscopic resection. However, administration of an antibiotic during most of the study period might mask peritonitis. Third, the closure site and the presence of leakage were evaluated macroscopically. The site was carefully observed using methylene blue, but there was no pathological evaluation. Fourth, the LACC time varied, although the size of the defect treated by modified LACC was limited. Although three experts performed the procedures, the stability and reproducibility of modified LACC after EFTR was questionable, based on results from this study. Fifth, many more clips were used for modified LACC than we anticipated, because there are few folds in the

► **Table 2** Clinical course after line-assisted complete closure.

Case	WBC, / μ L	WBC, / μ L	BW, kg	BW, kg	No. remain- ing clips (Day 4)	Maintaining closure (Day 4)	Peritonitis	Leakage	Clinical course
	(Day 0)	(Day 4)	(Day 0)	(Day 4)					
1	17000	35100	25.9	27	9	Partially dehiscent	No	No	Being well
2	19000	23000	23.4	26.2	6	Partially dehiscent	No	No	Being well
3	19700	25200	23.8	26.2	7	Partially dehiscent	No	No	Being well
4	17500	15700	30.8	31.8	0	Entirely dehiscent	No	No	Being well
5	19900	20300	22.5	23.4	0	Entirely dehiscent	No	No	Being well
6	15700	17400	26	26.4	0	Entirely dehiscent	No	No	Being well

WBC, white blood cell; BW, body weight.

gastric of porcine models and endoscopy maneuverability was poor, which was not cost-effective.

Conclusions

In conclusion, we have shown that modified LACC can be used to close the defect after gastric EFTR in porcine models, although the closure is not maintained. Fortunately, the clinical course after the procedures was good in all cases, given the rapid adhesion, but improvement is needed to maintain closure before using the technique in human EFTR.

Acknowledgments

The authors are grateful to Yoji Takeuchi MD (Osaka International Cancer Institute) who developed LACC with the first author of this article, and Tatsuma Nomura MD (Ise Red Cross Hospital) who advised about the technique to fix the clip and line. We thank Haruko Hirayama, DVM, PhD, and Katsumi Mominoki, DVM, PhD (Department of Animal Resources, Advanced Science Research Center, Okayama University) who supported the animal experiments. We thank Cathel Kerr, BSc, PhD, from Edanz (<https://jp.edanz.com/ac>) for editing a draft of this manuscript. This study was supported by J-CASE Research Grant.

Competing interests

Author Y.Y. received honoraria from Olympus, Cor., and FUJIFILM Cor. Author H.O. received honoraria from Otsuka Pharmaceutical Co., Ltd., Takeda Pharmaceutical Co. Ltd., AstraZeneca K.K., Daiichi Sankyo Co., Ltd., Nippon Kayaku Co., Ltd., EA Pharma Co., Ltd., Eisai Co., Ltd., Otsuka Pharmaceutical Factory, Inc., Viartis Inc., Olympus, Cor., FUJIFILM Cor., Miyarisan Pharmaceutical Co., Ltd, Mylan EPD G.K., Chugai Pharmaceutical Co., Ltd., Novartis Pharma K.K., Taiho Pharmaceutical Co., Ltd., and Bayer Yakuin, Ltd.

Funding

J-CASE Research Grant 2019

References

- [1] Zhou PH, Yao LQ, Qin XY et al. Endoscopic full-thickness resection without laparoscopic assistance for gastric submucosal tumors originated from the muscularis propria. *Surg Endosc* 2011; 25: 2926–2931
- [2] Schmidt A, Beyna T, Schumacher B et al. Colonoscopic full-thickness resection using an over-the-scope device: a prospective multicentre study in various indications. *Gut* 2018; 67: 1280–1289
- [3] Aslanian HR, Sethi A. ASGE Technology Committee. et al. ASGE guideline for endoscopic full-thickness resection and submucosal tunnel endoscopic resection. *VideoGIE* 2019; 4: 343–350
- [4] Shichijo S, Uedo N, Yanagimoto Y et al. Endoscopic full-thickness resection of gastric gastrointestinal stromal tumor: a Japanese case series. *Ann Gastroenterol* 2019; 32: 593–599
- [5] Backes Y, Kappelle WFW, Berk L et al. Colorectal endoscopic full-thickness resection using a novel, flat-base over-the-scope clip: a prospective study. *Endoscopy* 2017; 49: 1092–1097
- [6] Al-Bawardy B, Rajan E, Wong Kee Song LM. Over-the-scope clip-assisted endoscopic full-thickness resection of epithelial and subepithelial GI lesions. *Gastrointest Endosc* 2017; 85: 1087–1092
- [7] Shi Q, Chen T, Zhong YS et al. Complete closure of large gastric defects after endoscopic full-thickness resection, using endoloop and metallic clip interrupted suture. *Endoscopy* 2013; 45: 329–334
- [8] Qiao Z, Ling X, Zhu J et al. Therapeutic application of purse-string sutures with nylon loops and metal clips under single-channel endoscopy for repair of gastrointestinal wall defects. *Exp Ther Med* 2018; 15: 4356–4360
- [9] Goto O, Sasaki M, Akimoto T et al. Endoscopic hand-suturing for defect closure after gastric endoscopic submucosal dissection: a pilot study in animals and in humans. *Endoscopy* 2017; 49: 792–797
- [10] Goto O, Oyama T, Ono H et al. Endoscopic hand-suturing is feasible, safe, and may reduce bleeding risk after gastric endoscopic submucosal dissection: a multicenter pilot study (with video). *Gastrointest Endosc* 2020; 91: 1195–1202

- [11] Akimoto T, Goto O, Sasaki M et al. Endoscopic suturing promotes healing of mucosal defects after gastric endoscopic submucosal dissection: endoscopic and histologic analyses in in vivo porcine models (with video). *Gastrointest Endosc* 2020; 91: 1172–1182
- [12] Kobara H, Nishiyama N, Fujihara S et al. Traction-assisted endoscopic full-thickness resection followed by O-ring and over-the-scope clip closure in the stomach: an animal experimental study. *Endosc Int Open* 2021; 9: E51–E57
- [13] Granata A, Amata M, Ligresti D et al. Underwater full-thickness resection of a duodenal bulb gastrointestinal stromal tumor with Over-Stitch defect repair. *Endoscopy* 2019; 51: E207–E208
- [14] Yamasaki Y, Takeuchi Y, Kato M et al. Line-assisted complete closure of large gastric mucosal defects by use of multiple clip-and-line technique. *VideoGIE* 2016; 1: 49–50
- [15] Yamasaki Y, Takeuchi Y, Iwatsubo T et al. Line-assisted complete closure for a large mucosal defect after colorectal endoscopic submucosal dissection decreased post-electrocoagulation syndrome. *Dig Endosc* 2018; 30: 633–641
- [16] Ohmori M, Yamasaki Y, Yamamoto S et al. A novel precutting clip closure method using a reopenable clip after colorectal endoscopic submucosal dissection. *Endoscopy* 2021; doi:10.1055/a-1559-1586
- [17] Nomura T, Sugimoto S, Kawabata M et al. Large colorectal mucosal defect closure post-endoscopic submucosal dissection using the reopenable clip over line method and modified locking-clip technique. *Endoscopy* 2022; 54: E63–E64
- [18] Nakahira H, Takeuchi Y, Garcia JS et al. Line-assisted endoscopic complete closure of a large perforation during colonic endoscopic submucosal dissection. *Endoscopy* 2018; 50: E32–E33
- [19] Ominami M, Nagami Y, Tanaka C et al. Endoscopic technique for closure of a large gastric tube perforation by using endoclips with line-assisted complete closure. *Endoscopy* 2019; 51: E49–E50
- [20] Goto O, Sasaki M, Ishii H et al. A new endoscopic closure method for gastric mucosal defects: feasibility of endoscopic hand suturing in an ex vivo porcine model (with video). *Endosc Int Open* 2014; 2: E111–E116