

A Pediatric COVID-19 Study: Retinal Nerve Fiber Layer, Ganglion Cell Layer, and Alterations in Choroidal Thickness in Swept-Source OCT Measurements

Eine pädiatrische COVID-19-Studie: Veränderungen der Netzhautnervenfaserschicht, Ganglienzellschicht und Aderhautdicke bei Swept-Source-OCT-Messungen

Authors

Cetin Akpolat¹ , Tugba Cetinkaya², Muhammed M. Kurt²

Affiliations

- 1 Ophthalmology, Sisli Hamidiye Etfal Egitim ve Arastirma Hastanesi, Halaskargazi cd. Etfal sok., Istanbul, Turkey
- 2 Ophthalmology, Samsun Education and Research Hospital, Samsun, Turkey

Key words

pediatric COVID-19, retinal neurodegeneration, swept-source, optical coherence tomography

Schlüsselwörter

pädiatrisches COVID-19, Netzhautneurodegeneration, Swept-Source-optische Kohärenztomografie

received 23. 12. 2021
 accepted 23. 2. 2022
 published online 14. 4. 2022

Bibliography

Klin Monatsbl Augenheilkd 2022; 239: 916–922

DOI 10.1055/a-1785-3863

ISSN 0023-2165

© 2022. Thieme. All rights reserved.

Georg Thieme Verlag KG, Rüdigerstraße 14,
70469 Stuttgart, Germany

Correspondence

Dr. Cetin Akpolat
 Sisli Hamidiye Etfal Egitim ve Arastirma Hastanesi,
 Ophthalmology
 Halaskargazi cd. Etfal sok., 34377 Istanbul, Turkey
 Phone: +90 53 03 24 49 36, Fax: +90 21 22 24 07 72
 akpolatcetin@yahoo.com

ABSTRACT

Purpose To investigate early covid measurements of central macular thickness (CMT), retinal nerve fiber layer (RNFL), ganglion cell layer (GCL) thickness, and choroidal thickness (ChT) in children recovered from coronavirus disease 2019 (COVID-19).

Methods This cross-sectional study was carried out 4 weeks after completed COVID-19 treatment. The diagnosis of the Alpha variant COVID-19 was made by the polymerase chain reaction test after prediagnosis with clinical, laboratory, and radiological findings. A total of 46 children were included in the study. Pediatric patients who received COVID-19 treatment comprised the COVID-19 group (24 children), and healthy children were enrolled in the control group (22 children). Only the right eyes of the participants were enrolled in the study. All pediatric patients in the COVID-19 group required hospitalization without the need for intubation. Swept-source optical coherence tomography (SS-OCT) was used to measure CMT, RNFL, and GCL thickness, and ChT measurements.

Results The COVID-19 and control groups had similar mean values of visual acuity, intraocular pressure, spherical equivalent, axial length, and CMT ($p > 0.05$ for all). RNFL thickening, GCL, and choroidal thinning were observed in all SS-OCT measurements of COVID-19 children. However, RNFL thickening was significant only in the global and nasal peripapillary quadrants. GCL thinning was significant in the nasal/inferior sector ($p < 0.002$ for all). Some significant correlations were observed between the mean levels of inflammatory markers and OCT measurements ($p < 0.002$).

Conclusion This study may be among the first reports of SS-OCT examination of COVID-19 children. OCT measurements showed changes in retinal and ChT in the COVID-19 children as in adult patients.

ZUSAMMENFASSUNG

Zweck Untersuchung der frühen COVID-Messungen der zentralen Makuladicke (CMT), der retinalen Nervenfaserschicht (RNFL), der Dicke der Ganglienzellschicht (GCL) und der Aderhautdicke (ChT) bei Kindern, die sich von der Coronavirus-Krankheit 2019 (COVID-19) erholt haben.

Methoden Diese Querschnittsstudie wurde 4 Wochen nach der abgeschlossenen COVID-19-Behandlung durchgeführt. Die Diagnose der Alpha-Variante von COVID-19 wurde durch den Polymerase-Kettenreaktions-Test nach Vordiagnose mit

klinischen, Labor- und radiologischen Befunden gestellt. Insgesamt wurden 46 Kinder in die Studie eingeschlossen. Pädiatrische Patienten, die eine COVID-19-Behandlung erhielten, bildeten die COVID-19-Gruppe (24 Kinder) und gesunde Kinder wurden in die Kontrollgruppe aufgenommen (22 Kinder). Nur das rechte Auge der Teilnehmer wurde in die Studie aufgenommen. Alle pädiatrischen Patienten in der COVID-19-Gruppe mussten ohne Intubation ins Krankenhaus eingeliefert werden. Die optische Kohärenztomografie mit Swept-Source (SS-OCT) wurde verwendet, um CMT-, RNFL-, GCL-Dicke- und ChT-Messungen zu messen.

Ergebnisse Die COVID-19- und die Kontrollgruppe hatten ähnliche Mittelwerte für Sehschärfe, Augeninnendruck, sphärisches Äquivalent, axiale Länge und CMT ($p > 0,05$ für alle).

RNFL-Verdickung, GCL und Aderhautverdünnung wurden bei allen SS-OCT-Messungen von COVID-19-Kindern beobachtet. Die RNFL-Verdickung war jedoch nur in den globalen und nasalen peripapillären Quadranten signifikant. Die GCL-Verdünnung war im nasalen/unteren Bereich signifikant ($p < 0,002$ für alle). Einige signifikante Korrelationen wurden zwischen den mittleren Konzentrationen von Entzündungsmarkern und OCT-Messungen beobachtet ($p < 0,002$).

Schlussfolgerung Diese Studie gehört möglicherweise zu den ersten Berichten über die SS-OCT-Untersuchung von COVID-19-Kindern. OCT-Messungen zeigten bei den COVID-19-Kindern wie bei erwachsenen Patienten Veränderungen der Netzhaut- und Aderhautdicke.

Introduction

The World Health Organization accepted the coronavirus disease 2019 (COVID-19), raised from China in December 2019, as a global pandemic in March 2020 due to its quick spread and possible serious sequels and fatal results [1]. The pathogen is an enveloped RNA virus of the beta coronavirus family and is called severe acute respiratory syndrome coronavirus 2 (SARS-CoV-2) [2, 3]. Human-to-human transmission of the COVID-19 has been reported via the spread of respiratory droplets [4]. COVID-19 mainly causes respiratory tract infections [5, 6]. However, COVID-19 has a wide clinical spectrum from mild to severe manifestations including cough, fever, myalgia, fatigue, dyspnea, anosmia, diarrhea, pneumonia, severe acute respiratory syndrome, septic shock, multi-organ failure, and even death [7–10].

The mechanism of the SARS-CoV-2 infection is thought to be the angiotensin-converting enzyme (ACE) 2 receptors located on the host cells [11–13]. COVID-19 might result in hypercoagulability and exacerbated systemic inflammation by the ACE 2 receptors expressed almost in all major organs, properly on the endothelial cells [5, 14]. The endothelial cells have important functions to prevent ischemia, tissue edema, vasoconstriction, and coagulation [14]. The involvement of endothelial cells can lead to impaired microvasculature function with increased inflammatory marker responses (fibrinogen, D-dimer, C-reactive protein, etc.) in COVID-19 patients [14].

Previous reports have demonstrated the presence of viral RNA in tears of adult COVID-19 patients [15, 16]. Conjunctival hyperemia, epiphora, and chemosis have been reported as anterior segment findings in adult COVID-19 patients [17, 18]. Meanwhile, microhemorrhages, cotton wool spots, and hyperreflective lesions have been documented as retinal findings in adult COVID-19 patients [17]. The existence of viral RNA has also been demonstrated in the conjunctiva and tear secretions of pediatric patients [19]. It has been postulated that pediatric COVID-19 patients have a better prognosis, shorter disease duration, and lower disease prevalence than adult patients [20, 21]. There are limited studies about ocular involvement of the COVID-19 in the pediatric population. Moreover, to the best of our knowledge, no reports have been documented regarding optical coherence tomography (OCT)

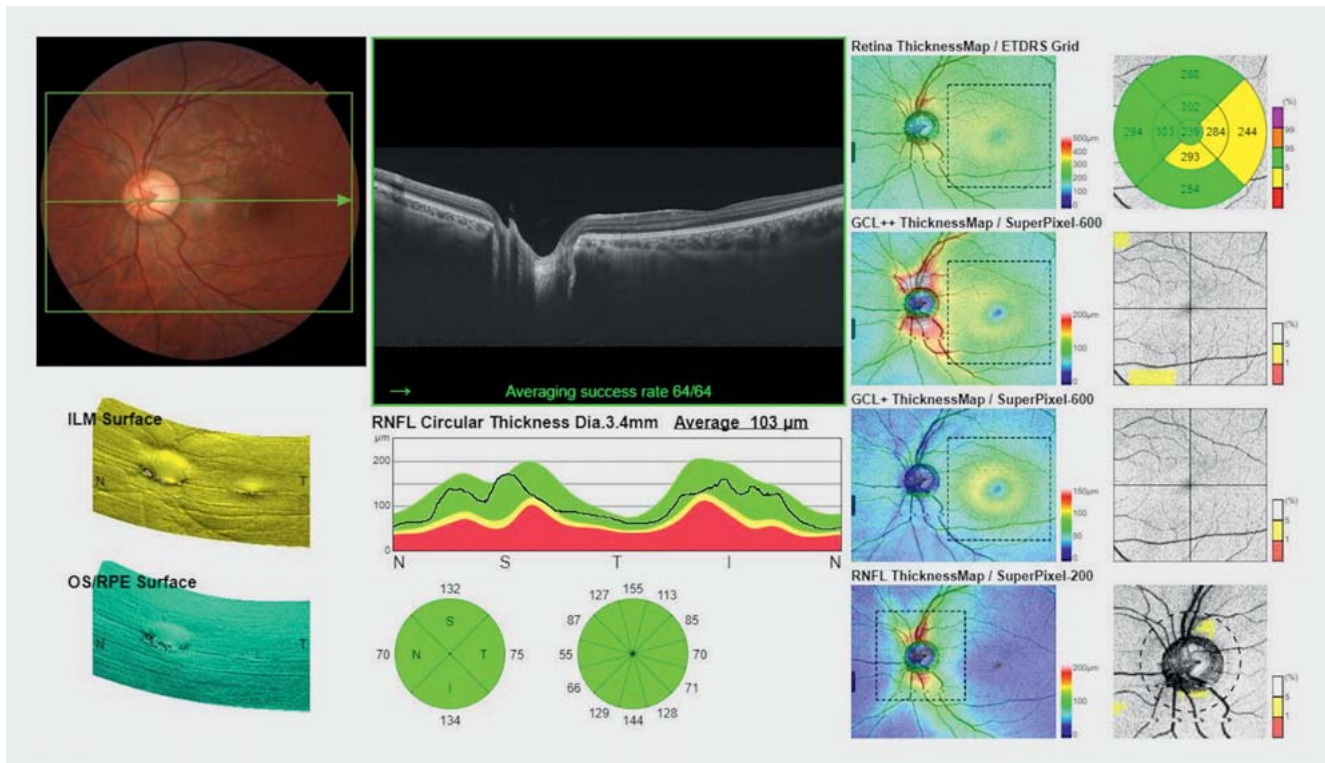
findings in the COVID-19 children. In the present study, we intended to compare early covid swept-source (SS) OCT measurements between pediatric COVID-19 patients and healthy children to assess retinal neurodegeneration and choroidal thickness (ChT) alterations.

Methods

The present study was designed cross-sectionally and conducted in adherence to the tenets of the Declaration of Helsinki. The institutional review board approved the study. All parents of the children signed the informed consent before study enrollment.

Pediatric Subjects

A total of 46 children with regular controls (7–18 years old) were randomly circuted in the study between April 2020 and October 2020. Only the right eyes of the participants were enrolled in the study. Twenty-four eyes of 24 early post-COVID-19 (Alpha variant) children were included in the COVID-19 group. These patients were enrolled in the study 4 weeks (28 days) after they completed COVID-19 treatment to investigate early covid posterior segment measurements. The patients did not have any COVID-19 symptoms at the time of examination. Twenty-two eyes of age- and gender-matched 22 healthy children with negative COVID-19 antibody blood test results served as the control group. Clinical, laboratory, and radiologic findings were evaluated for COVID-19 prediagnosis. The blood tests for inflammatory markers were performed at the time of admission to the hospital (just prior to the hospitalization). The confirmation of the Alpha variant COVID-19 diagnosis was performed by the polymerase chain reaction (PCR) test. All children in the COVID-19 group had positive PCR test results for SARS-CoV-2. All children cooperated with ophthalmic examination and OCT measurements. All children in the COVID-19 group required hospitalization for some lung involvement. Fortunately, none of the children had oxygen saturation lower than 90%, so no one was intubated. The COVID-19 group completed oral combined treatment of ampicillin/sulbactam and azithromycin for 7 days. All children had a detailed ocular examination including best-corrected visual acuity (BCVA, in logMAR), intraocular pressure (IOP, mmHg, with a pneumatic tonometry-Topcon,



► **Fig. 1** Central macula, retinal nerve fiber layer, and ganglion cell layer thickness measurements performed by swept-source optical coherence tomography.

Tokyo Japan), spheric equivalent (SE, Diopter), axial length (AxL, mm), biomicroscopic anterior segment (no signs of conjunctivitis, clear cornea, no cells in the anterior chamber, normal iris, symmetric pupil, and crystalline phakic lens) and fundus assessment as well as SS-OCT measurements. The children with IOP greater than 21 mmHg, refractive error $> \pm 1.00$, AxL of 22–24 mm, history of an ocular disorder (corneal opacity, cataract, ocular inflammation, choroidal or retinal diseases, etc.), previous ophthalmic surgery, and systemic disease were not included in the study.

Optical Coherence Tomography Measurement System

All scans were taken by the same experienced and masked researcher and all OCT parameters were measured during the morning shift to inhibit diurnal effects. The scans with poor quality ($< 60/100$) were excluded and repeated images were taken up to get high-quality results. The scans were performed using a deep range imaging Triton model SS-OCT (Topcon, Tokyo, Japan) with the 3D wide protocol (12.0×9.0 mm) measuring on the peripapillary area and macula. The central macular thickness (CMT, μm) was measured between the inner limiting membrane (ILM) and retinal pigment epithelium (RPE) under the fovea. The retinal nerve fiber layer (RNFL) thickness measurement was performed from the ILM to the ganglion cell layer (GCL) borders at the temporal, superior, nasal, and inferior peripapillary quadrants. The GCL thickness was measured from two different layers and in six sectors of the macula (superior, temporal-inferior, temporal-superior, inferior, nasal-inferior, and nasal-superior). The GCL+ thick-

ness was measured from the RNFL and the inner nuclear layer (INL). The GCL++ thickness was measured from the ILM to the INL borders. The ChT measurements were performed between the Bruch membrane and the sclera-choroidal interface at five different points (subfovea, 500 microns nasal and temporal points from the fovea, 1500 microns nasal and temporal points from the fovea; ► **Fig. 1**).

Statistical Analysis

The SPSS software version 21.0 (IBM Corp., Armonk, NY, USA) was used for the statistical analysis of the study. Continuous variables were described as mean \pm standard deviation. The detection of normal distribution was analyzed by the Shapiro-Wilk test. The BCVA, IOP, and SS-OCT measurements were compared between the groups. The chi-square test was used for the analysis of categorical parameters. A p value of < 0.05 was accepted as significant. Since the Student's t-test cannot be employed for comparing many different OCT parameters between the groups, the ANOVA test was used for statistical analysis, and the Bonferroni correction was employed for multiple testing. Correlations of inflammation markers with OCT parameters were similarly analyzed with correction. For these parameters, the statistical significance was accepted if a p value of < 0.002 was obtained.

► **Table 1** The mean concentrations of the proinflammatory markers in the COVID-19 group.

Parameters (mean ± SD)	COVID-19 group	Normal range
Fibrinogen (mg/L)	297.79 ± 78.63 (210–492)	200–400
D-dimer (µg/mL)	1.34 ± 0.80 (0.19–2.98)	< 0.5
WBC count (per mcl)	8682.50 ± 5749.86 (3300–26300)	5000–10 000
ESR (mm/hour)	23.54 ± 12.11 (5–52)	0–10
CRP (mg/L)	10.39 ± 12.19 (3–49)	0–5

SD: standard deviation, COVID-19: coronavirus disease 2019, WBC: white blood cell, ESR: erythrocyte sedimentation rate, CRP: C-reactive protein

► **Table 2** Assessment of the mean RNFL thickness measurements in the COVID-19 and control groups.

Thickness measurements (µm)	COVID-19 group (n = 48)	Control group (n = 44)	p*
RNFL_Global	109.79 ± 9.77	100.72 ± 9.64	0.001**
RNFL_Temporal	77.37 ± 10.67	74.77 ± 8.58	0.104
RNFL_Superior	137.25 ± 15.74	131.18 ± 15.15	0.045
RNFL_Nasal	84.76 ± 10.28	72.98 ± 15.09	<0.001**
RNFL_Inferior	142.05 ± 11.51	136.64 ± 15.09	0.009

RNFL: retinal nerve fiber layer, COVID-19: coronavirus disease 2019, * statistical analysis was calculated by the ANOVA test, ** statistically significant

Results

The mean age of the children in the COVID-19 group was 13.29 ± 2.91 (8–17) years and the mean age of the children in the control group was 13.09 ± 2.88 (7–17) years ($p = 0.759$). The similarity was noted between the gender numbers of the COVID-19 (13 female, 11 male) and control (12 female, 10 male) groups ($p = 0.412$). The mean BCVA value was 0.02 ± 0.01 logMAR in the COVID-19 group, which was similar to the control group's value (0.01 ± 0.01 logMAR), ($p = 0.341$). The mean IOP value in the COVID-19 group (13.88 ± 2.83 mmHg) was also similar to the control group's mean IOP value (13.47 ± 2.45 mmHg), ($p = 0.372$). The mean SE and AxL values were also similar in the COVID-19 (SE = +0.52 ± 0.04, AxL = 22.85 ± 4.22) and control groups (SE = +0.48 ± 0.05, AxL = 22.92 ± 5.06) ($p = 0.216$ and $p = 0.302$, respectively).

None of the patients in the COVID-19 group showed any signs of retinopathy in the biomicroscopic fundus assessment. Approximately 70.8% (17) of the children presented with fever, 37.5% (9) with cough, 16.7% (4) with weakness, 12.5% (3) with diarrhea, 8.3% with a sore throat (2) and vomiting (2), and 4.2% with shortness of breath (1), headache (1), chest pain (1), and joint pain (1) in the COVID-19 group. The mean hospitalization duration was 4.8 ± 2.3 days (3–8 days). The time since the positive PCR test results was 28 days + hospitalization duration (4.8 ± 2.3 days [3–8 days]) and time since the first symptoms was plus 2 days (the positive-resulted PCR tests were performed 2 days before the hospitalization). The mean levels of fibrinogen, D-dimer, white blood cell (WBC) count, erythrocyte sedimentation rate (ESR), and C-re-

active protein (CRP) in the COVID-19 group are presented in ► **Table 1**.

The mean CMT values of the children in the COVID-19 group (227.48 ± 15.85 µ) and the healthy individuals in the control group (225.68 ± 16.96 µ) were similar ($p = 0.601$). The mean RNFL thickness measurements in the overall and peripapillary quadrants including the temporal, superior, nasal, and inferior areas are presented in ► **Table 2**. All RNFL thickness measurements were thicker in the COVID-19 group. Statistically significant differences were noted in the global and nasal RNFL quadrant thickness measurements between the COVID-19 and control groups ($p < 0.002$ for both). The mean GCL+ and GCL++ thickness measurements in the superior, temporal-inferior, temporal-superior, inferior, nasal-inferior, and nasal-superior sectors are presented in ► **Table 3**. All GCL thickness measurements were thinner in the COVID-19 group. However, statistically significant outcomes were observed only in the nasal-inferior sectors of the GCL+ and GCL++ between the COVID-19 and control groups ($p < 0.05$ for all). The mean thickness measurements performed at five different choroidal points (subfovea, 500 µ, and 1500 µ far away from the subfovea at temporal and nasal sides) are presented in ► **Table 4**. All ChT measurements were thinner in the COVID-19 group. However, results very close to statistical significance were noted in the locations of temporal 500 µ, 1500 µ, and nasal 500 µ from the subfovea between the COVID-19 and control groups ($p = 0.002$ for all).

The correlations of inflammation markers with the OCT parameters that were different between COVID-19 and control groups were investigated. The mean initial inflammatory markers in the

► **Table 3** Comparison of the mean GCL+ and GCL++ thickness measurements between the COVID-19 and control groups.

Thickness measurements (µm)	COVID-19 group (n = 48)	Control group (n = 44)	p*
GCL+_S	72.45 ± 9.19	73.24 ± 4.52	0.422
GCL+_Ti	72.24 ± 6.78	73.82 ± 4.27	0.603
GCL+_Ts	72.67 ± 7.38	73.08 ± 4.38	0.588
GCL+_I	70.83 ± 8.44	78.86 ± 4.27	0.012
GCL+_Ni	72.35 ± 10.47	79.80 ± 5.01	<0.001**
GCL+_Ns	73.62 ± 11.29	79.48 ± 4.77	0.016
GCL++_S	105.52 ± 10.11	109.16 ± 7.05	0.034
GCL++_Ti	97.07 ± 8.01	98.22 ± 5.16	0.212
GCL++_Ts	93.76 ± 8.08	96.74 ± 5.67	0.024
GCL++_I	100.54 ± 9.85	109.52 ± 7.22	0.010
GCL++_Ni	113.40 ± 11.95	123.12 ± 17.50	0.001**
GCL++_Ns	116.95 ± 11.04	121.76 ± 7.08	0.006

GCL: ganglion cell layer, COVID-19: coronavirus disease 2019, **statistical analysis was calculated by the ANOVA test, GCL+/++_S: ganglion cell layer in the superior sector, GCL+/++_Ti: ganglion cell layer in the temporal-inferior sector, GCL+/++_Ts: ganglion cell layer in the temporal-superior sector, GCL+/++_I: ganglion cell layer in the inferior sector, GCL+/++_Ni: ganglion cell layer in the nasal-inferior sector, GCL+/++_Ns: ganglion cell layer in the nasal-superior sector, **statistically significant

► **Table 4** Evaluation of the mean ChT measurements in the COVID-19 and control groups.

ChT Measurements (µm)	COVID-19 group (n = 48)	Control group (n = 44)	p*
Subfovea	340.02 ± 78.10	371.50 ± 86.14	0.035
Temporal_500	330.33 ± 79.94	368.40 ± 81.97	0.002
Temporal_1500	313.90 ± 71.57	345.80 ± 81.98	0.002
Nasal_500	321.45 ± 74.49	356.60 ± 87.95	0.002
Nasal_1500	280.90 ± 85.74	308.28 ± 85.13	0.016

ChT: choroidal thickness, COVID-19: coronavirus disease 2019, *statistical analysis was calculated by the ANOVA test, **statistically significant

COVID-19 group were correlated with some SS-OCT measurements. The mean fibrinogen level demonstrated a statistically significant positive correlation with the mean nasal RNFL thickness measurement ($r = +0.512$, $p < 0.001$). The mean D-dimer level in the COVID-19 group resulted in negative significant correlations with the mean GCL+ thickness measurement in the nasal-inferior sector ($r = -0.442$, $p = 0.001$). The mean ESR concentration showed statistically significant positive correlations with mean RNFL thickness measurements in an overall assessment ($r = +0.436$, $p = 0.001$). The mean ESR concentration showed a weak negative correlation with the mean GCL++ thickness measurements in the nasal-inferior ($r = +0.398$, $p = 0.002$) sector.

Discussion

SS-OCT is a noninvasive tool enabling repeatable and high-resolution images of the retina and even the choroid, which is a deeper

layer. OCT measurements can provide a comprehensive evaluation of retinal neurodegeneration, structural changes in the peripapillary area, macula, choroid, and optic nerve head related to many ocular or systemic disorders. In this study, SS-OCT was used to investigate the effect of SARS-CoV-2 neurotropism on the OCT thickness measurements and retinal neurodegeneration in early post-COVID-19 pediatric patients. No significant differences were observed between the mean CMT measurements of the two groups. Significant RNFL thickening was noted in the nasal quadrant and overall assessment, significant thinning was observed in the nasal-inferior GCL sectors, and weak choroidal thinning was observed in the temporal and nasal choroidal locations of the COVID-19 group. Some significant correlations were also found between the mean values of inflammatory markers and SS-OCT measurements.

Symptomatic anterior segment ocular involvement of SARS-CoV-2 has been reported in both adult and pediatric COVID-19

patients [18, 22]. However, to the best of our knowledge, very limited studies have been reported regarding OCT analysis of the retina or choroid in pediatric COVID-19 patients. Posterior segment findings in adult COVID-19 patients have been documented, such as acute macular neuroretinopathy papillophlebitis, retinitis, and optic neuritis [23, 24]. In addition, fine cotton wool spots accompanied by retinal microhemorrhages and focal hyperreflective spots in the GCL and IPL layers of OCT scans have also been reported in the adult COVID-19 patients [25]. Similarly, a case report also demonstrated a hyperreflective band, sparing the outer retina, at the levels of GCL and IPL in an SS-OCT image of an adult COVID-19 patient [26]. No vascular leakage or exudation and no hypo- or hyperautofluorescence were noted in this hyperreflective band [26]. A cohort observational study revealed that mean CMT and GCL values were similar in post-COVID-19 adult patients and healthy controls [27]. Retinal cotton wool spots (9 cases), vitreous fibrillary degeneration (10 cases), and papillary focal retinal hemorrhage (1 case) were examined in these adult COVID-19 patients [27]. Macular hole and epiretinal membrane had similar prevalence in both groups [27]. In contrast, it has been also postulated that these hyperreflective dots could be normal retinal vessels, and the cotton wool spots could be associated with myelinated nerve fibers or other pathological conditions [28].

Supporting our results, a cohort study in pediatric COVID-19 patients concluded that children with recent COVID-19 had RNFL thickening when compared to healthy children [29]. In contrast to our results, this study reported GCL thickening [29]. Similar to our study, another study showed RNFL thickening and GCL thinning in adult patients [30]. Moreover, the authors observed that this thickening of the RNFL was more prominent in the adult COVID-19 cases with cotton wool spots than the adult COVID-19 patients without cotton wool spots [30]. Similarly, a report concluded thickening of the RNFL in the adult COVID-19 patients, which might be due to COVID-19-related hypoxia and inflammation [31]. Another recent study reported that adult COVID-19 patients showed RNFL thickening in the overall assessment and in the nasal peripapillary quadrants, which was similar to our results, representing nasal RNFL thickening [32]. However, in contrast to our results, the authors noted that adult COVID-19 patients presented GCL thickening in the superior outer, nasal outer, and inferior outer sectors [32]. Interestingly, adult COVID-19 patients with anosmia and ageusia demonstrated a thicker peripapillary RNFL and macular GCL than the patients without these symptoms [32]. In contrast to this study and previously mentioned reports, a study reported no change in the mean RNFL thickness measurement of adult COVID-19 patients [33], and another study documented no differences in the mean RNFL, GCL, and ChT measurements of adult COVID-19 patients compared to healthy controls [34]. It is warranted to investigate if these RNFL and GCL thickness alterations are temporary or permanent results of COVID-19. RNFL thickening in the present study might be assumed by the initial effect of inflammation in the short-term period [35]. Unlike RNFL thickening, short-term GCL and weak choroidal thinning in this study may be explained by earlier neurodegeneration of the ganglion cells in the GCL than the axonal loss in the RNFL and preceding of retinal neurodegeneration than the vascular processes [35, 36].

The choroid is a highly vascularized tissue, which makes it more susceptible to inflammation and ischemia-associated systemic disorders. A reduction in ChT following exercise might be related to an exercise-induced decrease in the flow of the internal carotid artery [37]. Regarding weakly significant results of this study, it can be postulated that temporal and partial nasal choroidal thinning in the pediatric COVID-19 patients may be related to blood flow reduction due to SARS-CoV-2 caused hypercoagulability and vasculitis [38].

COVID-19 patients usually demonstrate elevated laboratory abnormalities in fibrinogen, D-dimer, WBC count, sedimentation, and CRP concentrations [39]. An elevated D-dimer level can be used as a biomarker for thrombus formation and as an independent predictor for hospital mortality [40]. A study reported that adult COVID-19 patients with elevated D-dimer concentrations presented with retinal vascular abnormalities [41]. The results of the present study have shown that pediatric COVID-19 patients with elevated D-dimer concentrations demonstrated nasal-inferior GCL+ thinning following the recovery of the SARS-CoV-2 infection. This offers the hypothesis that COVID-19 might lead to subclinical neurodegenerative alterations at the level of GCL, and the underlying physiopathology might be due to retinal vascular hemodynamic changes related to SARS-CoV-2 infection-induced effects and potential microangiopathy and a prothrombotic state.

The correlations of inflammatory markers with altered SS-OCT measurements showed coherent results with the alterations of thickness measurements representing RNFL thickening and GCL thinning. According to the literature review, no studies have been reported about the RNFL thickness analysis, neurodegenerative alterations in the GCL, or ChT changes in the early post-COVID-19 pediatric patients. Thus, this study may be among the first reports in the literature examining these OCT parameter changes associated with the COVID-19 infection in the pediatric population. However, the study has some limitations, including a relatively small sample size, lack of disease severity (none of the patients had a respiratory failure or were intubated), and short-term OCT measurements. Regarding these limitations, new studies with larger sample sizes, the presence of the disease severity, and long-term OCT measurements are warranted to be conducted in the future.

In conclusion, the present study compared SS-OCT measurements in early post-COVID-19 children and healthy controls. The outcomes of the study demonstrated retinal neurodegenerative alterations in the COVID-19 children and some significant differences in SS-OCT measurements between the pediatric COVID-19 and control groups. The clinical relevance of this study is that the neurodegenerative effect of SARS-CoV-2 in the retina and ChT alterations might be possible in pediatric patients without apparent ocular involvement as well as adult patients. Nonetheless, these changes may be secondary to the poor general condition of the affected pediatric patients, but not directly correlated to the outcomes of COVID-19.

Conflict of Interest

The authors declare that they have no conflict of interest.

References

- [1] World Health Organization. Coronavirus disease 2019 (COVID-19). Situation Report – 84. Accessed April 13, 2020 at: <https://www.who.int/publications/m/item/situation-report-84>
- [2] Zhu N, Zhang D, Wang W et al. A novel coronavirus from patients with pneumonia in China, 2019. *N Engl J Med* 2020; 283: 727–733
- [3] Guan W, Ni Z, Hu Y et al. Clinical characteristics of coronavirus disease 2019 in China. *N Engl J Med* 2020; 382: 1708–1720
- [4] Lu R, Zhao X, Li J et al. Genomic characterization and epidemiology of 2019 novel coronavirus: implications for virus origins and receptor binding. *Lancet* 2020; 395: 565–574
- [5] Wu Z, McGoogan JM. Characteristics of and important lessons from the coronavirus disease 2019 (COVID-19) outbreak in China: summary of a report of 72314 cases from the Chinese Center for Disease Control and Prevention. *JAMA* 2020; 323: 1239–1242
- [6] Chan JF, Kok KH, Zhu Z et al. Genomic characterization of the 2019 novel human-pathogenic coronavirus isolated from a patient with atypical pneumonia after visiting Wuhan. *Emerg Microbes Infect* 2020; 9: 221–236
- [7] Rothan HA, Byrareddy SN. The epidemiology and pathogenesis of coronavirus disease (COVID-19) outbreak. *J Autoimmun* 2020; 109: 102433
- [8] Huang C, Wang Y, Li X et al. Clinical features of patients infected with 2019 novel coronavirus in Wuhan, China. *Lancet* 2020; 395: 497–506
- [9] Luers JC, Rokohl AC, Loreck N et al. Olfactory and Gustatory Dysfunction in Coronavirus Disease 19 (COVID-19). *Clin Infect Dis* 2020; 71: 2262–2264. doi:10.1093/cid/ciaa525
- [10] Rokohl AC, Loreck N, Wawer Matos PA et al. More than loss of taste and smell: burning watering eyes in coronavirus disease 19 (COVID-19). *Clin Microbiol Infect* 2020; 26: 1560.e5–1560.e8. doi:10.1016/j.cmi.2020.08.018
- [11] Hoffmann M, Kleine-Weber H, Schroeder S et al. SARS-CoV-2 cell entry depends on ACE2 and TMPRSS2 and is blocked by a clinically proven protease inhibitor. *Cell* 2020; 181: 271–280
- [12] Grajewski RS, Rokohl AC, Becker M et al. A missing link between SARS-CoV-2 and the eye?: ACE2 expression on the ocular surface. *J Med Virol* 2021; 93: 78–79. doi:10.1002/jmv.26136
- [13] Grajewski RS, Rokohl AC, Becker M et al. Malignancy going viral: ACE2 and TMPRSS2 expression in conjunctival neoplastic diseases. *Ann Anat* 2021; 234: 151661. doi:10.1016/j.aanat.2020.151661
- [14] Becker R. COVID-19 update: Covid-19 associated coagulopathy. *J Thromb Thrombolysis* 2020; 50: 54–67
- [15] Seah IY, Anderson DE, Kang AEZ et al. Assessing viral shedding and infectivity of tears in coronavirus disease 2019 (COVID-19) patients. *Ophthalmology* 2020; 27: 977–979. doi:10.1016/j.ophtha.2020.03.026
- [16] Lu CW, Liu XF, Jia ZF. 2019-nCoV transmission through the ocular surface must not be ignored. *Lancet* 2020; 395: e39.
- [17] Marinho PM, Arcos AAA, Romano AC et al. Retinal findings in patients with COVID-19. *Lancet* 2020; 395: 1610
- [18] Wu P, Duan F, Luo C et al. Characteristics of ocular findings of patients with coronavirus disease 2019 (COVID-19) in Hubei province, China. *JAMA Ophthalmol* 2020; 138: 575–578
- [19] Rokohl AC, Grajewski RS, Matos PAW et al. Ocular Involvement in COVID-19: Conjunctivitis and More. *Klin Monbl Augenheilkd* 2021; 238: 555–560
- [20] Valente P, Iarossi G, Federici M et al. Ocular manifestations and viral shedding in tears of pediatric patients with coronavirus disease 2019: a preliminary report. *J AAPOS* 2020; 24: 212–215
- [21] Choi SH, Kim HW, Kang JM et al. Epidemiology and clinical features of coronavirus disease 2019 in children. *Clin Exp Pediatr* 2020; 63: 125–132
- [22] Ludvigsson JF. Systematic review of COVID-19 in children shows milder cases and a better prognosis than adults. *Acta Paediatr* 2020; 109: 1088–1095
- [23] Virgo J, Mohamed M. Paracentral acute middle maculopathy and acute macular neuroretinopathy following SARS-CoV-2 infection. *Eye (Lond)* 2020; 3: 1–2
- [24] Seah I, Agrawal R. Can the coronavirus disease 2019 (COVID-19) affect the eyes? A review of coronaviruses and ocular implications in humans and animals. *Ocul Immunol Inflamm* 2020; 28: 391–395
- [25] Marinho PM, Marcos AAA, Romano AC et al. Retinal findings in patients with COVID-19. *Lancet* 2020; 395: 1610
- [26] Ortiz-Egea JM, Ruiz-Medrano J, Ruiz-Moreno JM. Retinal imaging study diagnoses in COVID-19: a case report. *J Med Case Rep* 2021; 15: 15
- [27] Savastano MC, Gambini G, Cozzupoli GM et al.; Gemelli Against COVID-19 Post-Acute Care Study Group. Retinal capillary involvement in early post-COVID-19 patients: a healthy controlled study. *Graefes Arch Clin Exp Ophthalmol* 2021; 259: 2157–2165. doi:10.1007/s00417-020-05070-3
- [28] Vavvas DG, Sarraf D, Satta SR et al. Concerns about the interpretation of OCT and fundus findings in COVID-19 patients in recent Lancet publication. *Eye (Lond)* 2020; 9: 1–2
- [29] Burgos-Blasco B, Güemes-Villahoz N, Morales-Fernandez L et al. Retinal nerve fibre layer and ganglion cell layer changes in children who recovered from COVID-19: a cohort study. *Arch Dis Child* 2021; 107: 175–179. doi:10.1136/archdischild-2021-321803
- [30] González-Zamora J, Bilbao-Malavé V, Gándara E et al. Retinal Microvascular Impairment in COVID-19 Bilateral Pneumonia Assessed by Optical Coherence Tomography Angiography. *Biomedicines* 2021; 9: 247
- [31] Burgos-Blasco B, Güemes-Villahoz N, Donate-Lopez J et al. Optic nerve analysis in COVID-19 patients. *J Med Virol* 2021; 93: 190–191. doi:10.1002/jmv.26290
- [32] Burgos-Blasco B, Güemes-Villahoz N, Vidal-Villegas B et al. Optic nerve and macular optical coherence tomography in recovered COVID-19 patients. *Eur J Ophthalmol* 2022; 32: 628–636. doi:10.1177/11206721211001019
- [33] Savastano A, Crincoli E, Savastano MC et al. Peripapillary Retinal Vascular Involvement in Early Post-COVID-19 Patients. *J Clin Med* 2020; 9: 2895. doi:10.3390/jcm9092895
- [34] Cetinkaya T, Kurt MM, Akpolat C. Assessment of Retinal Neurodegeneration and Choroidal Thickness in COVID-19 Patients Using Swept-Source OCT Technology. *Klin Monbl Augenheilkd* 2021; 238: 1092–1097. doi:10.1055/a-1340-0066
- [35] Chen Y, Li J, Yan Y et al. Diabetic macular morphology changes may occur in the early stage of diabetes. *BMC Ophthalmol* 2016; 16: 1–7
- [36] Sohn EH, van Dijk HW, Jiao C et al. Retinal neurodegeneration may precede microvascular changes characteristic of diabetic retinopathy in diabetes mellitus. *Proc Natl Acad Sci U S A* 2016; 113: E2655–E2664
- [37] Li S, Pan Y, Xu J et al. Effects of physical exercise on macular vessel density and choroidal thickness in children. *Sci Rep* 2021; 11: 2015
- [38] Varga Z, Flammer AJ, Steiger P et al. Endothelial cell infection and endotheliitis in COVID-19. *Lancet* 2020; 395: 1417–1418
- [39] Lippi G, Plebani M. Laboratory abnormalities in patients with COVID-2019 infection. *Clin Chem Lab Med* 2020; 58: 1131–1134
- [40] Zhang L, Yan X, Fan Q et al. D-dimer levels on admission to predict in-hospital mortality in patients with Covid-19. *J Thromb Haemost* 2020; 18: 1324–1329
- [41] Guemes-Villahoz N, Burgos-Blasco B, Vidal-Villegas B et al. Reduced retinal vessel density in COVID-19 patients and elevated D-dimer levels during the acute phase of the infection. *Med Clin (Barc)* 2021; 156: 541–546. doi:10.1016/j.medcli.2020.12.006