

# Safety and effectiveness of underwater cold snare resection without submucosal injection of large non-pedunculated colorectal lesions




## Authors

Andrew W. Yen<sup>1,2</sup>, Joseph W. Leung<sup>1,2</sup>, Malcom Koo<sup>3,4</sup>, Felix W. Leung<sup>5,6</sup>

## Institutions

- 1 Sacramento Veterans Affairs Medical Center, VANCHCS, Division of Gastroenterology, Mather, California, United States
- 2 University of California Davis School of Medicine, Sacramento, California, United States
- 3 Graduate Institution of Long-term Care, Tzu Chi University of Science and Technology, Hualien City, Hualien, Taiwan
- 4 Dalla Lana School of Public Health, University of Toronto, Ontario, Canada
- 5 Sepulveda Ambulatory Care Center, VAGLAHS, Division of Gastroenterology, North Hills, California, United States
- 6 David Geffen School of Medicine at UCLA, Los Angeles, California, United States

submitted 15.9.2021

accepted after revision 29.11.2021

## Bibliography

Endosc Int Open 2022; 10: E791–E800

DOI 10.1055/a-1784-4523

ISSN 2364-3722

© 2022. The Author(s).

This is an open access article published by Thieme under the terms of the Creative Commons Attribution-NonDerivative-NonCommercial License, permitting copying and reproduction so long as the original work is given appropriate credit. Contents may not be used for commercial purposes, or adapted, remixed, transformed or built upon. (<https://creativecommons.org/licenses/by-nc-nd/4.0/>)

Georg Thieme Verlag KG, Rüdigerstraße 14,  
70469 Stuttgart, Germany

## Corresponding author

Andrew W. Yen, MD, MAS, Sacramento Veterans Affairs Medical Center, VANCHCS, Division of Gastroenterology, 111/G, 10535 Hospital Way, Mather, CA 95655  
Fax: +1-916-843-2673  
[andrew.yen3@va.gov](mailto:andrew.yen3@va.gov)

## ABSTRACT

**Background and study aims** Adverse events are uncommon with cold snaring, but cold techniques are generally reserved for lesions  $\leq 9$  mm out of concern for incomplete resection or inability to mechanically resect larger lesions. In a non-distended, water-filled lumen, colorectal lesions are not stretched, enabling capture and en bloc resection of large lesions. We assessed the effectiveness and safety of underwater cold snare resection (UCSR) without submucosal injection (SI) of  $\geq 10$  mm non-pedunculated, non-bulky ( $\leq 5$  mm elevation) lesions with small, thin wire snares.

**Patients and methods** Retrospective analysis of an observational cohort of lesions removed by UCSR during colonoscopy. A single endoscopist performed procedures using a small thin wire (9-mm diameter) cold or (10-mm diameter) hybrid snare.

**Results** Fifty-three lesions (mean 15.8 mm [SD 6.9]; range 10–35 mm) were removed by UCSR from 44 patients. Compared to a historical cohort, significantly more lesions were resected en bloc by UCSR (84.9% [45/53];  $P=0.04$ ) compared to conventional endoscopic mucosal resection (EMR) (64.0% [32/50]). Results were driven by high en bloc resection rates for 10- to 19-mm lesions (97.3% [36/37];  $P=0.01$ ). Multiple logistic regression analysis adjusted for potential confounders showed en bloc resection was significantly associated with UCSR compared to conventional EMR (OR 3.47,  $P=0.027$ ). Omission of SI and forgoing prophylactic clipping of post-resection sites did not result in adverse outcomes.

**Conclusions** UCSR of  $\geq 10$  mm non-pedunculated, non-bulky colorectal lesions is feasible with high en bloc resection rates without adverse outcomes. Omission of SI and prophylactic clipping decreased resource utilization with economic benefits. UCSR deserves further evaluation in a prospective comparative study.

## Introduction

Conventional endoscopic mucosal resection (EMR) and underwater resection (polypectomy) are established techniques for removal of colorectal lesions. Although a newer approach, underwater resection is safe and effective [1, 2] with advantages compared to conventional EMR including faster resection and reduced resource utilization [3]. But underwater resection is still not widely practiced outside of referral centers. Simplified, practical, safe and effective modifications to the technique may encourage adoption.

Endoscopic resection of neoplastic colorectal lesions  $\geq 10$  mm in size is generally accomplished with a snare and electrocautery. Though effective, diathermy to assist with polypectomy introduces risks, including perforation, delayed bleeding and post-polypectomy syndrome [4]. Conversely, adverse events (AEs) are uncommon with cold resection techniques that avoid electrocautery [3–7], but cold techniques have been reserved mainly for lesions  $\leq 9$  mm in size out of concern for incomplete resection, immediate bleeding and/or inability to remove lesions  $\geq 10$  mm en bloc.

The role of cold snare resection has expanded recently, however, owing to its safety and efficacy, although cold snaring larger ( $\geq 10$  mm) lesions remains more limited and, at present, primarily focused on serrated class lesions [8–12] as these polyps commonly lack high grade histology and have lower rates of submucosal extension [13]. Polypectomy is often successfully performed in a piecemeal fashion for larger serrated lesions with smaller sized (9–10 mm) dedicated cold snares with enhanced mechanical cutting characteristics. However, concern for incomplete resection of polyps and residual or recurrent neoplasia, commonly associated with piecemeal resection [14], is a notable area that deserves attention.

Underwater resection of colorectal lesions with a snare, with or without diathermy, is a safe and effective alternative to traditional resection techniques [3]. An observed advantage of underwater resection is the ability to capture larger surface areas and volumes of tissue in a non-distended lumen compared to polypectomy in a gas-distended colon. Even large lesions can be removed en bloc [15]. But underwater resection of lesions  $\geq 10$  mm has also generally been performed with electrocautery and thus, still carries with it the accompanying thermal risks. Therefore, our aim was to assess the safety and effectiveness of a simplified approach, underwater cold snare resection (UCSR) without submucosal injection (SI) of  $\geq 10$  mm non-pedunculated, non-bulky ( $\leq 5$  mm elevation) colorectal lesions utilizing small, thin (0.3 mm) wire dedicated cold or hybrid snares.

## Patients and methods

### Study design

This was a retrospective observational study conducted at a US Veterans Affairs Medical Center. The study was approved by the Institutional Review Board at the Sacramento VA Medical Center, Veterans Affairs Northern California Health Care System (VACHCS) to report deidentified data.

## Study population and polyps

Retrospective analysis was performed on prospectively collected data of consecutive lesions removed by UCSR without SI from adult ( $\geq 18$  years old) patients presenting for scheduled routine colonoscopies from January 2016 to November 2020.

Patients excluded from this analysis were those recruited for enrollment in our unit's other prospective endoscopic clinical trials; patients on uninterrupted antithrombotic therapy, aside from low dose aspirin, at the time of their procedure; hospitalized patients; or patients with uncorrected coagulopathy (international normalization ratio  $> 1.5$ ) or thrombocytopenia (platelet count  $< 50,000/\mu\text{L}$ ).

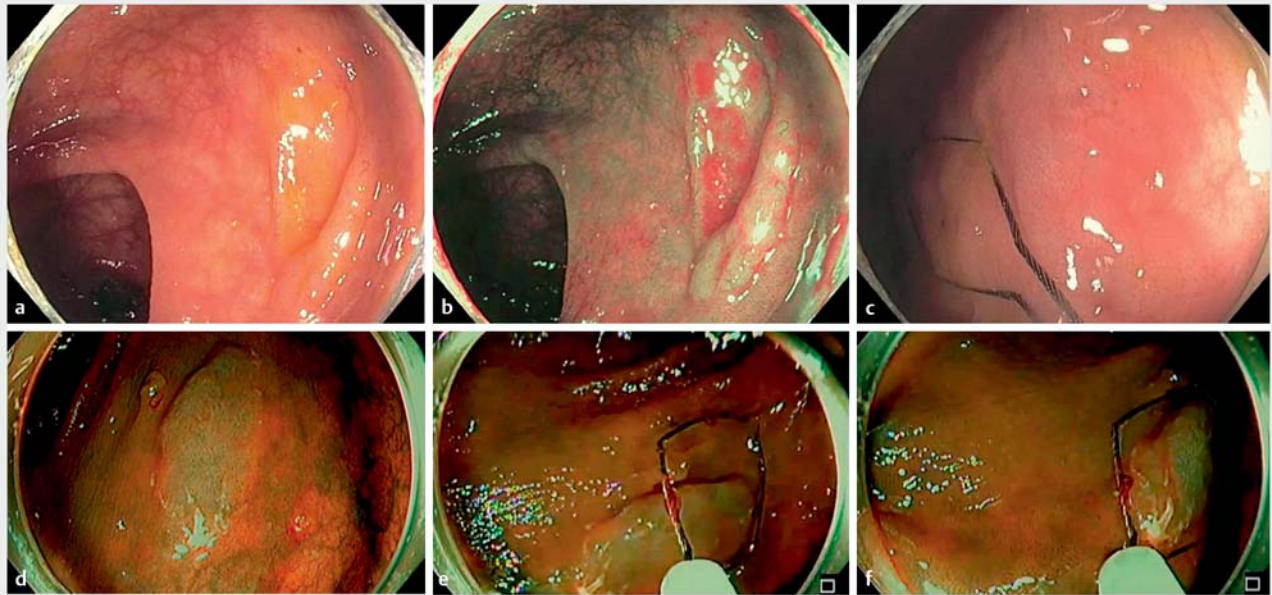
Eligible polyps were  $\geq 10$  mm in size. Polyps excluded from the analysis were lesions  $< 10$  mm; pedunculated lesions; and bulky lesions with  $> 5$ -mm elevation from the colon wall (with the tip of a 2.4-mm snare sheath as reference) where mechanical transection of tissue by cold techniques can be limited and where advanced imaging techniques cannot be applied to assess for advanced histology in the deeper portion of a polyp. As standard practice, lesions with endoscopic evidence of deep submucosal invasion (NICE type 3 [16]; Kudo pit pattern V [17]), were not endoscopically resected or included in this analysis. All polyps identified were photographed and their size, morphology and location were documented. Polyp sizes were assessed objectively in a gas-distended colon using a fully open snare of known dimensions for reference to gain the most accurate in situ estimate of lesion size (► Fig. 1). Morphology of polyps was recorded according to the Paris classification [18].

## Colonoscopy and instruments

All patients received split-dose bowel preparation with 4 liters of polyethylene glycol 3350 and electrolytes oral solution before colonoscopy. One experienced endoscopist (AWY) performed all procedures using high-definition colonoscopes (Olympus PCF-H 190L/I; Olympus America, Center Valley, Pennsylvania, United States) with a distal transparent cap attachment (Disposable Distal Attachment D-201-12704; Olympus America, Center Valley, Pennsylvania, United States). Patients were under moderate or no sedation for their examination. The technique of combined water exchange and cap-assisted colonoscopy [19] was performed for colonoscope insertion and the colon was fully distended with carbon dioxide for withdrawal inspection, evaluation and measurement of polyps.

## UCSR technique

For polyps removed by UCSR, gas was completely suctioned from the segment of bowel where the lesion was located and sterile water at room temperature was infused with a foot pedal-operated water pump for partial distention of the lumen. There was no limit to the amount of water infused to maintain visualization of the field. Water exchange, infusion of clear water and suctioning of turbid or bloody fluid, is emphasized to maintain a clear field. SI, as in traditional EMR, was not used. Endoscopic ultrasound and marking of the periphery of the lesion was not performed. Underwater views with or without nar-



► **Fig. 1** **a** Large sessile serrated lesion. **b** Narrow band imaging of lesion. **c** Polyp size assessed in a gas-distended colon with a fully open snare of known dimensions (9-mm diameter, 23-mm length). **d** Narrow band imaging of a separate sessile serrated lesion. **e** Polyp size assessed with a fully open snare. **f** Polyp size assessed with the long axis of the snare.

row band imaging helped enhance the visualization of lesion borders (► **Video 1**). Polyps were removed with a thin (0.3 mm) wire 9-mm diameter dedicated cold snare (Exacto Cold Snare; US Endoscopy, Mentor, Ohio, United States) or 10-mm diameter (0.3 mm thick) hybrid (hot/cold) snare (Olympus America; Center Valley, Pennsylvania, United States) at the discretion of the endoscopist. Electrocautery and SI were not used for any resection. Attempts were made to completely remove lesions en bloc (► **Fig. 2** and ► **Video 1**).

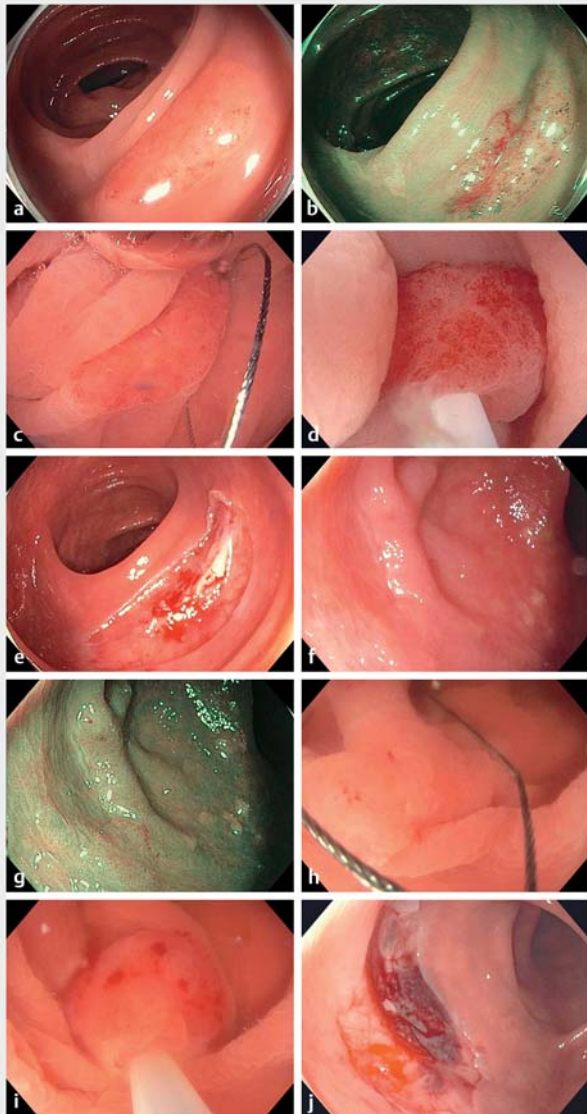
For UCSR, coordination with the assistant is important to ensure success of mechanical resection of lesions. A systematic approach is necessary and utilizing the long axis of the snare can assist with capturing lesions > 10 mm. After capturing a lesion underwater and ensuring a margin of  $\geq 1$  mm normal tissue, slow, controlled closure of the snare (over at least a 5 to 7 second count, particularly if the snare is full) reduces entrapment of deep submucosa and muscularis propria, which can hinder successful cold resection. It is important to keep the entire snare sheath/shaft as straight as possible throughout the cutting process to transmit a constant and consistent cutting force. This results in resection of the majority of lesions. If a lesion is not initially severed from the colon wall with these maneuvers, continuing to hold the snare handle completely closed with firm pressure for an additional period of at least 5 seconds will often result in completion of the resection. If a lesion still cannot be severed from the colon with these maneuvers, the snare and the entrapped polyp are gently drawn back into the instrument channel, with the snare handle still held closed, to create a shearing force that will often complete the polypectomy (► **Video 2**). If these maneuvers still do not successfully resect the lesion, it is often because of a captured thick, submu-

cosal cord, and as the snare and polyp are lifted away from the colon wall, the snare is opened slightly to release the base of the cord and reclosed without releasing the polyp, and the steps above repeated (► **Video 3**).

This approach allows resection of a rather generous surface area of mucosa (► **Fig. 2**), but some experience with this technique is still needed to recognize when too much volume is captured by the snare before the resection is initiated. A post-resection submucosal protrusion can be observed after resection [20].

Piecemeal resection was only utilized in this cohort for lesions that could not be removed en bloc by the above technique (► **Fig. 3** and ► **Video 4**). Although not needed in this series, availability of a hybrid snare has the advantage of allowing application of electrocautery without switching accessories or releasing the captured polyp in the event it is needed to complete the resection if cold snaring alone does not sever the lesion from the colon.

Resection was deemed complete once all macroscopic evidence of the polyp had been removed after careful inspection of the polypectomy base and margin in a water-filled lumen and then confirmed in a gas-distended colon. Water injected into the submucosa of the polypectomy base with the foot pedal-operated pump helped to further enhance evaluation of the border of the resection site. If any residual polyp was suspected, additional snare resection was performed underwater to ensure clearance of the site. Adjuvant thermal ablative techniques were not applied in this cohort. All polyps were collected and placed in separate jars for histopathologic assessment. No prophylactic clipping of post-polypectomy sites was performed.



► **Fig. 2** **a** 16-mm flat (0-IIa) tubular adenoma in a gas-distended colon. **b** Narrow band imaging of lesion. **c** Lesion underwater, appears more compact and floats into the collapsed lumen. **d** Ensnaring the lesion underwater with a thin wire snare. **e** En bloc post-polypectomy site in a gas-filled lumen. **f** Irregularly shaped 15-mm 0-IIa tubular adenoma in a gas-distended colon. **g** Narrow band imaging of lesion. **h** Lesion underwater, appears more compact and completely captured in the long axis of the snare. **i** Ensnaring the lesion underwater. **j** En bloc post-polypectomy site in a gas-filled lumen. (► **Video 3**).

## Outcome variables

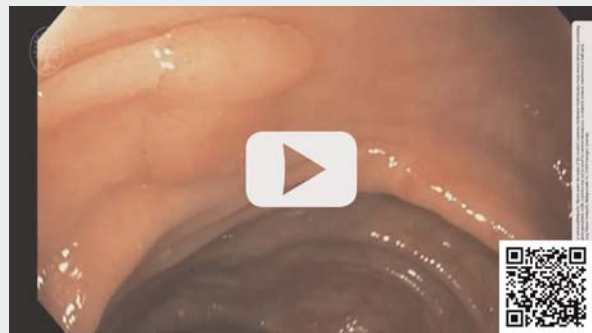The primary outcome measure was the en bloc resection rate based on endoscopic assessment. Secondary outcomes were immediate adverse event rates including perforation requiring intervention, including endoscopic closure or surgery; delayed bleeding within 30 days requiring blood transfusion and/or need for surgery, an interventional radiology procedure, or repeat colonoscopy; or other event requiring unexpected hospitalization.

## ► VIDEO



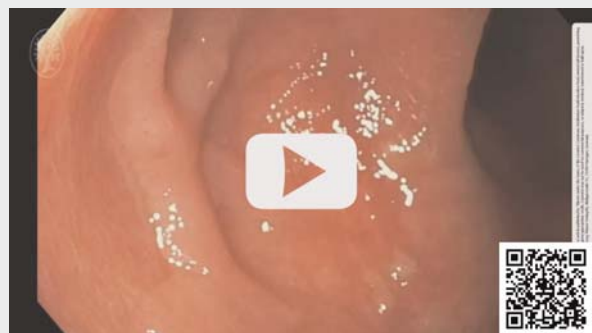► **Video 1** Underwater cold snare resection without submucosal injection of a 13 mm sessile serrated lesion.

## ► VIDEO



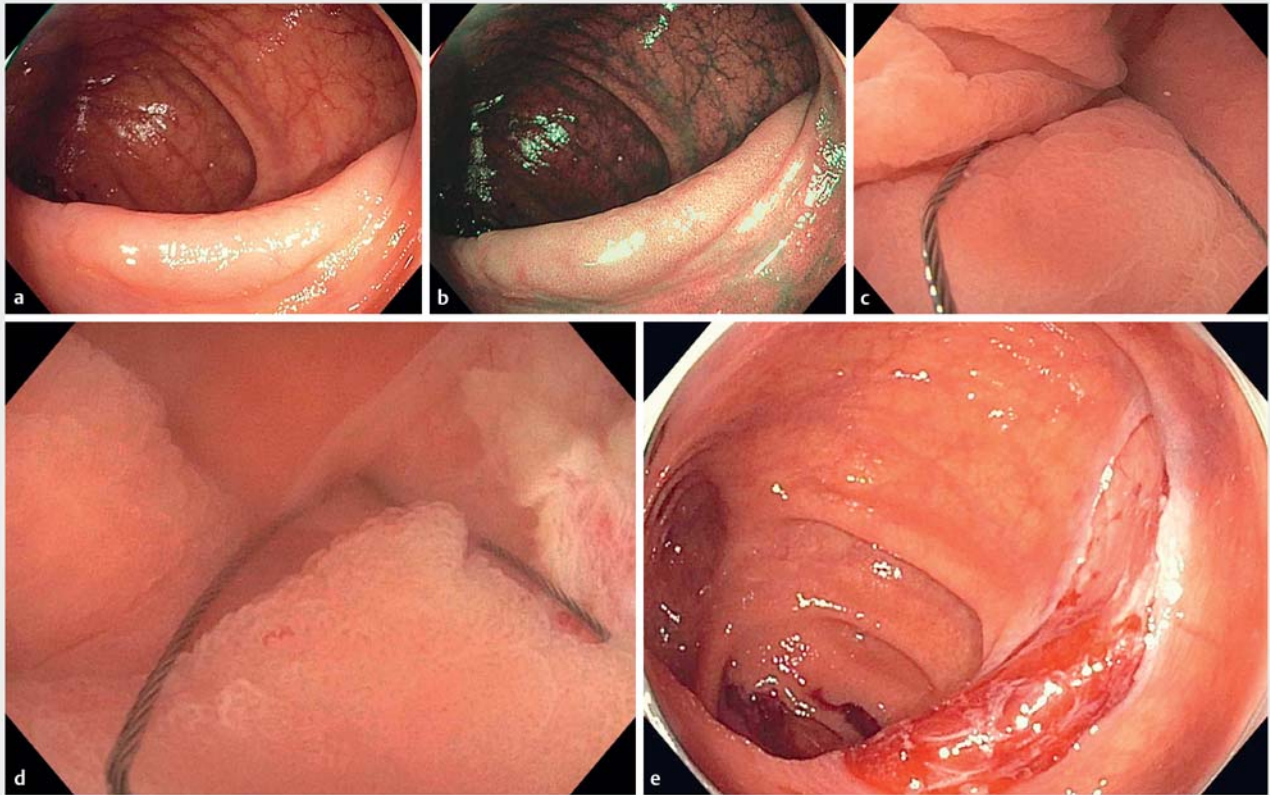
► **Video 2** Underwater cold snare resection with application of a shearing force to complete en bloc polypectomy.

## ► VIDEO



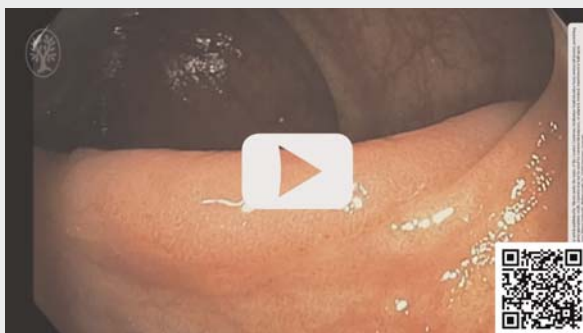► **Video 3** Underwater cold snare resection with application of a shearing force and release of a submucosal cord to complete en bloc polypectomy.

Immediate post-polypectomy bleeding (bleeding that did not stop on its own after 30 seconds and requiring endoscopic intervention) was also recorded.



► **Fig. 3** a 35-mm flat (0-IIa) tubular adenoma in a gas-distended colon straddling a haustral fold. b Narrow band imaging of lesion. c Lesion underwater, configuration is favorably altered in a collapsed lumen and more easily accessible for snare resection. d Piecemeal resection (4 snare resections total) underwater with a thin wire snare to completely remove lesion. e Post-polypectomy site in a gas-filled lumen (► **Video 4**).

► **VIDEO**



► **Video 4** Piecemeal underwater cold snare resection of a large tubular adenoma.

Patients received a routine post-procedure telephone call the following business day after their procedure to assess for post-procedure complications and electronic medical records were reviewed at the end of 30 days to evaluate for unexpected hospitalizations or treatment. Departmental notification of post-procedure hospitalizations outside of VANCHCS and

within 30 days of an endoscopic procedure was also routinely performed as part of standard care for the facility.

### Statistics

Descriptive statistics were used to report collected data. Categorical variables were evaluated by the Fisher exact test and differences between means were compared using one-way analysis of variance (ANOVA). Stepwise multiple logistic regression analysis, based on backward likelihood ratio test selection method, were used to obtain unadjusted and adjusted odds ratios (OR), 95% confidence intervals (CI), and *P* values for the association between en bloc resection and resection techniques. Nine variables, including age, sex, indication, body mass index, American Society of Anesthesiologists Classification, sedation method, polyp location, polyp size and polyp morphology were evaluated as potential confounders in the regression model.

### Results

In 44 patients, 53 lesions (mean size 15.8 mm [SD 6.9]) (range 10–35 mm) were removed by UCSR (► **Table 1**). The majority of lesions (62.3%) were tubular adenomas and most (45/53) were resected from the proximal colon. En bloc resection was successful in 84.9% (45/53), with all but one 10- to 19-mm lesion

**► Table 1** Patient demographics (n = 44) and characteristics of ≥ 10-mm non-pedunculated, non-bulky colorectal lesions (n = 53) removed by underwater cold snare resection

Number of patients, n	44	
Age (SD)	65.7 (8.9)	
M/F (%)	43/1 (97.7)	
Body mass index, kg/m <sup>2</sup> (SD)	29.3 (5.0)	
Antithrombotic use (%)	26/44 (59.1)	
▪ Aspirin	23/44 (52.3)	
▪ Other	3/44 (6.8)	
Procedure Indication (%)		
▪ Screening	15/44 (34.1)	
▪ Surveillance	16/44 (36.4)	
▪ Diagnostic	7/44 (15.9)	
▪ Therapeutic	4/44 (9.1)	
▪ Polypectomy follow up	2/44 (4.5)	
Sedation (%)		
▪ Moderate sedation	38/44 (86.4)	
▪ No sedation	6/44 (13.6)	
ASA classification (%)		
▪ II	22/44 (50)	
▪ III	22/44 (50)	
Bowel preparation quality (%)		
▪ Adequate (excellent or good)	44/44 (100)	
▪ Inadequate (fair or poor)	0/44 (0)	
Number of lesions, n	53	
Mean size [mm] (SD)	15.8 (6.9)	
Size range [mm]	10–35	
	10–19 mm	≥ 20 mm
Number of lesions, n	37	16
Proximal colon (%)	31/37 (83.8)	14/16 (87.5)
Tubular adenoma (%)	23 (62.2)	10 (62.5)
Sessile serrated lesion (%)	14 (37.8)	6 (37.5)
Morphology (Paris Classification)		
▪ 0-Is	12	1
▪ 0-IIa	23	11
▪ 0-IIb	2	4

SD, standard deviation; ASA, American Society of Anesthesiologists.

(97.3%; 36/37) removed with one snare resection. The remaining lesions required more than one snare resection for complete clearance.

Compared to a published historical cohort from a randomized controlled trial (RCT) of underwater hot snare without SI and conventional EMR – submucosal injection, lift and hot snare – by the author [3], UCSR outperformed conventional EMR for en bloc resection, particularly for lesions 10 to 19 mm in size (► **Table 2**), even though a larger (15-mm diameter) snare was used in the RCT. Recent published en bloc resection rates from the literature [21, 22] from groups comparing underwater and conventional resection techniques (also using larger snares than this cohort) are provided for additional reference in ► **Table 2**.

Results from the stepwise multiple logistic regression analysis indicated that en bloc resection was significantly associated with UCSR, compared to conventional EMR (adjusted OR = 3.47, 95% CI = 1.15–10.43, *P* = 0.027) adjusted for polyp size. In contrast, en bloc resection was not significantly associated with underwater hot snare without SI, compared to conventional EMR (adjusted OR = 1.32, 95% CI = 0.53–3.30, *P* = 0.550) adjusted for polyp size (► **Table 3**).

AEs with UCSR were not observed and there was one case of immediate bleeding after piecemeal resection of a 23-mm sessile serrated lesion in the cecum that was successfully managed by endoscopic intervention (clipping) for hemostasis.

Short-term endoscopic follow-up was not routinely performed for lesions in the 10- to 19-mm size range, but for patients with lesions ≥ 20 mm surveillance in 6 to 12 months was conducted as part of standard practice. In this series, 16 such lesions were removed from 15 patients. All but three patients returned for follow-up. One patient moved; another did not return after being diagnosed with a non-gastrointestinal cancer; and another with two lesions ≥ 20 mm declined follow-up. At first follow-up there was no evidence of residual/recurrent neoplasia in 9/12 (75%). In cases where residual neoplasia was identified, it was small and easily addressed endoscopically (► **Table 4**).

## Discussion

Our results confirm the success of simplifying the technique of underwater resection. We report the feasibility, safety and efficacy of UCSR without SI of ≥ 10 mm non-pedunculated, non-bulky, adenomatous and serrated class colorectal lesions. Using a 9- to 10-mm diameter dedicated thin (0.3-mm) wire cold or hybrid snare and a systematic approach, UCSR results in high en bloc resection rates with no observed AEs.

Polypectomy is effective in reducing the incidence and mortality of colorectal cancer [23], but the introduction of diathermy accounts for the majority of complications related to colonoscopy. Current guidelines [24, 25] support cold snaring for removal of small (< 10 mm) lesions because of the ease, efficacy and safety of this technique. Cold snaring larger lesions is attractive because of the safety profile but concerns about incomplete resection and inability to remove larger areas by mechanical resection have limited wider adoption. However, the notion that electrocautery reduces incomplete resection, even for small polyps, has been challenged [14], and additional factors such as ensuring a clear margin and reducing piecemeal re-

► **Table 2** Resection outcomes for ≥ 10-mm colorectal lesions removed by underwater cold snare (n=53) vs. historical cohort of underwater hot snare and conventional EMR with hot snare<sup>1</sup> and additional literature references

	Underwater cold snare without SI		Underwater hot snare without SI		Conventional EMR with hot snare		P value	Yamashina et al; Gastro 2019 (RCT 10–20 mm lesions) [21]		Cadoni et al; United Euro Gastroenterol J 2018 (Retrospective ≥ 10-mm sessile lesions) [22]	
	9–10	15	10–19 mm	≥ 20 mm	10–19 mm	≥ 20 mm		Underwater hot snare without SI	Conventional EMR with hot snare	Underwater hot snare without SI	Conventional EMR with hot snare
Diameter of snare used (mm)	9–10	15			15		–	10–26		variable – standard or large	
Number of lesions, n	53	68	10–19 mm	≥ 20 mm	50		–	108	102	81	77
Overall en bloc resection (%)	45 (84.9)	48 (70.6)	10–19 mm	≥ 20 mm	32 (64.0)		0.04 <sup>2</sup>	96 (89.0)	76 (75.0)	58 (71.6)	51 (66.2)
Number of lesions, n	37	52	10–19 mm	≥ 20 mm	10–19 mm	≥ 20 mm	10–19 mm	–	–	–	–
	16	16	52	16	34	16	–	–	–	–	–
En bloc resection (%)	36 (97.3)	44 (84.6)	4 (25.0)	4 (25.0)	25 (73.5)	7 (43.8)	0.01 <sup>2</sup>	–	–	–	–
Immediate bleeding (%)	0 (0)	2 (3.9)	3 (18.8)	2 (12.5)	1 (2.9)	2 (12.5)	0.62 <sup>2</sup>	–	–	10 (12.3)	11 (14.3)
Perforation (%)	0 (0)	0 (0)	0 (0)	0 (0)	0 (0)	0 (0)	–	0 (0)	0 (0)	0 (0)	0 (0)
Clipping [prophylactic] (%)	0 (0)	41 (78.6)	15 (93.8)	15 (93.8)	30 (88.2)	15 (93.8)	<0.001 <sup>2</sup>	76 (70.0)	59 (58.0)	–	–
Number of clips [for clipped lesions], n (SE)	0 (0)	2.41 (0.18)	4.07 (0.30)	4.07 (0.30)	3.00 (0.21)	4.33 (0.30)	<0.001 <sup>3</sup>	–	–	–	–
Submucosal injection (%)	0 (0)	0 (0)	0 (0)	0 (0)	34 (100)	16 (100)	<0.001 <sup>2</sup>	–	–	–	–

EMR, endoscopic mucosal resection (inject, lift, hot snare); RCT, randomized controlled trial; SI, submucosal injection; SE, standard error.

<sup>1</sup> Data from author's prior RCT [3].

<sup>2</sup> Fisher's exact test.

<sup>3</sup> ANOVA (one-way).

► **Table 3** Stepwise multiple logistic regression analysis of the association between en bloc resection and endoscopic resection techniques.

Variable	Odds ratio	95% confidence interval	P value
Endoscopic resection techniques			
Conventional EMR with hot snare	1.00	–	–
Underwater cold snare without SI	3.47	1.15–10.43	0.027
Underwater hot snare without SI	1.32	0.53–3.30	0.553
Polyp size (mm)	0.86	0.81–0.90	<0.001

Other variables evaluated in the multiple logistic regression models included age, sex, body mass index, American Society of Anesthesiologists classification, sedation (moderate versus no), polyp morphology (Paris classification), procedure indication (screening, surveillance, diagnostic, therapeutic), and polyp location. EMR, endoscopic mucosal resection; SI, submucosal injection. Nagelkerke  $R^2=0.36$

► **Table 4** Residual or recurrent neoplasia at first and second endoscopic follow up for lesions  $\geq 20$  mm in size.

Lesion size (mm)	Location	Pathology	En bloc resection	Residual/recurrent at first follow-up	Residual/recurrent at second follow-up
23	Cecum	SSL	(–)	(–)	n/a
21	Transverse	TA	(+)	Data unavailable	n/a
22	Descending	SSL	(+)	(–)	n/a
20	Transverse	TA	(+)	(–)	n/a
20	Descending	SSL	(+)	(–)	n/a
25	Ascending	TA	(–)	(+)	Pending follow up
35	Ascending	TA	(–)	(–)	n/a
27	Transverse	SSL	(+)	(–)	n/a
20	Transverse	TA	(+)	(–)	n/a
22	Ascending	SSL	(+)	(+)	(–)
30	Cecum	SSL	(–)	(–)	n/a
30	Cecum	TA	(–)	(+)	(–)
34	Cecum	TA	(–)	(–)	n/a
23	Ascending	TA	(+)	Data unavailable	n/a
30	Ascending	TA	(–)	Data unavailable	n/a
20	Transverse	TA	(+)	Data unavailable	n/a

SSL, sessile serrated lesion; TA, tubular adenoma; n/a, not applicable.

sections, may be equally, or possibly more important. Other factors, such as SI, may also play a role in completeness of resection. A recent RCT demonstrated lower complete resection rates related to the use of SI in cold snare resection of small lesions [26].

Evidence for cold resection of large serrated class lesions is accumulating [8–12], but experience for adenomas is limited. Adenomas may have more submucosal fibrosis and extension, which may make mechanical resection more difficult. Piecemeal resection of large serrated and adenomatous lesions by cold snare has been reported, but piecemeal resection also increases the frequency of residual neoplasia and achieving en

bloc resection was associated with lower incomplete resection rates [14]. Performing en bloc resection may be more challenging, however, for lesions  $\geq 10$  mm using small diameter (9–10 mm) snares optimized for cold snaring. These thin wire snares are firmer and have a stiffer sheath which can enhance cutting characteristics compared to standard snares; but drawbacks have been the need to resort to piecemeal resection when removing larger lesions, particularly if SI is utilized, as this further expands and enlarges lesions. The ability to fully capture a lesion and still be able to utilize the properties of a snare optimized for cold resection would be beneficial. Collapsing the colon lumen, “shrinking” a polyp and applying the



steps of UCSR in a systematic approach may help accomplish this.

Underwater resection of colorectal polyps has been reported by our group as a safe and effective alternative for removal of colorectal lesions in a RCT [3]. The technique has advantages compared to conventional resection [3], but underwater removal of lesions  $\geq 10$  mm is still generally accomplished with diathermy. UCSR possibly retains the advantages of underwater interventions but avoids electrocautery (example in Videos). Reductions in polyp size in a collapsed, water-filled lumen is crucial with this approach when capturing a lesion within a smaller snare. The importance of selecting appropriate lesions for resection with this technique and applying a systematic approach must be emphasized, however, as not all lesions should be removed by UCSR; but adhering to the standard principles outlined demonstrates the feasibility of this approach.

In our analysis, both adenomatous and serrated class lesions were successfully removed with UCSR while maintaining high en bloc resection rates for lesions up to 20 mm. Despite the small diameter snares in this study, en bloc resection rates for UCSR (84.9% overall [45/53]) remained high, particularly for 10- to 19-mm lesions (97.3% [36/37]). The overall en bloc resection rate was significantly higher compared to the author's historical cohort of lesions  $\geq 10$  mm removed by conventional EMR (64.0% [32/50]) [3], where SI and a 15-mm hot snare were used. En bloc resection remained significantly associated with UCSR compared to conventional EMR in the multiple logistic regression model. Compared to other groups experienced with underwater and conventional resection techniques, the en bloc resection rate of UCSR was also comparable or better than those reported in a recent multicenter RCT [21] and retrospective study [22]. In these trials, standard sized snares were used for resections.

The avoidance of SI with UCSR has cost advantages. The expenses related to the injection needle and injectate solution, and the additional time needed to perform this maneuver, often with piecemeal resection, are all reduced if SI is omitted. Our prior RCT demonstrated that compared to underwater resection, SI prior to polypectomy significantly increases the time to perform polypectomy for lesions  $\geq 10$  mm in size [3]. Additionally, because delayed bleeding is uncommon with cold resection, clip closure of polypectomy sites is unnecessary, resulting in further savings in time and resources.

Most colorectal lesions encountered in routine practice are  $< 10$  mm in size and can be resected safely and effectively by standard cold snaring. Easily, efficiently and inexpensively expanding the cold snaring armamentarium to larger lesions, namely those in the 10–19 mm size range, would allow endoscopists to resect the majority of lesions encountered routinely without the application of diathermy. Importantly, this would reduce complications related to thermal injury and may improve procedural efficiency and reduce resource utilization.

Similar to other cold resection techniques, AEs were infrequent for UCSR. Immediate bleeding was observed in one patient upon removal of a 23-mm cecal lesion and this was successfully managed endoscopically. Delayed bleeding is rare with cold resection and was not observed even without prophylactic clip closure of resection sites after UCSR.

Because AEs are uncommon with cold techniques, an added benefit is that endoscopists can be confident that they can secure a generous margin around polyps and/or extend resection sites to ensure clearance of neoplasia.

This study has limitations. It is a retrospective analysis of observational data from a US veteran population; a single endoscopist experienced with underwater resection performed all examinations; and the completeness of polyp resection was based on endoscopic assessment, so results may not be generalizable. Pathologic assessment for completeness of resections was limited by specimen fragmentation and standard pathology reporting at our site and routine short-term follow-up of resected polyps in the 10- to 19-mm size range is not performed. However, our prior RCT demonstrated that careful and systematic assessment of the margin and polypectomy site results in low rates of residual neoplasia based on sampling at the margins and at the first surveillance (for lesions  $\geq 20$  mm) [3], and the same approach for endoscopic margin assessment was utilized for this cohort. In future investigations, however, a more systematic approach to specimen retrieval and processing, such as immediate pinning and fixing for accurate sizing and pathologic assessment would be useful. Establishing a protocol for endoscopic follow-up to determine the outcome of residual/recurrent neoplasia would also be important.

In this analysis, the comparison with a historical cohort might be affected by biases from the differences in the demographic and clinical characteristics of the patients. However, we have included potential confounders using multiple logistic regression and adjusted for their effects. Because of the limitations in this small, retrospective study, the impact of findings requires further investigation and the practical and clinical effectiveness of UCSR will need to be explored in a RCT. As this is a novel technique, however, this pilot investigation provides important observations and insights regarding UCSR feasibility, outcomes and hypothesis generation and serves as a basis for planning larger, well designed prospective trials. A similar approach led by our group investigating underwater resection techniques beginning with a pilot observational study [27] led to a funded RCT [3]. Finally, conclusions regarding post-polypectomy complications from a cohort of this size should be interpreted with some caution.

## Conclusions

The novel application of UCSR shows promise as a simplified method that can assist endoscopists in the safe and efficient removal of intermediate and large sized adenomatous and serrated class colorectal lesions. UCSR is part of the continued evolution of underwater resection techniques that hold promise for the effective resection of colorectal neoplasia. Prospective RCTs are necessary to determine its full impacts. The cost and time savings of avoidance of SI, prophylactic clipping and utilization of multiple and/or larger snares may be an additional incentive to evaluate UCSR in practice. Expanding the polypectomy toolkit with an efficient, effective and simplified technique

with lower burden of risk and resources may motivate colonoscopists to incorporate UCSR into routine clinical care.

## Acknowledgments

This material is the result of work supported by resources from the VA Northern California Health Care System, Sacramento, California. The contents reported/presented within do not necessarily represent the views of the Department of Veterans Affairs or the United States Government.

## Competing interests

The authors declare that they have no conflict of interest.

## References

- [1] Li DF, Lai MG, Yang MF et al. The efficacy and safety of underwater endoscopic mucosal resection for 10 mm colorectal polyps: systematic review and meta-analysis *Endoscopy* 2021; 53: 636–646
- [2] Garg R, Singh A, Aggarwal M et al. Underwater endoscopic mucosal resection for 10 mm or larger nonpedunculated colorectal polyps: a systematic review and meta-analysis. *Clin Endosc* 2021; 54: 379–389
- [3] Yen AW, Leung JW, Wilson MD et al. Underwater versus conventional endoscopic resection of nondiminutive nonpedunculated colorectal lesions: a prospective randomized controlled trial (with video). *Gastrointest Endosc* 2020; 91: 643–654.e2
- [4] Kothari ST, Huang RJ, Shaikat A et al. ASGE Standards of Practice Committee Chair. ASGE review of adverse events in colonoscopy. *Gastrointest Endosc* 2019; 90: 863–876.e33
- [5] Paspatis GA, Tribonias G, Konstantinidis K et al. A prospective randomized comparison of cold vs hot snare polypectomy in the occurrence of postpolypectomy bleeding in small colonic polyps. *Colorectal Dis* 2011; 13: e345–348
- [6] Repici A, Hassan C, Vitetta E et al. Safety of cold polypectomy for < 10 mm polyps at colonoscopy: a prospective multicenter study. *Endoscopy* 2012; 44: 27–31
- [7] Horiuchi A, Nakayama Y, Kajiyama M et al. Removal of small colorectal polyps in anticoagulated patients: a prospective randomized comparison of cold snare and conventional polypectomy. *Gastrointest Endosc* 2014; 79: 417–423
- [8] Tutticci NJ, Hewett DG. Cold EMR of large sessile serrated polyps at colonoscopy (with video). *Gastrointest Endosc* 2018; 87: 837–842
- [9] Tate DJ, Awadie H, Bahin FF et al. Wide-field piecemeal cold snare polypectomy of large sessile serrated polyps without a submucosal injection is safe. *Endoscopy* 2018; 50: 248–252
- [10] van Hattem WA, Shahidi N, Vosko S et al. Piecemeal cold snare polypectomy versus conventional endoscopic mucosal resection for large sessile serrated lesions: a retrospective comparison across two successive periods. *Gut* 2021; 70: 1691–1697
- [11] Kimoto Y, Sakai E, Inamoto R et al. Safety and efficacy of cold snare polypectomy without submucosal injection for large sessile serrated lesions: a prospective study. *Clin Gastroenterol Hepatol* 2022; 20: e132–e138
- [12] McWhinney CD, Vemulapalli KC, El Rahyel A et al. Adverse events and residual lesion rate after cold endoscopic mucosal resection of serrated lesions  $\geq 10$  mm. *Gastrointest Endosc* 2021; 93: 654–659
- [13] Bettington M, Walker N, Rosty C et al. Clinicopathological and molecular features of sessile serrated adenomas with dysplasia or carcinoma. *Gut* 2017; 66: 97–106
- [14] Pohl H, Srivastava A, Bensen SP et al. Incomplete polyp resection during colonoscopy—results of the complete adenoma resection (CARE) study. *Gastroenterology* 2013; 144: 74–80.e1
- [15] Binmoeller KF, Hamerski CM, Shah JN et al. Attempted underwater en bloc resection for large (2–4 cm) colorectal laterally spreading tumors (with video). *Gastrointest Endosc* 2015; 81: 713–718
- [16] Hayashi N, Tanaka S, Hewett DG et al. Endoscopic prediction of deep submucosal invasive carcinoma: validation of the narrow-band imaging international colorectal endoscopic (NICE) classification. *Gastrointest Endosc* 2013; 78: 625–632
- [17] Kudo SE, Lambert R, Allen JI et al. Nonpolypoid neoplastic lesions of the colorectal mucosa. *Gastrointest Endosc* 2008; 68: S3–S47
- [18] Endoscopic Classification Review Group. Update on the Paris classification of superficial neoplastic lesions in the digestive tract. *Endoscopy* 2005; 37: 570–578
- [19] Yen AW, Leung JW, Leung FW. A novel method with significant impact on adenoma detection: combined water-exchange and cap-assisted colonoscopy. *Gastrointest Endosc* 2013; 77: 944–948
- [20] Tutticci N, Burgess NG, Pellise M et al. Characterization and significance of protrusions in the mucosal defect after cold snare polypectomy. *Gastrointest Endosc* 2015; 82: 523–528
- [21] Yamashina T, Uedo N, Akasaka T et al. Comparison of underwater vs conventional endoscopic mucosal resection of intermediate-size colorectal polyps. *Gastroenterology* 2019; 157: 451–461.e2
- [22] Cadoni S, Liggi M, Gallittu P et al. Underwater endoscopic colorectal polyp resection: Feasibility in everyday clinical practice. *United European Gastroenterol J* 2018; 6: 454–462
- [23] Zauber AG, Winawer SJ, O'Brien MJ et al. Colonoscopic polypectomy and long-term prevention of colorectal-cancer deaths. *N Engl J Med* 2012; 366: 687–696
- [24] Kaltenbach T, Anderson JC, Burke CA et al. Endoscopic removal of colorectal lesions—recommendations by the US Multi-Society Task Force on colorectal cancer. *Gastroenterology* 2020; 158: 1095–1129
- [25] Ferlitsch M, Moss A, Hassan C et al. Colorectal polypectomy and endoscopic mucosal resection (EMR): European Society of Gastrointestinal Endoscopy (ESGE) Clinical Guideline. *Endoscopy* 2017; 49: 270–297
- [26] Shimodate Y, Itakura J, Takayama H et al. Impact of submucosal saline solution injection for cold snare polypectomy of small colorectal polyps: a randomized controlled study. *Gastrointest Endosc* 2020; 92: 715–722.e1
- [27] Yen AW, Amato A, Cadoni S et al. Underwater polypectomy without submucosal injection for colorectal lesions  $\leq 20$  mm in size—a multicenter retrospective observational study. *Surg Endosc* 2019; 33: 2267–2273