

Intra-sphincteric botulinum toxin in the management of functional biliary pain



Authors

Shyam Menon^{1,2}, Andrew Holt², Adam D. Farmer^{3,4,5}

Institutions

- 1 The Royal Wolverhampton NHS Trust, Wolverhampton, UK
- 2 University Hospitals Birmingham NHS Foundation Trust, Birmingham, UK
- 3 Neurogastroenterology Group, Blizard Institute of Cell & Molecular Science, Wingate Institute of Neurogastroenterology, Barts & the London School of Medicine & Dentistry, Queen Mary University of London, London, UK
- 4 University of Keele, Keele, UK
- 5 Department of Gastroenterology, University Hospitals North Midlands, Stoke on Trent, UK

submitted 4.8.2021

accepted after revision 15.11.2021

Bibliography

Endosc Int Open 2022; 10: E521–E527

DOI 10.1055/a-1784-0061

ISSN 2364-3722

© 2022. The Author(s).

This is an open access article published by Thieme under the terms of the Creative Commons Attribution-NonDerivative-NonCommercial License, permitting copying and reproduction so long as the original work is given appropriate credit. Contents may not be used for commercial purposes, or adapted, remixed, transformed or built upon. (<https://creativecommons.org/licenses/by-nc-nd/4.0/>)

Georg Thieme Verlag KG, Rüdigerstraße 14,
70469 Stuttgart, Germany

Corresponding author

Dr. S. Menon, Department of Gastroenterology, The Royal Wolverhampton NHS Trust, New Cross Hospital, Wednesfield Road, Wolverhampton WV10 0QP, UK, UK

Fax: +441902695738

shyam.menon@nhs.net

ABSTRACT

Background and study aims The management of functional biliary-type pain remains a clinical challenge. Intra sphincteric botulinum toxin putatively exerts an anti-spasmodic and anti-nociceptive effect. The objective of this study was to examine the clinical response to intra sphincteric botulinum toxin in patients with functional biliary-type pain.

Patients and methods This was a cross-sectional (hypothesis-generating) study of prospectively collected data from patients referred to a tertiary center from 2014 to 2019. The efficacy of ampullary botulinum toxin injection for relief of pain was recorded at post-procedure outpatient review. Opioid analgesia, neuromodulatory medication, and frequency of hospital admissions were recorded.

Results A total of 119 consecutive patients (109 women, 10 men, mean age 45 years; range 17–77) underwent 411 intra-sphincteric botulinum toxin injection procedures (mean 2 procedures; range 1–15). A total of 103 patients (87%) had a significant improvement in pain on post-procedure review and 77% and 76% of patients were opioid and admission free, respectively. Of the patients, 59% were prescribed tricyclic antidepressants (amitriptyline), 18% duloxetine, 13% pregabalin, and 3% mirtazapine. Loss of response with the initial dose of botulinum toxin occurred in 56% of patients. Pain control was reestablished in 80% of patients in this cohort following botulinum toxin injection at a higher dose.

Conclusions These data suggest that botulinum toxin may improve outcomes in patients with functional biliary pain. Further controlled studies are needed to clarify the role of Botox and neuromodulatory agents.

Introduction

Dysfunction within the bidirectional communication between the enteric nervous system and the central nervous system is considered to play an important role in the genesis and maintenance of symptoms in chronic visceral pain disorders [1]. Although such disorders are often considered functional in na-

ture, contemporaneous nomenclature refers to these as a disorder of gut brain interaction (DGBI) [2]. Among the most incompletely understood of the DGBI are the gallbladder and sphincter of Oddi disorders (SOD) [3].

The Rome criteria define typical biliary pain as a sense of discomfort located in the epigastrium and/or right upper quadrant associated with other features such as gradual onset,

which occurs at different intervals and is severe enough to interrupt daily activity [4]. Frequently, this pain can radiate into the back and/or the right infra-scapular area and be associated with nausea and vomiting. Aspects that distinguish biliary pain from other types of abdominal pain include symptoms of pain not being significantly associated with bowel movements, postural change, or acid suppression. The Rome IV process has sought to make the distinction between functional gallbladder disorder, functional pancreatic SOD, and functional biliary SOD [4].

The management of functional pancreaticobiliary pain is challenging. Although the term SOD was developed nearly three decades ago to associate a mechanistic cause for this pain syndrome, its treatment remains controversial. Based on the modified Milwaukee classification, SOD was classified into three categories (SOD Types I-III) with endoscopic sphincterotomy (ES) without biliary manometry as the treatment for Type I SOD and manometry guided sphincterotomy as the therapy for Types II and III SOD [5–7]. However, the landmark Evaluating Predictors and Interventions in Sphincter of Oddi Dysfunction (EPISOD) study demonstrated that ES was no better than sham treatment in the management of Type III SOD [8]. The term “functional biliary pain” was felt to be a better descriptor for Type III SOD, with Type II SOD described as “functional biliary sphincter disorder” [4]. Type I SOD is now regarded to be a fibrostenotic process associated with the SOD and has a very good response to ES without the need for biliary manometry [4, 9].

Therapeutic options for true functional biliary pain or Type III SOD remain limited. Neuromodulatory therapy with amitriptyline and duloxetine, among other agents have shown encouraging results but a significant proportion of patients with functional biliary pain remain symptomatic despite these therapies [4, 10, 11].

Botulinum toxin A, a toxin produced by *Clostridium botulinum*, causes paralysis of skeletal muscle by inhibiting acetylcholine release from nerve endings, and this property has been used to treat spastic disorders of gastrointestinal smooth muscles, as in achalasia cardia [12, 13]. Botulinum toxin (Botox) may alleviate spasm of the SOD but there are data to suggest that it may exert antinociceptive effects as well [14–16].

Intra-sphincteric botulinum toxin A injection (Botox) into the sphincter of Oddi was originally performed by Pasricha [17] in two patients with post-cholecystectomy pain syndrome in 1994 who subsequently underwent biliary manometry and biliary scintigraphy. Botox injection reduced the sphincter of Oddi pressure by 50% in one patient and improved bile flow in the other. One patient reported a transient improvement in pain post Botox injection for up to 2 months although the other patient did not experience any improvement in pain. Neither patient had any symptomatic relief following ES. Subsequent studies have suggested a correlation between the response to Botox injection and efficacy of ES [18–22]. A recent meta-analysis of studies involving intra-sphincteric Botox injection for the treatment of SOD suggested a pooled efficacy of Botox injection of 49% in completely alleviating SOD-associated pain and a partial improvement of 64% [23]. These results, albeit transi-

ent, could potentially offer a framework for management of patients with functional biliary pain, with a study suggesting that repetitive Botox injections can be associated with prolonged symptom control [24].

We performed a cross-sectional (hypothesis-generating) study of prospectively collected data patients referred to a tertiary center from 2014 to 2019. Our aim was to report our clinical experience of intra-sphincteric Botox injections in the management of functional biliary pain.

Patients and methods

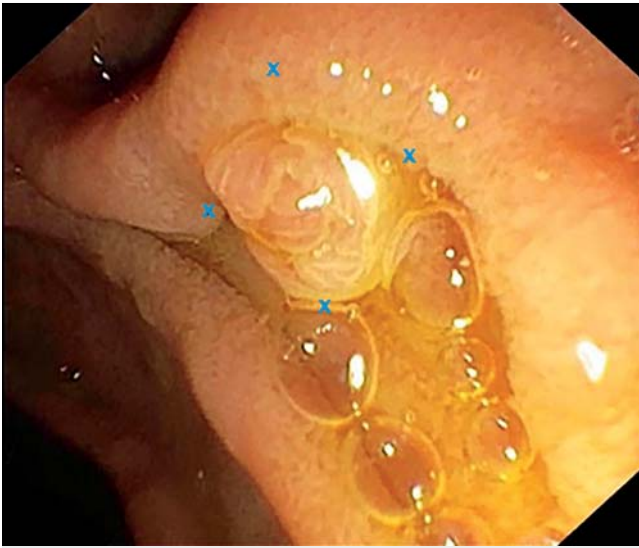A retrospective review of prospectively collected data over a 5-year period (2014–2019) was performed. The data that were extracted were anonymized and the necessary approval for undertaking this review was obtained from the Gastroenterology Directorate at The Royal Wolverhampton NHS Trust, UK.

Patient cohort

The diagnosis of functional biliary pain was made in post-cholecystectomy patients with abdominal pain identical to their pre-cholecystectomy pain, fulfilling the Rome IV criteria [4]. All patients underwent extensive investigations including blood tests (full blood count, liver function tests, renal function tests, thyroid function tests, coeliac serology), esophagogastroduodenoscopy (EGD), transabdominal ultrasonography, cross-sectional imaging (with either magnetic resonance cholangiopancreatography or computed tomography), and endoscopic ultrasound. Patients with typical pre-cholecystectomy pain, normal duct size, and normal liver function tests were identified as having functional biliary pain, according to the Rome IV criteria. All patients had severe or very severe symptoms of pancreaticobiliary pain and had multiple and recent Emergency Department (ED) visits or hospital admissions. We did not utilize a formal verbal rating scale threshold for recruitment. Patients post-biliary sphincterotomy were excluded from this cohort owing to the likelihood that these patients may have had functional biliary sphincter disease (SOD II).

Intra-sphincteric botulinum toxin injection procedure

Intra-sphincteric Botox injection (Botulinum toxin Type A, Allergan, UK), was performed under deep sedation or general anesthesia using a duodenoscope, in a quadrantic fashion across the ampullary face (► **Fig. 1**). Botox was reconstituted to a volume of 4 mL with 0.9% saline and the injection technique was similar to the sub-mucosal lift technique used for conventional polypectomy. The major papilla was identified and 1 mL of Botox was injected quadratically into the outer aspect of the papillary muscular complex. This was performed to achieve two aims. First, to achieve circumferential coverage of the papillary muscle and second, to allow the Botox to be delivered to the duodenal wall beyond the major papilla and potentially facilitate a regional “pain block.” Care was taken to avoid the biliary and pancreatic orifices with the needle-tip directed into the muscle complex and away from the biliary and pancreatic ostia. The rationale for the submucosal lift technique to deliver.



► **Fig. 1** Image of major papilla with the points of Botox injection marked as "x."

Botox was that a deeper injection could potentially deliver Botox into the retroperitoneum due to the thin nature of the duodenal wall and to allow Botox to be delivered around the major papilla. Post-procedure, patients were monitored in the endoscopy department for 3 hours. Intravenous fluids or rectal nonsteroidal anti-inflammatory drugs were not administered.

Patient outcome measures

The effect of intra-sphincteric Botox injection was recorded at an outpatient review around 6 weeks following the procedure. During the consultation, each patient was asked if the severity and frequency of attacks of their biliary pain had completely improved, partially improved, were exactly the same as before or had become worse following the procedure, as a simplified version of a verbal intensity pain scale [25]. Opioid analgesia and frequency of hospital admissions were noted, in addition to neuromodulatory medication used. Opioid doses were calculated as morphine equivalents for statistical analysis. Patients were followed up subsequently every 3 to 4 months as outpatients and during each outpatient review, a qualitative evaluation of their symptomatology was performed by asking patients whether their episodes of pain had completely improved, partially improved or were exactly the same pre-Botox or worse. Additional Botox sessions were discussed and planned, depending on each patient's symptoms. A minimum of 12 months of outpatient follow-up data were included.

Data synthesis and statistical analysis

Results of quantitative data are presented as means \pm standard deviations or a median and interquartile range (IQR), dependent on data distribution as determined by Shapiro Wilk testing. Categorical data were summarized as the percentage of the group total. Given the hypothesis-generating nature of the study, imputational analyses were not undertaken. All analyses

were performed using proprietary software (SPSS, Version 19.0, Chicago, Illinois, United States).

Results

Patient cohort

One hundred and nineteen patients (109 females [92%], 10 males, mean age 45 years; range 17–77) were identified. These patients underwent 411 intra-sphincteric Botox injection procedures (mean 2 procedures; range 1–15) over the 5-year study period. The median dose of Botox used was 200 units; range 100–600. Seventy-nine patients (66%) had severe episodes of pancreaticobiliary pain and 40 patients had very severe episodes of pain at the time of recruitment. Of these patients, 43% were on regular opioids to control their symptoms of abdominal pain, while 55% used opioids intermittently.

Outcomes of intra-sphincteric botulinum toxin injection

Following intra-sphincteric Botox injection, 103 patients (87%) had an improvement in pain on post-procedure review with 79 patients (77%) discontinuing opioids post-procedure. Ninety-one patients (76%) did not need to go to the Emergency Department (ED) or be admitted to the hospital due to severe biliary pain. The severity of attacks of pancreaticobiliary pain and the frequency of the episodes significantly improved (very severe or severe pain to no pain) in 77 patients (75%), with 26 patients reporting partial improvement of symptoms (very severe or severe pain to mild/moderate pain) at review. Symptoms were exactly as before or worse post-procedure in 16 patients (13%). Although there was a transient exacerbation of pain lasting for 24 to 48 hours in over 90% of patients, there were no procedure-related complications in the group. None of the patients experiencing post-procedure pain needed to go to the ED or be hospitalized.

Neuromodulatory drugs

Seventy patients (59%) in the cohort were prescribed tricyclic antidepressants (amitriptyline median dose 10mg; range 10–50 mg); 21 patients (18%) duloxetine, a selective serotonin and norepinephrine reuptake inhibitor (SNRI) (median dose 30mg; range 30–120 mg); 15 patients (13%) pregabalin (median dose 100 mg; range 50–300 mg); and three patients (3%) mirtazapine, a noradrenergic and specific serotonergic antidepressant (median dose 15 mg; range 15–45 mg) to manage their chronic pain. Neuromodulatory therapy was initiated in 62 patients (89%) during their post-procedure outpatient review while the remaining patients were already on neuromodulatory therapy at the time of their Botox injection and the dose of medication was augmented, if tolerable at outpatient review. Combination therapy was used in 21 patients (17.6%). Duloxetine 30mg was used in conjunction with pregabalin 50mg in 18 patients, amitriptyline 10mg/duloxetine 30mg in two patients, and amitriptyline/pregabalin 50mg in one patient. Forty-nine of the cohort (41%) were not on neuromodulatory therapy, and in this cohort, 34 patients had a complete

response to Botox injection while the rest had a partial response.

Opioid use

One hundred and five patients (88%) in the cohort were on opioid medication (morphine sulfate [oral solution and extended-release tablets/capsules], oxycodone, tramadol and codeine) regularly (43%) or intermittently (55%) for symptoms. Oxycodone, tramadol, and codeine doses were converted to morphine equivalent doses. The mean pre-Botox opioid dose used by patients was 59.8 mg of morphine equivalents per day. Following intermittent Botox injection therapy, 79 patients (77%) stopped opioid therapy altogether and mean opioid doses were reduced to 36.3 mg per day ($\chi^2 P < 0.001$) in the rest of the cohort.

Longer-term outcomes

A relapse of biliary pain following the initial injection of Botox occurred in 67 patients (56%) at a median of 3 months (range 1–24 months). Patients underwent a further Botox injection at the same dose of Botox (if the previous or index response was a complete response) or higher dose of Botox (if the previous or index response was a partial response), with pain control re-established in 80% of patients in this cohort. Non-responders to a higher dose of Botox were managed with neuromodulatory therapy and pain management, generally with opioids. Neuro-modulatory therapy, if tolerable, was continued in all patients who responded to Botox injection.

Patients were followed up for a mean of 19 months (range 12–56). At 12-month follow-up, 101 patients (85%) reported durable pain relief (ongoing complete or partial response) with the remainder of the patients managing their symptoms with pain management support.

Discussion

This study provides preliminary evidence that intra-sphincteric Botox injection, coupled with the use of neuromodulatory agents, is useful in managing functional biliary pain. Such a strategy also reduces opioid use, ED visits, and hospital admissions. Nevertheless, approximately half of patients will experience a relapse in symptoms necessitating further intra-sphincteric Botox injection and use of neuromodulatory agents.

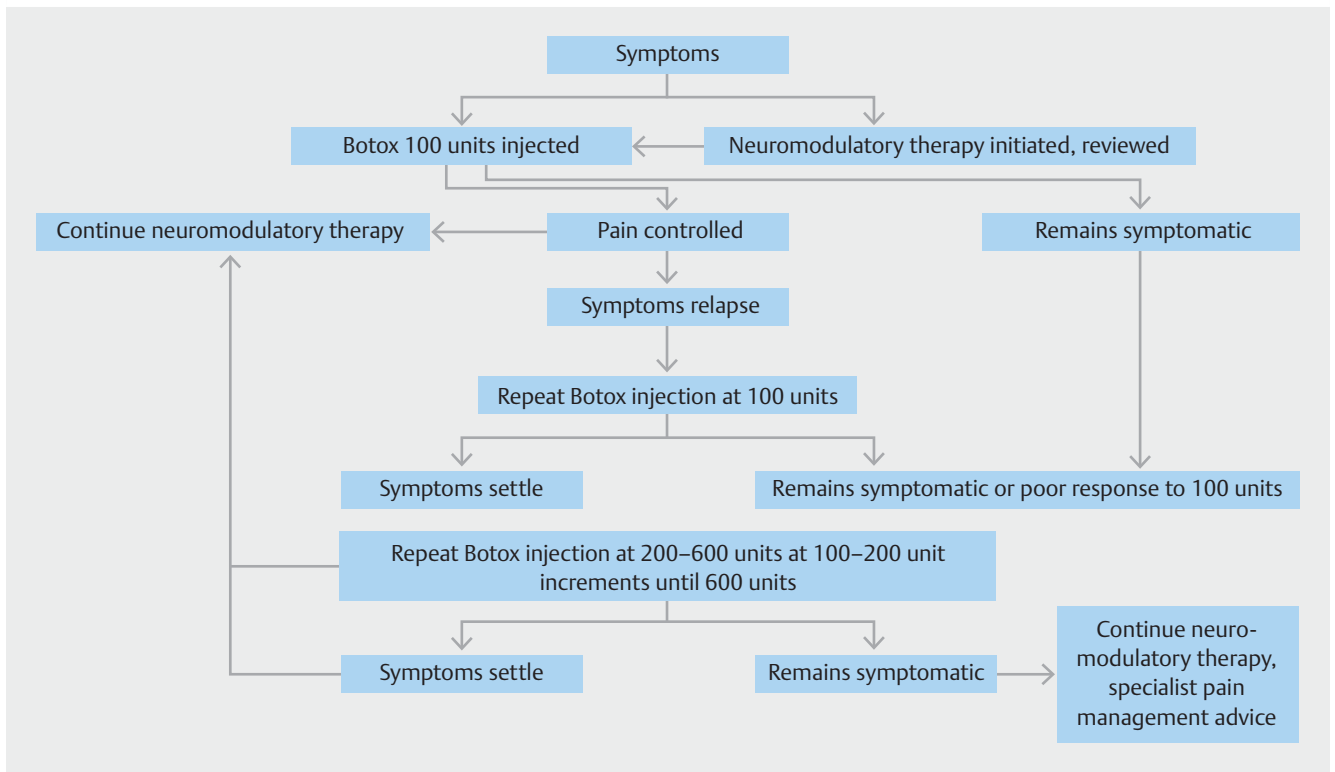
There is accumulating evidence that cholecystectomy alters the dynamics of the sphincter of Oddi in animal studies by damaging pericholedochal nerves and impairing a cholecysto-sphincteric reflex that facilitates sphincter of Oddi relaxation in conjunction with gallbladder distension [26]. The inhibition and/or loss of such a reflex may impair the response of the sphincter of Oddi to cholecystokinin activity [27] while increased biliary pressures (spasm) have been noted following intramuscular morphine injection in post-cholecystectomy patients compared to patients with intact gallbladders where there was no increase in intra biliary pressure [28], thus suggesting changes in biliary and sphincter of Oddi dynamics in the post-cholecystectomy state exposed by the loss of the gallbladder reservoir; in the natural state the gallbladder might

provide a “safety valve” by dispersing the rise in intra-ductal pressures associated with sphincter dysfunction [28, 29].

As the EPISOD trial has demonstrated, simplistic explanations ascribing biliary pain solely to sphincter of Oddi spasm are incorrect [8]. Biliary pain is likely to reflect a regional pain syndrome focused on the sphincter of Oddi region caused by nociceptive sensitization of the bilio-pancreatic area following an inflammatory process in the gallbladder, that usually settles in the majority of patients following cholecystectomy but can be amplified in individuals with biliary SOD into a severe functional pain syndrome characterized by nociceptive stimulation, hypersensitivity and allodynia [4, 30, 31]. Cross-sensitization of adjacent pain pathways may amplify pain into a wider area of perception as pancreatic and duodenal pain pathways are inter-linked [30, 31], as demonstrated in a study in which duodenal and not rectal barostat inflation reproduced biliary pain in patients with SOD [32]. Another study demonstrated that patients with post-cholecystectomy biliary pain had somatosensory hyperalgesia compared to controls, corroborating the hypothesis that a local inflammatory or sensitizing process in the post-cholecystectomy state could lead to hypersensitivity of the peripheral nociceptive nerve fibers in patients with SOD [26]. Functional biliary pain due to Type III SOD is likely to therefore represent a regional pain syndrome with the epicenter of the pain zone at the sphincter of Oddi. It is plausible that this pain zone is much more localized around the sphincter of Oddi, with associated spasm of the sphincter of Oddi in Type II SOD as opposed to a wider pain zone in Type III SOD without a spasm-associated issue of the sphincter of Oddi. This hypothesis may explain the lack of response to ES in Type III SOD, making it a “true” functional abdominal pain.

The lack of therapeutic options in patients with functional biliary pain makes the management of these patients challenging, as many patients are debilitated with pain, with significant impairment to the quality of their lives, dependence on opioids and recurrent hospital admissions. Botox injection into the sphincter of Oddi has been demonstrated to cause a reduction in sphincter of Oddi resting pressures and may exert an antinociceptive effect [17, 33, 34]. Intra-sphincteric botulinum toxin injection into the sphincter of Oddi has been demonstrated to be of short-term clinical benefit in reducing pain in a number of studies [19, 24, 34–36]. It therefore seems reasonable to assume that this technique could be an effective management strategy in patients with functional biliary pain/Type III SOD, particularly as the technique is relatively simple to perform, does not require specialist equipment and is only associated with rates of pancreatitis of < 1% [23].

We found that 87% of patients had a positive response to Botox injection with improvement in pain, and of these patients, 75% had a complete response with cessation of pain. Although the effect of Botox was transient, with a median time for relapse of symptoms of 3 months, re-treatment with Botox was successful in alleviating pain. We additionally found that Botox injection at higher doses led to improvement in pain in patients who lost response to Botox or in whom the response was initially a partial improvement of pain. We sought to start and continue or augment neuromodulatory therapy, if toler-



► **Fig. 2** Flowchart summarizing the clinical pathway for management of functional biliary pain/Type III SOD patients.

ated, in all patients working on the possibility that ongoing neuromodulatory therapy could potentially prolong the efficacy derived from Botox injection.

The initial dose of Botox used in our patient cohort was 100 units. There are no data in the literature on the effect of Botox at higher strengths. We found that not only did incremental doses of Botox (at 100-unit increments) reestablish pain relief in 80% of patients who had lost efficacy to Botox, there were no side effects to injections at higher doses. The repetitive and incremental use of Botox as part of a therapeutic strategy including neuromodulatory therapy is a novel management pathway that allows control of symptoms in most patients (► **Fig. 2**).

Wehrmann studied 22 patients with manometrically confirmed Type III SOD who had 100 units of Botox injected into the major papilla [19]. Six weeks after Botox injection, 12 (55%) of patients were symptom free. Of the patients who did not respond to Botox injection, 50% had normalization of sphincter of Oddi pressures and these patients did not respond to ES. Eleven of the 12 patients who had a positive response to Botox had a relapse of pain at a median of 6 months and all patients had increased sphincter of Oddi pressures at manometry with a positive and durable subsequent response to ES. It is possible that a proportion of these patients had functional biliary sphincter disease; hence the response to ES, but as the study illustrates, the response to Botox may be independent of basal sphincter of Oddi pressures. This was corroborated by the EPISOD study in which manometry results were not associated with the clinical outcomes [8], raising the possibility that sphincter of Oddi spasm could be part of the pain syndrome in

patients with Type III SOD/functional biliary pain and not the sole cause for symptoms.

There is some concern that repetitive Botox injections can potentially cause fibrosis of the sphincter of Oddi [37]. Porcine studies on Botox injection to the lower esophageal sphincter (LES) as management for achalasia cardia have suggested that endoscopic pre-treatment can cause inflammation and fibrosis of the LES [38]. However, most clinical studies have demonstrated that Botox injection does not affect esophageal muscle histology or patient outcomes in patients undergoing myotomy [37, 39, 40]. Further studies are necessary to understand the effect of multiple Botox injections to the sphincter of Oddi.

This study is not without significant limitations. First, the observational nature of our study design is a critical methodological issue, which has limited us to reporting outcomes rather than any causal effects. Second, details on opioid dosages used during acute hospital admissions and emergency attendances were limited, particularly as many of our patients were referred from other hospitals. Third, it is entirely plausible to suggest that there is a significant placebo effect to Botox injection. Placebo responses have been studied extensively in chronic pain syndromes and specifically in irritable bowel syndrome (IBS) and functional dyspepsia [41]. Despite the wide range of placebo responses (3–84%) in IBS, Enck [42] suggested that the true placebo effect of treatments in functional abdominal pain is likely to be around 40%. A therapeutic response of >80% would suggest that the effect of Botox is greater than what one would expect with a placebo and is therefore possibly a true response. As the majority of the patient cohort were started on neuromodulatory

dulatory therapy following Botox injection, it is also plausible that the clinical response was more likely to be related to a combination of Botox and neuromodulatory therapy. However, 49 (41%) of patients were not on neuromodulatory therapy, and in this cohort, all patients derived either a complete or partial response to Botox injection with ongoing durable response to a strategy of intermittent Botox injections depending on symptoms, suggesting a possible true effect of Botox therapy. Finally, we have not been able to compare this group of patients with a control group simply because our practice of offering endoscopic biliary sphincterotomy for Type III SOD/functional biliary pain ceased following the EPISOD trial and we resorted to managing this cohort using a combination of Botox injections and neuromodulatory therapy. A well designed randomized, sham-controlled trial, therefore, will be necessary to distinguish the true effect of Botox injection from any placebo response.

Conclusions

We have demonstrated a potential clinical strategy for patients with functional biliary pain which may allow some control of a debilitating condition for these individuals. We would propose a randomized study to fully understand the clinical efficacy of this strategy but are aware that recruitment into a potential future sham-controlled trial may not be simple.

Competing interests

The authors declare that they have no conflict of interest.

References

- [1] Farmer AD, Aziz Q. Visceral pain hypersensitivity in functional gastrointestinal disorders. *Brit Med Bull* 2009; 91: 123–136
- [2] Drossman DA, Hasler WL. Rome IV-functional GI disorders: Disorders of gut-brain interaction. *Gastroenterology* 2016; 150: 1257–1261
- [3] Afghani E, Lo SK, Covington PS et al. Sphincter of Oddi Function and risk factors for dysfunction. *Front Nutr* 2017; 4: 1
- [4] Cotton PB, Elta GH, Carter R et al. Gallbladder and sphincter of Oddi disorders. *Gastroenterology* 2016; 150: 1420–1429
- [5] Hogan WJ, Geenan JE. Biliary dyskinesia. *Endoscopy* 1988; 20: 179–183
- [6] Behar J, Corazziari E, Guelrud M et al. Functional gallbladder and sphincter of oddi disorders. *Gastroenterology* 2006; 130: 1498–1509
- [7] Geenan JE, Hogan WJ, Dodds WJ et al. The efficacy of endoscopic sphincterotomy after cholecystectomy in patients with sphincter-of-Oddi dysfunction. *N Engl J Med* 1989; 320: 82–87
- [8] Cotton PB, Durkalski V, Romagnuolo J et al. Effect of endoscopic sphincterotomy for suspected sphincter of Oddi dysfunction on pain-related disability following cholecystectomy: the EPISOD randomized clinical trial. *JAMA* 2014; 311: 2101–2109
- [9] Baillie J. Sphincter of Oddi dysfunction: Overdue for an overhaul. *Am J Gastroenterol* 2005; 100: 1217–1220
- [10] Tornblom H, Drossman DA. Centrally targeted pharmacotherapy for chronic abdominal pain. *Neurogastroenterol Motil* 2015; 27: 455–467
- [11] Pauls Q, Durkalski-Mauldin V, Brawman-Mintzer O et al. Duloxetine for the treatment of patients with suspected sphincter of Oddi dysfunction: A pilot study. *Digest Dis Sci* 2016; 61: 2704–2709
- [12] Simpson LL. The origin, structure, and pharmacological activity of botulinum toxin. *Pharmacol Rev* 1981; 33: 155–188
- [13] Pasricha PJ, Ravich WJ, Kalloo AN. Botulinum toxin for achalasia. *Lancet* 1993; 341: 244–245
- [14] Singh J. Use of botulinum toxin in musculoskeletal pain. *F1000Res* 2013; 2: 1–22
- [15] Colhado OC, Boeing M, Ortega LB. Botulinum toxin in pain treatment. *Revista brasileira de anesthesiologia* 2003; 59: 366–381
- [16] Wheeler AH, Goolkasian P. Open label assessment of botulinum toxin a for pain treatment in a private outpatient setting. *Musculoskel Pain* 2001; 9: 68–82
- [17] Pasricha PJ, Sostre S, Kalloo AN. Endoscopic injection of botulinum toxin for patients with suspected sphincter of Oddi dysfunction: results of a pilot trial. *Gastrointest Endosc* 1994; 40: 421
- [18] Austin AS, Wheeler K, Larvin M et al. Transient response to botulinum toxin injection predicts the medium-term outcome after endoscopic sphincterotomy in type 2/3 sphincter of Oddi dysfunction. *Gut* 2010; 59: PTU-001 doi:10.1136/gut.2009.209015m
- [19] Wehrmann T, Seifert H, Seipp M et al. Endoscopic injection of botulinum toxin for biliary sphincter of Oddi dysfunction. *Endoscopy* 1998; 30: 702–707
- [20] Wheeler K, Salmon CA, Austin AS. Response to peri-ampullary botox injection and subsequent long term response to endoscopic sphincterotomy in type 2/3 sphincter of Oddi dysfunction. *Gut* 2014; 63: PTH-012 doi:10.1136/gutjnl-2014-307263.458
- [21] Murray W, Kong S. Botulinum toxin may predict the outcome of endoscopic sphincterotomy in episodic functional post-cholecystectomy biliary pain. *Scand J Gastroenterol* 2010; 45: 623–627
- [22] Macdougall L, Nayar M, McArdle F et al. Use of botulinum toxin to predict manometry results in type iii sphincter of Oddi dysfunction; a retrospective single centre review. *Gut* 2014; 63: OC-073 doi:10.1136/gutjnl-2014-307263.73
- [23] Menon S, Kurien R, Mathew R. The role of intrasphincteric botulinum toxin injection in the management of functional biliary pain: a systematic review and meta-analysis. *Eur J Gastroenterol Hepatol* 2020; 32: 984–989
- [24] Menon S, Mathew R. PTH-122 Is there a role for intra-sphincteric botulinum toxin injection in the management of type iii sphincter of oddi dysfunction? *Gut* 2017; 66: doi:10.1136/gutjnl-2017-314472.521
- [25] British Pain Society. Outcome Measures. Churchill House, 35 Red Lion Square, London WC1R 4SG: The Faculty of Pain Medicine of the Royal College of Anaesthetists; 2019: https://www.britishpainsociety.org/static/uploads/resources/files/Outcome_Measures_January_2019.pdf
- [26] Kurucsai G, Joó I, Fejes R et al. Somatosensory hypersensitivity in the referred pain area in patients with chronic biliary pain and a sphincter of Oddi dysfunction: new aspects of an almost forgotten pathogenetic mechanism. *Am J Gastroenterol* 2008; 103: 2717–2725
- [27] Thune A, Saccone GT, Scicchitano JP et al. Distension of the gall bladder inhibits sphincter of Oddi motility in humans. *Gut* 1991; 32: 690–693
- [28] Tanaka M, Ikeda S, Nakayama F. Change in bile duct pressure responses after cholecystectomy: loss of gallbladder as a pressure reservoir. *Gastroenterology* 1984; 87: 1154–1159
- [29] Rolny P, Funch-Jensen P, Kruse A et al. Effect of cholecystectomy on the relationship between hydrostatic common bile duct pressure and sphincter of Oddi motility. *Endoscopy* 1991; 23: 111–113
- [30] Pasricha PJ. Unraveling the mystery of pain in chronic pancreatitis. *Nature Rev Gastroenterol Hepatol* 2012; 24: 140–151

- [31] Li C, Zhu Y, Shenoy M et al. Anatomical and functional characterization of a duodeno-pancreatic neural reflex that can induce acute pancreatitis. *Am J Physiol Gastrointest Liver Physiol* 2013; 304: G490–500
- [32] Desautels SG, Slivka A, Hutson WR et al. Postcholecystectomy pain syndrome: pathophysiology of abdominal pain in sphincter of Oddi type III. *Gastroenterol* 1999; 116: 900–905
- [33] Pasricha PJ, Miskovsky EP, Kalloo AN. Intrasphincteric injection of botulinum toxin for suspected sphincter of Oddi dysfunction. *Gut* 1994; 35: 1319–1321
- [34] Sand J, Nordback I, Arvola P et al. Effects of botulinum toxin A on the sphincter of Oddi: an in vivo and in vitro study. *Gut* 1998; 47: 507–510
- [35] Macdougall L, Nayar M, McArdle F et al. OC-073 Use of botulinum toxin to predict manometry results in type iii sphincter of Oddi dysfunction; a retrospective single centre review. *Gut* 2014; 63: A36–37
- [36] Austin AS, Wheeler K, Larvin M et al. PTU-001 Transient response to botulinum toxin injection predicts the medium-term outcome after endoscopic sphincterotomy in type 2/3 sphincter of Oddi dysfunction. *Gut* 2010; 59: A48
- [37] Lacy BE, Weiser K, Kennedy A. Botulinum toxin and gastrointestinal tract disorders: panacea, placebo, or pathway to the future? *Gastroenterol Hepatol* 2008; 4: 283–295
- [38] Richardson WS, Willis GW, Smith JW. Evaluation of scar formation after botulinum toxin injection or forced balloon dilation to the lower esophageal sphincter. *Surg Endosc* 2003; 17: 696–698
- [39] Bloomston M, Fraiji E, Boyce HW Jr et al. Preoperative intervention does not affect esophageal muscle histology or patient outcomes in patients undergoing laparoscopic Heller myotomy. *J Gastrointest Surg* 2003; 7: 181–188 ; discussion 188–190
- [40] Cowgill SM, Villadolid DV, Al-Saadi S et al. Difficult myotomy is not determined by preoperative therapy and does not impact outcome. *JLS* 2007; 11: 336–343
- [41] Musial F, Klosterhalfen S, Enck P. Placebo responses in patients with gastrointestinal disorders. *World J Gastroenterol* 2007; 13: 3425–3429
- [42] Enck P, Klosterhalfen S. The placebo response in functional bowel disorders: perspectives and putative mechanisms. *Neurogastroenterol Motility* 2005; 17: 325–331