

# Safety and efficacy of dual emission endoscopic laser treatment in patients with upper or lower gastrointestinal vascular lesions causing chronic anemia: results from the first multicenter cohort study




## Authors

Gian Eugenio Tontini<sup>1,2,3</sup>, Lorenzo Dioscoridi<sup>4</sup>, Alessandro Rimondi<sup>3,5</sup>, Paolo Cantù<sup>3</sup>, Flaminia Cavallaro<sup>1,3</sup>, Aurora Giannetti<sup>4,6</sup>, Luca Elli<sup>3</sup>, Luca Pastorelli<sup>1,7</sup>, Francesco Pugliese<sup>4</sup>, Massimiliano Mutignani<sup>\*,4</sup>, Maurizio Vecchi<sup>\*,1,2,3</sup>

## Institutions

- 1 Gastroenterology and Digestive Endoscopy Unit, IRCCS Policlinico San Donato, San Donato Milanese, Milan, Italy
- 2 Department of Pathophysiology and Organ Transplantation, University of Milan, Milan, Italy
- 3 Gastroenterology and Endoscopy Unit, Fondazione IRCCS Ca' Granda Ospedale Maggiore Policlinico, Milan, Italy
- 4 Digestive and Interventional Endoscopy Unit, Niguarda Hospital, ASST Niguarda, Milan, Italy
- 5 Postgraduate Specialization in Gastrointestinal Diseases, University of Milan, Milan, Italy
- 6 Gastroenterology and Endoscopy Unit, IRCCS Multimedica, Sesto San Giovanni, Milano
- 7 Department of Biomedical Sciences for Health, University of Milan, Milan, Italy

submitted 28.8.2021

accepted after revision 21.9.2021

## Bibliography

Endosc Int Open 2022; 10: E386–E393

DOI 10.1055/a-1781-7066

ISSN 2364-3722

© 2022. The Author(s).

This is an open access article published by Thieme under the terms of the Creative Commons Attribution-NonDerivative-NonCommercial License, permitting copying and reproduction so long as the original work is given appropriate credit. Contents may not be used for commercial purposes, or adapted, remixed, transformed or built upon. (<https://creativecommons.org/licenses/by-nc-nd/4.0/>)


Georg Thieme Verlag KG, Rüdigerstraße 14,  
70469 Stuttgart, Germany

## Corresponding author

Gian Eugenio Tontini, MD PhD, Gastroenterology and Endoscopy Unit, Fondazione IRCCS Ca' Granda Ospedale Maggiore Policlinico, Via della Commenda 12, 20122 Milan, Italy

Fax: +02550312140

[gianeugeniotontini@gmail.com](mailto:gianeugeniotontini@gmail.com)

 Supplementary material is available under <https://doi.org/10.1055/a-1781-7066>

## ABSTRACT

**Objectives and study aims** Recent pilot studies have assessed the feasibility of a novel 1.9-/1.5- $\mu\text{m}$  dual emission endoscopic laser treatment ( $_{1.9-/1.5-\mu\text{m}}$ DEELT) for endoscopic hemostasis, ablation and resection. In this study, we investigated the safety and efficacy of  $_{1.9-/1.5-\mu\text{m}}$ DEELT in patients with chronic anemia due to gastrointestinal vascular lesions in a real-life multicenter cohort setting.

**Patients and methods** Consecutive patients with moderate/severe iron-deficiency anemia undergoing  $_{1.9-/1.5-\mu\text{m}}$ DEELT for upper and lower gastrointestinal bleeding due to vascular lesions were enrolled in three academic referral centers. Safety and successful ablation of vascular lesions were the primary outcomes. Long-term hemoglobin level, blood transfusion requirements, endoscopic severity scores of complex vascular disorders and technical lasing parameters were also assessed. Long-term hemoglobin variations have been further assessed, with repeated measure analysis of variance and univariate analyses.

**Results** Fifty patients (median age 74; range 47 to 91 years) with gastric antral vascular ectasia (GAVE) (22), angioectasia (22) and radiation proctopathy (6) underwent 58  $_{1.9-/1.5-\mu\text{m}}$ DEELT between 2016 and 2020. All procedures were technically feasible leading to successful ablation of the targeted lesion/s, with no incident or adverse event potentially related to the  $_{1.9-/1.5-\mu\text{m}}$ DEELT technique. Within a 6-month follow-up, hemoglobin values significantly rose (+1.77 at 1 month and +1.70 g/dL at 6 months,  $P < 0.01$ ), the blood supply requirement decreased (at least one transfusion in 32 versus 13 patients,  $P < 0.01$ ), and GAVE lesions showed a clear endoscopic improvement (from 5 points to 1 points,  $P < 0.01$ ).

**Conclusions** The 1.9-/1.5- $\mu\text{m}$  laser system is a safe and effective endoscopic tool for haemostatic ablation of bleeding vascular lesions within the gastrointestinal tract in tertiary referral centers.

\* These authors contributed equally.

## Introduction

Gastrointestinal bleeding is a considerable source of clinical morbidity and mortality. The annual incidence is estimated to be up to 40 to 150 cases per 100,000 people, with an overall mortality between 3% and 14% depending on the population considered [1, 2].

Endoscopic management of nonvariceal gastrointestinal bleeding relies on a discrete variety of endoscopic tools [3]. In the past two decades, technologies based on conveying thermal energy through electrosurgical devices, argon plasma coagulation or radiofrequency have become the leading endoscopic techniques for ablation of gastrointestinal vascular lesions with recurrent bleeding, such as gastric antral vascular ectasia (GAVE), radiation proctitis or angioectasia [4–7].

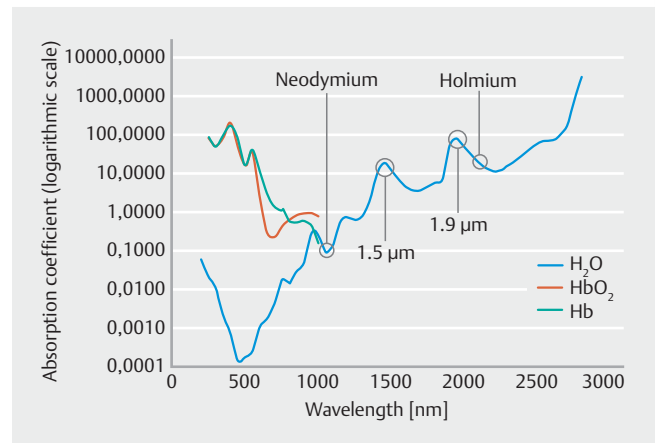
In a pilot study published in 2017, a novel laser system with a continuous wave mode and a 2.0- $\mu\text{m}$  wavelength was adopted for the first time to treat complex nonvariceal upper gastrointestinal bleeding in a real-life endoscopic setting, showing a very precise photocoagulation effect and an easy handling profile [8]. This result was later confirmed in small case series of patients treated for gastrointestinal angioectasia with a novel dual emission endoscopic laser system using 1.9- $\mu\text{m}$  and 1.5- $\mu\text{m}$  wavelength [9, 10]. These wavelengths combine a very low absorption coefficient for oxyhemoglobin, with an excellent water absorption coefficient among continuous wave lasers suitable for endoscopic purposes (► Fig. 1). This leads to a very confined effect, resulting in a precise coagulation and vaporesective cutting line with reduced risk of thermal injuries (► Video 1).

Here, we describe the first multicenter study of the use of a 1.9-/1.5- $\mu\text{m}$  dual emission endoscopic laser treatment ( $_{1.9-/1.5-\mu\text{m}}$ DEELT) system in patients with bleeding vascular disorders in the upper and lower gastrointestinal tract.

## Patients and methods

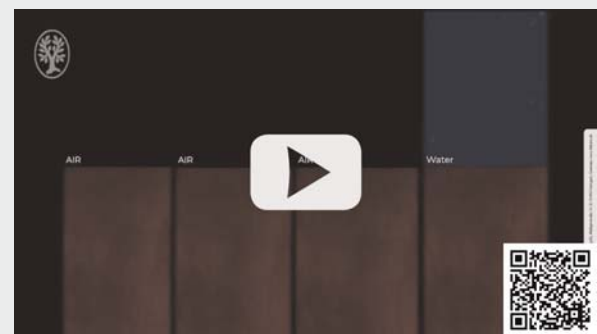
This was a multicenter observational study on consecutive patients undergoing upper or lower digestive endoscopy with  $_{1.9-/1.5-\mu\text{m}}$ DEELT, with all of the following inclusion criteria: aged over 18 years, moderate to severe iron-deficiency anemia (moderate defined respectively as  $\text{Hb} < 12 \text{ g/dL}$  in men and  $< 11 \text{ g/dL}$  in non-pregnant women, severe defined as  $\text{Hb} < 8 \text{ g/dL}$  in men and non-pregnant women [11–13]) and hemorrhagic gastrointestinal vascular disorders including angioectasia (i.e. a cluster of capillary dilatation within the mucosal layer), gastric antral vascular ectasia (GAVE) and radiation proctopathy (RP). Patients with established multiple sources of gastrointestinal bleeding were also included, according to the real-life setting of the present study, hereby featuring an intention-to-treat analyses.

Safety and technical success, defined respectively as the absence of adverse events (AEs) and as the successful ablation of gastrointestinal vascular lesions, were considered primary outcomes for this study. A successful ablation was achieved when no residual significant bleeding vascular lesion was visible at the end of each endoscopic treatment. AEs potentially related



► Fig. 1 Laser absorption coefficient for hemoglobin, oxyhemoglobin and water, according to different laser wavelengths.

## VIDEO



► Video 1 Video representation of the photoresection and photocoagulation effect on organic tissue of the  $_{1.9-/1.5-\mu\text{m}}$  dual emission endoscopic laser treatment, according to different settings and environmental conditions. Notably, overall power outputs  $< 5 \text{ W}$  have a very superficial effect (i.e., mucosal “blanching”) when targeting the gastrointestinal mucosa for no more than 2 seconds.

to  $_{1.9-/1.5-\mu\text{m}}$ DEELT or to the endoscopic procedure were documented and classified by the local investigators, according to the American Society for Gastrointestinal Endoscopy lexicon [14].

Secondary outcomes were defined as the difference between the values of the lowest hemoglobin (Hb) at baseline and 1 and 6 months after  $_{1.9-/1.5-\mu\text{m}}$ DEELT, as well as the difference in the mean number of packed red blood cell (PRBC) units in the 6 months before and after  $_{1.9-/1.5-\mu\text{m}}$ DEELT. A level of 7 g/dL was commonly defined as sufficient for prescribing a packed red blood cell transfusion; a lower threshold at 8 g/dL was considered for patients with known cardiovascular disease [15].

For each patient, we recorded age, sex, tobacco use, lowest hemoglobin values before and after 1 and 6 months from  $_{1.9-/1.5-\mu\text{m}}$ DEELT, need for PRBC transfusions during the 6 months before and after  $_{1.9-/1.5-\mu\text{m}}$ DEELT, Charlson comorbidity index [16], antiplatelet or anticoagulation therapy and presence of bleeding diathesis.

For each procedure, total power output, lasing time, fiber type and the need for further endoscopic haemostasis were recorded. A novel and quantitative endoscopic scoring system was proposed for evaluating the severity of GAVE before and after treatment. This score took into consideration antral mucosal vascular ectasia surface involvement (1–30% = 1 point, 30–50% = 2 points, >50% = 3 points) and the presence of bleeding (luminal traces of blood + 3 points, evidence of active bleeding after mucosal washing + 5 points). RP was evaluated with a three-item symptom score and endoscopic severity score, according to Dray et al [17].

Endoscopic procedures were performed in three tertiary referral endoscopic centers in the metropolitan area of Milan, Italy: IRCCS Policlinico San Donato (San Donato Milanese), ASST Niguarda and Cà Granda Ospedale Maggiore Policlinico (Milan) between March 2016 and May 2020. Three endoscopists (GET, LD, LE) with expertise in gastrointestinal bleedings and non-fully trained on  $1.9-/1.5\text{-}\mu\text{m}$  DEELT performed all of the procedures.

The  $1.9-/1.5\text{-}\mu\text{m}$  DEELT has been carried out using two endoscopic laser systems (Opera and Opera Evo by Quanta System, Samarate, Italy), allowing either a single or a blended use of 1.9- $\mu\text{m}$  and 1.5- $\mu\text{m}$  wavelengths delivered through flexible optical fibers (Quanta System), with a power setting ranging from 0.5 to 40W under continuous or pulsed modality (► **Table 1**). These laser systems have been European Community-certified for various medical uses, including interventional digestive endoscopy. Based on the previous experiences [8, 9, 18], all  $1.9-/1.5\text{-}\mu\text{m}$  DEELT procedures were conducted using a continuous emission modality with reusable flexible optical fibers (core diameter: 272, 365, 550, 600, and 800  $\mu\text{m}$ ) (► **Table 2** and **Supplementary Fig. 1**).

The endoscopic procedures were conducted following the European safety requirements for class 4 laser use (International Electrotechnical Commission standards IEC 60825), including the use of specific safety goggles, indoor laser-controlled area, warning signs and labels, operator's education and training, and standard operating procedures.

Data retrieval was performed retrospectively and anonymously at each center every 6 months based on a predefined and shared data set, according to the abovementioned primary and secondary outcomes. Paired Student *t*-test was used for the statistical analyses of the difference between continuous matched variables. Repeated Measure Analysis of Variance (ANCOVA) was employed to test null hypothesis among multiple groups of paired variables. Wilcoxon signed rank test was used in secondary outcomes subgroup analyses when data distribution was not assumed to be normally distributed. Univariate and multivariate analyses were employed to determine possible interactions of covariates on secondary outcomes results. Fisher's exact test was employed to test statistical significance in the analysis of contingency tables. Statistics were performed with the use of R software (R Foundation for Statistical Computing, Vienna, Austria).

All patients were treated according to best clinical practice and following the ethical principles of the Helsinki Declaration and all of its amendments. Informed consent for laser treatment was retrieved before each procedure.

► **Table 1** Opera Evo technical specifications.

Opera Evo Technical specifications	
Laser sources	1.9 $\mu\text{m}$ + 1.5 $\mu\text{m}$
Average power	Up to 30 W @ 1.9 $\mu\text{m}$ + up to 10 W @ 1.5 $\mu\text{m}$ with 0.5 W incremental step
Treatment mode	Single wavelength or combined emission
Emission mode	Continuous, pulsed and single pulse
Beam delivery	Wide range of flexible silica fibers
Aiming beam	520 nm (adjustable < 5 mW) – Class 3 R
Fiber recognition	RFID System
Laser class	4 (IEC / EN 60825–1:2007)
Cooling system	Closed water circuit/water air exchanger
Electrical requirements	200–230 Vac, 50/60 Hz, 1.5 kVA   240 Vac, 50 Hz, 1.5 kVA
Dimensions/weight	49.5 cm (W) × 63.6 cm (D) × 38.3 cm (H) / 40 kg transportable by cart

## Results

### Study population

Fifty consecutive patients underwent 58  $1.9-/1.5\text{-}\mu\text{m}$  DEELTs for GAVE (22 patients and 27 procedures), angioectasia (22 patients and 23 procedures) and RP (6 patients and 8 procedures). Within the angioectasia group, five  $1.9-/1.5\text{-}\mu\text{m}$  DEELTs were performed in the stomach, five in the duodenum, 11 in the right colon and two in both the stomach and duodenum. All of the procedures were conducted using a standard colonoscope for the lower gastrointestinal tract and a standard gastro-scope and/or duodenoscope for the upper gastrointestinal tract.

Median age was 74 years (interquartile range [IQR] 67 to 80, range 47 to 91), median Charlson comorbidity index was 5.5 (IQR 4 to 7.75, range 0 to 13); 36 of 58 procedures were performed on men, 23 in cirrhotic patients with portal hypertension and three in subjects with established multiple sources of gastrointestinal bleeding (► **Table 3**).

Overall, 12 of 58 procedures were carried out multiple times in four patients according to multiorgan vascular lesions (one patient with angioectasia), complex disorders requiring multiple treatment sessions (one patient with GAVE and one with RP), or very late disease recurrence following successful and complete endoscopic ablation with Hb normalization (one patient with GAVE received four  $1.9-/1.5\text{-}\mu\text{m}$  DEELTs, one every year, after a median follow-up of 11 months, range 9 to 12 months).

Most  $1.9-/1.5\text{-}\mu\text{m}$  DEELTs (44/58) were performed in patients on anticoagulant (16) or antiplatelet therapies (28). Concomitant assumption of acetylsalicylic acid was always tolerated, whereas anti-P2Y (e.g., Clopidogrel, Prasugrel) or anticoagulant drugs were discontinued on a patient-tailored risk assessment basis [19].

► **Table 2** Predictable pros and cons of dual emission endoscopic laser treatment versus standard hemostatic tools in gastrointestinal endoscopy.

DEELT feature	Pros	Cons
Confined photocoagulation effect	Precise ablation of vascular lesion with limited transmural and lateral thermal injuries.	Need for precise targeting of the lesion with the inert laser beam before any laser treatment.
Contactless energy release	Constant visualization of the targeted mucosa during photocoagulation.	Instability of distant targets during peristaltic wave movements.
	Quick ablation of larger lesions in fewer endoscopic sessions.	
	On demand distance from target.	
Precise setting calibration (fiber caliber, 1.9 and/or 1.5 μm power setting)	Tailored action based on both lesion and organ features.	Multiparameter setting option: fiber caliber and power output presetting according to the predictable endoscope angulation, targeted lesion extension, dry or water immersion setting, mucosal and submucosal thickness
	Dry or water immersion setting.	
	Cut, ablation and photocoagulation with the same probe.	
No gas insufflation	No risk of over-distension leading to tolerance and safety concerns.	–
No electrical circuit	No ancillary electric devices.	
	Compatible with any implanted electric medical device.	
Delivered by 200–1000 μm flexible optical fibers	Compatible with any endoscope working channel.	Progressive stiffness with larger fibers: difficult retroflexion and strict angulation with core diameter > 550 μm; challenging use with lateral-view scopes for core diameter > 350 μm.
	No or very limited impact on aspiration, washing and suctioning capabilities during the whole procedure.	
	A sphincterotome can be used to partially bend the optical fiber tip targeting tangential lesions.	Increased risk of fiber rupture within the endoscopic working channel when stressing the optical fiber stiffness with strict endoscope angulation.
Laser class 4 main requirements	–	Indoor laser-controlled area with warning signs and labels, dedicated operator's education and training, safety goggles, specific standard operating procedures
Device-related costs (power unit and optical fibers)	Comparable with those of other dedicated endoscopic treatment devices (e. g. radiofrequency ablation).	Considerable additional costs as compared to standard APC.

► **Table 3** Baseline demographic and clinical features. GAVE, gastric antral vascular ectasia; IQR, interquartile range.

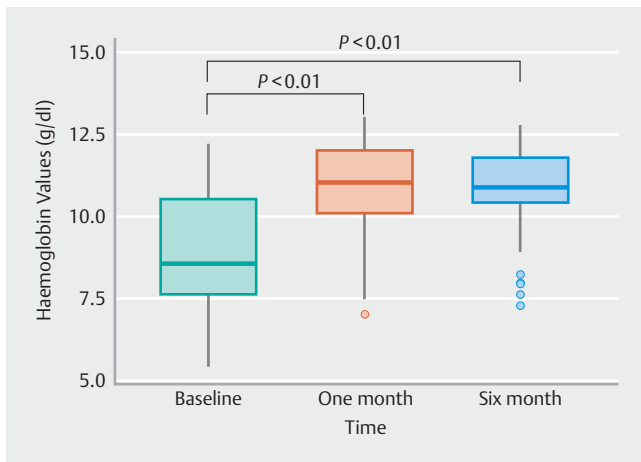
Procedures (patients)	58 (50)
Age	74 (IQR 67–80, range 47–91)
Gender	36 men of 58 procedures [62 %]
Charlson Comorbidity Index	5.5 (IQR 4–7.75, range 0–13)
Antiplatelet drugs	28 of 58 procedures [48 %]
Anticoagulant drugs	16 of 58 procedures [27 %]
Tobacco use	5 of 58 procedures [9 %]
Cirrhosis	23 of 58 procedures [39 %]
Bleeding vascular lesions per procedures (per patient)	27 (22) GAVE; 23 (22) angioectasia; 8 (6) radiation proctopathy

## Primary outcomes

All procedures were technically feasible leading to successful ablation of the targeted gastrointestinal vascular lesion/s, with no incident nor intraprocedural or post-procedural AEs potentially related to the 1.9-/1.5-μm DEELT technique including bleeding, perforation or necroses. Overall, no surgical intervention, prolonged hospital stays or hospitalization was required, except for one case of *Staphylococcus aureus* endocarditis that appeared 72 hours after 1.9-/1.5-μm DEELT of RP in a hospitalized 74-year-old woman with unrecognized severe heart valve disease who was later referred for cardiac surgery intervention.

## Secondary outcomes

Repeated Measure ANOVA was employed to test for statistical significance for the difference in lowest hemoglobin levels at 1 and 6 months after the procedure, showing an increase of 1.77 g/dL at 1 month after 1.9-/1.5-μm DEELT ( $P < 0.01$ ; 95%CI 1.08 to 2.46, mean 9.03 versus 10.81 g/dL) and 1.70 g/dL at 6 months ( $P < 0.01$ , 95%CI 0.97 to 2.43, 9.03 versus 10.74 g/dL)



► **Fig. 2** Boxplot of the lowest hemoglobin values pre- and post-laser ablation.

(► **Fig. 2**). The difference in lowest Hb levels at 1 and 6 months after the procedure was tested with univariate analysis for the following covariates: age, Charlson comorbidity index, need for transfusions, antiplatelet therapy, anticoagulant therapy, and treated pathology. None of these covariates was found to be statistically significant in affecting the gain or loss of hemoglobin levels.

The mean number of transfused PRBCs decreased by 2.5 compared to the 6 months before and the 6 months after  $1.9/1.5\text{-}\mu\text{m}$  DEELT (4.3 versus 1.7 PRBC,  $P < 0.01$ , 95%CI 1.5 to 4.0). Consistently, 60% of transfused patients (19/32) were relieved of the need for PRBC transfusion after  $1.9/1.5\text{-}\mu\text{m}$  DEELT, and the per patient blood supply requirement (at least one PRBC per patient) decreased from 55.2% (32/58) to 22.4% (13/58,  $P < 0.01$ , odds ratio 4.2, 95%CI 1.78 to 10.40) within the study population.

The endoscopic GAVE severity was evaluated before and 1 month after  $1.9/1.5\text{-}\mu\text{m}$  DEELT in 24 of 27 procedures (► **Fig. 3**). Median endoscopic improvement settled at a difference of 4 of 8 points from baseline (5 versus 1:  $P < 0.01$ , CI95% 4.0 to 5.5). Notably, 96.3% of GAVE (26/27 procedures) were treated in one unique endoscopic session (► **Video 2**). Symptoms and severity scores for RP were available in five of eight procedures and showed an improvement, without a statistically significant variation (mean endoscopic severity score: 5.8 versus 4.0,  $P = 0.37$ ; mean symptoms score: 2.6 versus 0.8,  $P = 0.15$ ).

### Additional endoscopic and technical parameters

Add-on hemostatic treatment with endoclips was adopted in five of 58  $1.9/1.5\text{-}\mu\text{m}$  DEELT in patients treated for multiple bleeding sources during the same procedure; this was done as a prophylactic measure rather than for incident persistent bleeding. All patients tolerated well the endoscopic treatments under conscious sedation, with intravenous midazolam ± opioids, and no general anesthesia was required.

Endoscopists reported an overall good and rapidly improving confidence in using  $1.9/1.5\text{-}\mu\text{m}$  DEELT, as well as excellent visualization of the mucosal target. The optical fiber with a core

### ► VIDEO



► **Video 2**  $1.9/1.5\text{-}\mu\text{m}$  Dual emission endoscopic laser treatment of a wide and actively bleeding GAVE lesion (with punctate pattern type) in a noncirrhotic 78-year-old man with severe iron-deficiency anemia. The single endoscopic session was carried out under conscious sedation. Endoscopic and laboratory follow-up confirmed both endoscopic and clinical remission.

diameter of 550  $\mu\text{m}$  was utilized in 42 of 58  $1.9/1.5\text{-}\mu\text{m}$  DEELT sessions (► **Supplementary Fig. 2**).

The settings and technical parameters for the  $1.9/1.5\text{-}\mu\text{m}$  DEELT sessions are provided in ► **Table 4**. No relevant difference in settings and technical parameters was observed among the three centers involved. When adopted for gastrointestinal segments with a thicker mucosal/submucosal layer, the laser output was increased to achieved deep photocoagulation of lesions with a submucosal origin (e. g., GAVE) and induce curative tissue scars (RP). In contrast, thinner gastrointestinal tract was approached with a more conscious and conservative laser output presetting to avoid deep transmural damage.

## Discussion

The  $1.9/1.5\text{-}\mu\text{m}$  DEELT is a novel endoscopic tool designed to improve hemostatic ablation and resection of luminal lesions along the entire gastrointestinal tract. The 1.9- $\mu\text{m}$  wavelength has a precise and confined action on tissues, due to the strong absorption of energy by molecules of water. In fact, the thulium-doped yttrium-aluminum-garnet laser system, which shares these specific wavelength features (1.91 to 2.04  $\mu\text{m}$ ), is an established surgical device, especially in the field of urology (prostate vapo-resection, enucleation and ablation [20–24], bladder tumors [25], ureteral and kidney neoplasia [26] and stricture [27]). This peculiarity limits potential transmural and lateral damage when treating gastrointestinal mucosa, as confirmed in a preliminary ex vivo histological study [18].

The second wavelength of 1.5  $\mu\text{m}$  produces more pronounced coagulation and has a less confined effect due to a lower absorption capacity for water (► **Fig. 1**).

Recent ex vivo and in vivo retrospective pilot studies have shown very promising results with the use of these lasers in gastrointestinal luminal endoscopy for the treatment of vascular lesions [9,10], Zenker diverticulum [28,29], lithotripsy [30],

► **Table 4** Dual emission endoscopic laser treatment: technical parameters.

	GAVE	Angioectasia <sup>1</sup>	RP
No. procedures	27	23	8
Median laser power output 1.9 $\mu$ m (W) + 1.5 $\mu$ m (W)	7 (IQR 6–8) + 2 (IQR 1–2)	3 (IQR 3–4) + 1 (IQR 1–2)	6 (IQR 5–8) + 2.5 (IQR 1–3)
Median released energy 1.9 $\mu$ m (J) + 1.5 $\mu$ m (J)	2002 (IQR 1538–2507) + 460 (IQR 306–693)	21 (IQR 13–36) + 9 (IQR 5–15) <sup>2</sup>	1531 (IQR 807–2400) + 577 (IQR 278–696)
Median lasing time (seconds)	296 (IQR 238–362)	6 (IQR 4–11) <sup>†</sup>	266 (IQR 174–295)

GAVE, gastric antral vascular ectasia; IQR, interquartile range.

<sup>1</sup> Angiectasia distribution: 11 in the right colon (1.9 + 1.5  $\mu$ m median power output: 3W + 1W), 5 in the stomach (1.9 + 1.5  $\mu$ m median power output: 7W + 2W), 5 in the duodenum (1.9 + 1.5  $\mu$ m median power output: 5W + 2W), 2 in both stomach and duodenum.

<sup>2</sup> Five outlier procedures were ruled out due to extensive and prolonged laser ablation of multiple and large angioectasias significantly affecting final technical parameters results.

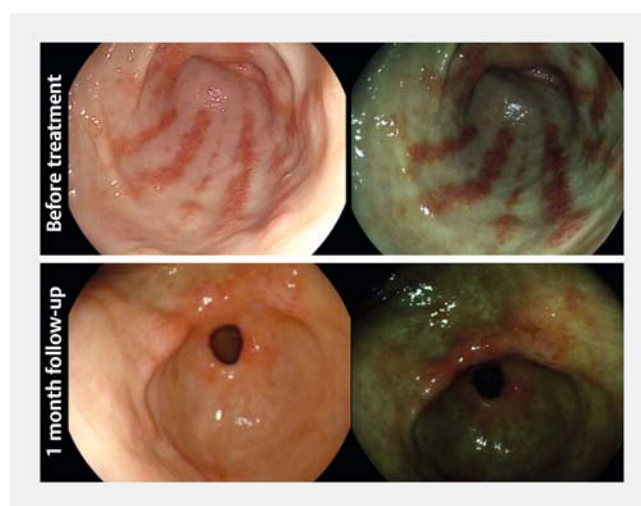
ablation of preneoplastic lesion, tumor debulking [8], mucosal incision, submucosal tunnelling, and dissection [18].

This multicenter series of consecutive patients finally confirms both the safety and the effectiveness of  $1.9\text{-}/1.5\text{-}\mu\text{m}$ DEELT for gastrointestinal vascular lesions in a real-life clinical scenario. The endoscopic photocoagulation of mucosal vascular lesions was feasible and successful with an excellent safety profile in the upper as well as in the lower gastrointestinal tract. Consistently, patients undergoing  $1.9\text{-}/1.5\text{-}\mu\text{m}$ DEELT showed quick and sustained restoration of hemoglobin levels and reduced transfusion support.

Notably, neither technical problems nor safety nor near miss occurred. In addition, the  $1.9\text{-}/1.5\text{-}\mu\text{m}$ DEELT technique was reproducible with excellent maneuverability and resulted in substantial immediate confidence among independent endoscopic operators from their first uses of the technique and despite limited experience with non-contact devices and laser systems. Remarkably, 96.3% of patients with GAVE were treated in one unique endoscopic session under conscious sedation, confirming the excellent maneuverability and tolerability of this technique.

The study limitations and the potential role of  $1.9\text{-}/1.5\text{-}\mu\text{m}$ DEELT in the gastrointestinal setting should be discussed. As far as this real-life study is concerned, the retrospective design represents a potential source of bias. To narrow this limitation, a predefined data set was designed a priori, according to the above-mentioned primary and secondary outcomes and data collection was performed every 6 months at each tertiary endoscopic center. Symptoms and severity scores for RP failed to demonstrate a statistically significant improvement and this is probably due to the low number of procedures [8]. There is no validated scoring system to assess disease or endoscopic severity of GAVE yet; consistently, we have designed a quantitative endoscopic scoring system for evaluating the severity of GAVE before and after treatment, which should later cross the formal multistep validation process.

Further, we did not make a comparison with standard endoscopic treatment modalities, hereby shadowing potential predicted benefits of the  $1.9\text{-}/1.5\text{-}\mu\text{m}$ DEELT option. In fact, even though electrosurgical probes, argon plasma coagulation (APC) and, to a lesser extent, radiofrequency are well-established



► **Fig. 3** Images of gastric mucosa from a patient affected by GAVE treated with  $1.9\text{-}/1.5\text{-}\mu\text{m}$ DEELT. Note the reduced extent of vascular abnormalities after laser treatment and residual small ulcers.

tools in modern endoscopy, they are not free from flaws. Electrosurgical probes need stable contact with the mucosa, masking the targeted area and potentially leading to lateral or transmural thermal injury [3]. APC is a non-contact device similarly requiring close proximity (2–10 mm) and conveying energy in a scattered manner across the submucosa and the muscle layer [8, 31, 32]. APC might also induce gas over-distension, reducing patient tolerance and raising safety concerns for prolonged treatments (e.g., GAVE) or fragile segments (e.g., cecum) [1, 2]. Furthermore, our results on hemoglobin levels at 1 month are comparable to previous findings of endoscopic treatment GAVE with APC [33].

In the present real-life multicenter study, the peculiarities of the  $1.9\text{-}/1.5\text{-}\mu\text{m}$ DEELT system have shown predictable pros and cons in clinical practice compared with standard devices for hemostatic ablation along the gastrointestinal tract, as outlined in reports from previous smaller studies [8–10, 28–30, 34–37] (► **Table 2**). This new generation of lasers suitable for endoscopic therapy has shown a very confined and adjustable photocoagulative effect as opposed to previous laser devices for

endoscopic thermocoagulation abandoned since the 1990s for either safety or cost-related issues. Notwithstanding, the use of a class 4 laser system for clinical activity still implies additional direct costs and several logistical requirements (► **Table 2**). In addition, a few technical aspects also should be highlighted. The stiffness of larger fibers can be an obstacle in cases of strict angulations, tangential lesions or with the use of lateral-view scopes potentially leading to accidental damage during fiber advancement over the endoscope working channel or against the gastrointestinal wall. Unrecognized fiber breakage during laser application can cause laser leakage with safety hazard. On the other hand, the flexibility of most fibers (up to a core diameter of 550  $\mu\text{m}$ ) allows laser treatments during endoscope retroversion and use of ancillary devices such as a sphincterotome to partially bend the optical fiber tip targeting tangential lesions. This small caliber does not require large operative channel endoscopes, thereby enabling aspiration, suction and washing during the entire procedure (especially in comparison with large-caliber hemostatic systems). Moreover, the green inert lasing beam helps the endoscopist both to target easier the lesion and to adjust and find the best distance for 1.9-/1.5- $\mu\text{m}$  DEELT.

## Conclusions

Taken together, this multicenter study conducted in a real-life scenario confirms the safety and effectiveness profile of the novel 1.9-/1.5- $\mu\text{m}$  dual emission endoscopic laser treatment in patients with bleeding vascular disorders in the upper and lower gastrointestinal tract, thus paving the way for randomized clinical trials, including with standard endoscopic hemostatic tools.

## Acknowledgments

The laser system and the optical fibers were provided unconditionally without cost by Quanta System for clinical purposes during the study period. Preliminary data were presented at the United European Gastroenterology Week in 2018 and 2019.

## Competing interests

The authors declare that they have no conflict of interest.

## References

- [1] Naseer M, Lambert K, Hamed A et al. Endoscopic advances in the management of non-variceal upper gastrointestinal bleeding: A review. *World J Gastrointest Endosc* 2020; 12: 1–16
- [2] Gralnek IM, Dumonceau JM, Kuipers EJ et al. Diagnosis and management of nonvariceal upper gastrointestinal hemorrhage: European Society of Gastrointestinal Endoscopy (ESGE) Guideline. *Endoscopy* 2015; 47: a1–a46
- [3] Tokar JL, Barth BA, Banerjee S et al. Electrosurgical generators. *Gastrointest Endosc* 2013; 78: 197–208
- [4] Tabaja L, Sidani SM. Management of radiation proctitis. *Dig Dis Sci* 2018; 63: 2180–2188
- [5] Naidu H, Huang Q, Mashimo H. Gastric antral vascular ectasia: the evolution of therapeutic modalities. *Endosc Int Open* 2014; 02: E67–E73
- [6] Albitar HAH, Almodallal Y, Papadakis KA et al. Intravenous bevacizumab reduces transfusion requirements and endoscopic interventions in patients with gastric antral vascular ectasia and small bowel angioectasia. *Gastroenterology* 2020; 158: 1162–1163.e4
- [7] Chetcuti Zammit S, Koulaouzidis A, Sanders DS et al. Overview of small bowel angioectasias: clinical presentation and treatment options. *Expert Rev Gastroenterol Hepatol* 2018; 12: 125–139
- [8] Tontini GE, Neumann H, Pastorelli L et al. Thulium laser in interventional endoscopy: animal and human studies. *Endoscopy* 2017; 49: 365–370
- [9] Tontini GE, Rimondi A, Neumann H et al. Safety and efficacy of the new thulium/erbium laser system in patients with gastrointestinal bleeding from vascular lesions. *United Eur Gastroenterol J* 2018; 6: A318
- [10] Dioscoridi L, Forti E, Pugliese F et al. Thulium laser coagulation: a new effective endotherapy to treat gastrointestinal angiodysplasia. *Gastrointest Endosc* 2019; 90: 319–320
- [11] Ko CW, Siddique SM, Patel A et al. AGA Clinical Practice Guidelines on the Gastrointestinal Evaluation of Iron Deficiency Anemia. *Gastroenterology* 2020; 159: 1085–1094
- [12] Goddard AF, James MW, McIntyre AS et al. Guidelines for the management of iron deficiency anaemia. *Gut* 2011; 60: 1309–1316
- [13] World Health Organization. Haemoglobin concentrations for the diagnosis of anaemia and assessment of severity. Vitamin and Mineral Nutrition Information System. Geneva: World Health Organization (WHO/NMH/NHD/MNM/11.1); <http://www.who.int/vmnis/indicators/haemoglobin.pdf>
- [14] Cotton PB, Eisen GM, Aabakken L et al. A lexicon for endoscopic adverse events: report of an ASGE workshop. *Gastrointest Endosc* 2010; 71: 446–454
- [15] Carson JL, Guyatt G, Hedde NM et al. Clinical practice guidelines from the AABB: Red blood cell transfusion thresholds and storage. *JAMA* 2016; 316: 2025–2035
- [16] Charlson M, Pompei P, Ales K et al. A new method of classifying prognostic comorbidity in longitudinal studies: development and validation. *J Chronic Dis* 1987; 40: 373–383
- [17] Dray X, Battaglia G, Wengrower D et al. Radiofrequency ablation for the treatment of radiation proctitis. *Endoscopy* 2014; 46: 970–976
- [18] Tontini G, Neumann H, Rimondi A et al. Ex vivo experimental study on the Thulium laser system: new horizons for interventional endoscopy (with videos). *Endosc Int Open* 2017; 05: E410–E415
- [19] Veitch AM, Vanbiervliet G, Gershlick AH et al. Endoscopy in patients on antiplatelet or anticoagulant therapy, including direct oral anticoagulants: British Society of Gastroenterology (BSG) and European Society of Gastrointestinal endoscopy (ESGE) guidelines. *Gut* 2016; 65: 374–389
- [20] Xia SJ, Zhuo J, Sun XW et al. Thulium laser versus standard transurethral resection of the prostate: a randomized prospective trial. *Eur Urol* 2008; 53: 382–390
- [21] Carmignani L, Pastore AL, Picozzi SCM et al. Thulium laser prostate enucleation in refractory urinary retention: operative and functional outcomes in a large cohort of patients. *Urology* 2016; 93: 152–157
- [22] Kirschbaum A, Höchsmann N, Steinfeldt T et al. Investigations of initial airtightness after non-anatomic resection of lung parenchyma using a thulium-doped laser with different optical fibres. *Lasers Med Sci* 2016; 31: 1097–1103
- [23] Passacantilli E, Lapadula G, Caporlingua F et al. Preparation of naso-septal flap in trans-sphenoidal surgery using 2- $\mu$  thulium laser: Technical note. *Photomed Laser Surg* 2015; 33: 220–223

- [24] Herrmann TRW, Bach T, Imkamp F et al. Thulium laser enucleation of the prostate (ThuLEP): Transurethral anatomical prostatectomy with laser support. Introduction of a novel technique for the treatment of benign prostatic obstruction. *World J Urol* 2010; 28: 45–51
- [25] Zhang X, Feng C, Zhu W et al. Two micrometer continuous-wave thulium laser treating primary non-muscle-invasive bladder cancer: Is it feasible? a randomized prospective study *Photomed Laser Surg* 2015; 33: 517–523
- [26] Musi G, Mistretta F, Marengi C et al. Thulium laser treatment of upper urinary tract carcinoma: a multi-institutional analysis of surgical and oncological outcomes. *J Endourol* 2018; 32: 257–263
- [27] Wang L, Wang Z, Yang B et al. Thulium laser urethrotomy for urethral stricture: a preliminary report. *Lasers Surg Med* 2010; 42: 620–623
- [28] Siboni S, Aiolfi A, Ceriani C et al. Cricopharyngeal myotomy with thulium laser through flexible endoscopy: proof-of-concept study. *Endosc Int Open* 2018; 06: E470–E473
- [29] Zanghi S, Siboni S, Asti E et al. Endoscopic stapling versus laser for Zenker diverticulum: a retrospective cohort study. *Eur Arch Oto-Rhino-Laryngology* 2020; doi:10.1007/s00405-020-06346-4
- [30] Mutignani M, Dioscoridi L, Italia A et al. Thulium laser to manage a difficult biliary lithiasis: a first case report. *Endoscopy* 2019; doi:10.1055/a-0983-8278
- [31] Manner H, Neugebauer A, Scharpf M et al. The tissue effect of argon-plasma coagulation with prior submucosal injection (Hybrid-APC) versus standard APC: A randomized ex-vivo study. *United Eur Gastroenterol J* 2014; 2: 383–390
- [32] Gong EJ, Ahn JY, Jung HY et al. Effects of argon plasma coagulation on human stomach tissue: An ex vivo study. *J Gastroenterol Hepatol* 2017; 32: 1040–1045
- [33] Fuccio L. Diagnosis and management of gastric antral vascular ectasia. *World J Gastrointest Endosc* 2013; 5: 6–13
- [34] Dioscoridi L, Pugliese F, Bertoglio C et al. Thulium laser to endoscopically manage a rectal erosion and intraluminal mesh migration after ventral rectopexy. *BMJ Case Rep* 2021; 14: e235807
- [35] Dioscoridi L, Forti E, Pugliese F et al. Endoscopic intraductal lithotripsy of biliary stones using thulium laser: preliminary results of a single-center experience. *Lasers Med Sci* 2021; doi:10.1007/s10103-021-03382-2
- [36] Cho J, Cho J, Kim M et al. Endoscopic submucosal dissection using a thulium laser: preliminary results of a new method for treatment of gastric epithelial neoplasia. *Endoscopy* 2013; 45: 725–728
- [37] Jung Y, Baik GH, Ko WJ et al. Diode laser – Can it replace the electrical current used in endoscopic submucosal dissection? *Clin Endosc* 2021; 54: 555–562