

Endoscopic vacuum therapy (EVT) for acute esophageal perforation: Could it replace surgery?



Authors

Petros Stathopoulos¹, Malte Zumblick¹, Sabine Wächter², Leif Schiffmann³, Thomas M. Gress⁴, Detlef Bartsch², Guido Seitz⁵, Ulrike W. Denzer¹

Institutions

- 1 Division of Interdisciplinary Endoscopy, Department of Gastroenterology, University Hospital Marburg, Marburg, Germany
- 2 Department of Visceral, Thoracic and Vascular Surgery, University Hospital Marburg, Marburg, Germany
- 3 Department of General, Visceral and Thoracic Surgery, Helios Hospital Aue, Aue, Germany
- 4 Department of Gastroenterology, University Hospital Marburg, Marburg, Germany
- 5 Department of Pediatric Surgery, University Hospital Marburg, Marburg, Germany

Baldingerstrasse 1, 35043 Marburg, Germany

Fax: +4964215863266

stathpetros@hotmail.com

ABSTRACT

Background and study aims Acute esophageal perforation is a potentially life-threatening condition that demands a multidisciplinary approach. Based on recently published data indicating that EVT may be effective in managing esophageal perforation, we report our institution's experience with EVT in this clinical setting.

Patients and methods We retrospectively analyzed all 10 patients with acute esophageal perforation from May 2018 to January 2021, using descriptive statistics. The primary outcome was successful closure of the perforation. Secondary outcomes included the length of treatment, number of endoscopic procedures required, and complication rate.

Results All patients (site of perforation: 4 upper, 2 middle, 4 lower esophagus; etiology: 8 iatrogenic, 2 foreign body ingestion) were treated with EVT successfully. In eight cases, EVT was started immediately after the perforation, in the other two cases 1 and 2 days later. The median (interquartile range) number of endoscopic procedures was 2.5 (range, 2–3) and the median duration of treatment was 7.5 days (range, 7–11.5). The sponge was placed in eight cases intraluminally, in the other two cases initially intracavitary. No complication occurred.

Conclusions EVT is highly effective for managing acute esophageal perforation within 1 to 3 weeks. Immediate start of EVT to prevent abscess formation and induce defect closure is crucial.

submitted 31.10.2021

accepted after revision 24.1.2022

published online 24.2.2022

Bibliography

Endosc Int Open 2022; 10: E686–E693

DOI 10.1055/a-1781-0827

ISSN 2364-3722

© 2022. The Author(s).

This is an open access article published by Thieme under the terms of the Creative Commons Attribution-NonDerivative-NonCommercial License, permitting copying and reproduction so long as the original work is given appropriate credit. Contents may not be used for commercial purposes, or adapted, remixed, transformed or built upon. (<https://creativecommons.org/licenses/by-nc-nd/4.0/>)

Georg Thieme Verlag KG, Rüdigerstraße 14,
70469 Stuttgart, Germany

Corresponding author

Petros Stathopoulos, University Hospital of Giessen and Marburg Campus Marburg, Division of Interdisciplinary Endoscopy, Department of Gastroenterology,

Introduction

Esophageal perforation, defined as an acute rupture of the esophageal wall, is a severe clinical condition with a high mortality rate of 13.3% [1]. To date there is no consensus about the optimal management of esophageal perforation. Treatment options range from surgery to endoscopic modalities such as through-the-scope clips (TTS), over-the-scope clips (OTSC),

self-expandable metal stents (SEMS), and endoscopic vacuum therapy (EVT). Although surgery is supposed to be the gold standard for managing esophageal perforation, about half of the cases are treated initially endoscopically (51.3%), mostly with placement of a metal stent [1, 2].

Recent studies have shown very promising results in management of upper gastrointestinal leaks with EVT, including esophageal perforations and postoperative leakage of esopha-

gogastrostomies. EVT has many theoretical advantages, which are already known based on its use for vacuum-assisted closure therapy of external wounds, including continuous drainage that prevents accumulation of secretion, reduction in local edema, increased local perfusion, and promotion of granulation tissue ingrowth [3, 4].

An EVT sponge can be manually prepared by assembling a piece of foam in the required size with a nasogastric tube [5] or a ready-made, commercially available sponge kit can be used (Eso-SPONGE). The aim of this study was to demonstrate the advantages of EVT in management of acute esophageal perforation measured by the closure rate of perforations. In addition, we aimed to underscore the great importance to patient clinical outcomes of early detection of and therapy for perforation.

Patients and methods

Study design and inclusion criteria

We performed a retrospective, single-center analysis of all patients who presented with acute esophageal perforation at the Department of Interdisciplinary Endoscopy of the University Hospital in Marburg, Germany from May 2018 to January 2021, by treating them with low negative-pressure EVT. This retrospective analysis was approved by the local ethical review board (Philipps-Universität Marburg, file reference "Studie_ek_mr_210721_denzer-3"). Each patient provided written informed consent for the procedure. For each patient there was interdisciplinary consent before starting treatment, considering EVT as the best possible therapeutic option.

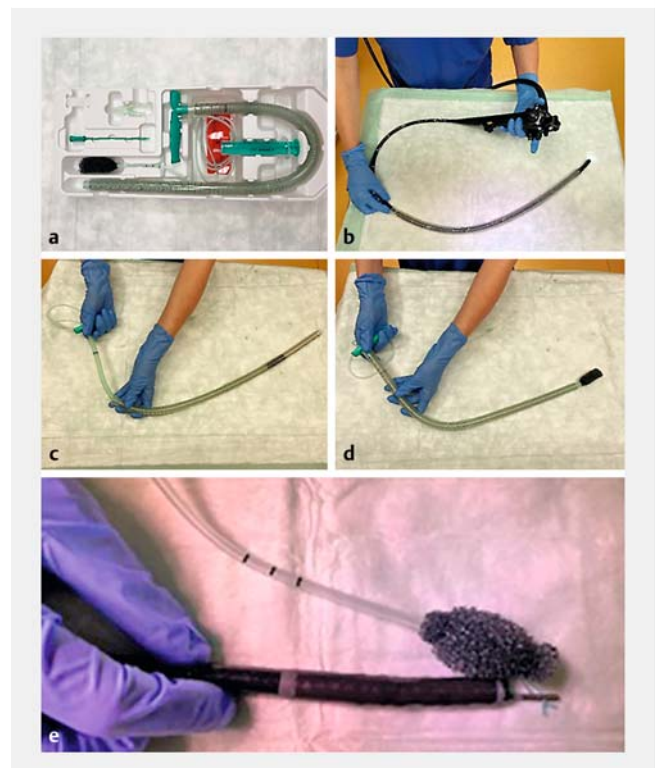
The primary outcome was the rate of closure of perforation with EVT, which was defined as the endoscopic finding of restoration of continuity of the esophagus, confirmed by clinical improvement and decrease in inflammatory parameters, even after the start of oral feeding. Secondary outcomes included: 1) length of the treatment; 2) number of endoscopic procedures required before closure of the perforation was achieved; and 3) rate of procedure-related complications.

All patients with an acute esophageal perforation were treated with EVT and were included in the analysis. Perforation was defined as a full-thickness esophageal wall defect. Patients with a diagnosis of another defect of the esophagus, such as fistulas or postoperative leaks, were excluded from this analysis. For all patients, the following parameters were recorded: basic characteristics (age, gender), laboratory data (white blood cell count and C-reactive protein), and etiology of the perforation. The following procedure characteristics were also recorded: size of the perforation, its anatomical location, the time it took to diagnose the perforation, the position of the sponge (intraluminal or inside the cavity), the number of exchanges of the sponge needed, the length of treatment and the rate of defect closure. Follow-up was performed by endoscopy, telephone interviews, and hospital visits.

Procedure

The procedures were performed under conscious sedation by means of intravenous propofol administration unless the patients were in septic shock with hemodynamic instability, or at higher-than-normal risk for sedation (according to the American Society of Anesthesiologists physical status classification), and they underwent general endotracheal anesthesia. Two experienced endoscopists performed all the procedures. Patients were kept nil per mouth. Before initial placement of the Eso-SPONGE, a nasojejunal tube was inserted to maintain enteral nutrition. Broad-spectrum antibiotics and proton pump inhibitors were administered intravenously.

Initiation of EVT was performed as soon as possible after the diagnosis of perforation was made, mostly directly after iatrogenic perforation occurred during a therapeutic intervention. The site of the perforation was carefully evaluated, and the perforation cavity was irrigated and debrided, if necessary. After placing an overtube transorally into the cavity or intraluminally using the endoscope as a guide rail, the sponge was pushed forward through the overtube to the desired location with a pusher (► Fig. 1). Alternatively, if the overtube did not fit through an esophageal stenosis or through a perforation with narrow opening, an air knot was created at the proximal end of the sponge after stitching through the tube and the knot was cap-



► **Fig. 1** Technical preparation of EVT. **a** Eso-SPONGE kit. **b** Endoscope serves as a guide rail for insertion of the overtube. **c, d** Sponge placement via overtube with a pusher. **e** Sponge insertion without overtube by creating an air knot at the proximal end of the sponge after stitching through the tube and capturing the knot by a grasping forceps.

tured by a grasping forceps, which had previously been inserted into the scope, and finally the sponge was inserted together with the scope in the esophagus. The drain, which was connected to the sponge, was transnasally channeled and then connected to an external suction pump; thus, negative pressure could be applied. The external pump was set at a continuous negative pressure of 125 to 150 mm Hg and high intensity. The sponge was changed twice a week to prevent adhesion to the esophagus or to the wound cavity and to control the healing process, until closure of the perforation was endoscopically documented. After that, oral feeding was started and patient clinical course and laboratory data were assessed for 2 days more before discharge.

Statistical analysis

Datasets were compiled and a descriptive analysis for patient and procedural characteristics was performed by using Microsoft Excel. Continuous variables are presented as medians with interquartile range. Categorical variables are presented as absolute values and percentages.

Results

Patient and procedure characteristics

From May 2018 to January 2021, all 10 patients with acute esophageal perforations were treated with EVT and were included in our retrospective analysis. Baseline patient and procedure characteristics are presented in ► **Table 1** and in detail in ► **Table 2**.

We report four cases with a perforation of the upper esophagus, two of which were associated with ingestion of foreign bodies (a pen and a piece of glass), one of which occurred accidentally during a diagnostic esophagoscopy in a patient with pemphigus vulgaris; and the last case occurred as a complication of a flexible endoscopy-assisted diverticulotomy (► **Fig. 2** and ► **Video 1**).

Furthermore, we treated two patients with perforation of the middle esophagus. In one case, the perforation occurred during removal of a food bolus. The other case involved a 3-year-old child with a caustic stricture of the esophagus, who unfortunately experienced perforation of the middle esophagus during a gastroscopy 3 weeks after the caustic ingestion. In that case, we had to cut the sponge to the appropriate size to fit the small diameter of the child's esophagus with the caustic stricture. Because the overtube would not fit in the child's esophagus, we had to insert the sponge into the esophagus together with the scope, by creating a knot at the proximal end of the foam after stitching through the tubing and by grasping the knot with a rat tooth grasper, which had previously been inserted into the scope (► **Fig. 3** and ► **Video 2**).

Moreover, we report four cases with perforation of the lower esophagus after pneumatic balloon dilation (30 mm) of the lower esophageal sphincter for achalasia (► **Fig. 4** and ► **Video 3**).

In eight of 10 cases, EVT was started immediately after the perforation was seen on endoscopy. In one patient with perforation of the upper esophagus, the initial defect closure with

► **Table 1** Baseline patient and procedure characteristics.

	No. patients (n = 10)
Age, years, median (IQR)	68.5 (39.5–76.8)
Sex, n (%)	
▪ Male	4 (40)
▪ Female	6 (60)
Etiology of perforation, n (%)	
▪ Pneumatic balloon dilation with 30-mm Rigiflex balloon	4 (40)
▪ Foreign body	2 (20)
▪ Diagnostic EGD, pemphigus vulgaris	1 (10)
▪ Removal of food bolus	1 (10)
▪ Caustic stricture	1 (10)
▪ Endoscopic-assisted diverticulotomy	1 (10)
Anatomical location, n (%)	
▪ Upper esophagus	4 (40)
▪ Middle esophagus	2 (20)
▪ Lower esophagus	4 (40)
Size of the perforation, mm, median (IQR)	17.5 (15–20)
Time until start of EVT after perforation, days, median (range)	0 (0–2)
Position of the sponge, n (%)	
▪ Intraluminal	8 (80)
▪ Intracavitary & intraluminal	2 (20)
No of Eso-SPONGE change, mean (IQR)	2.5 (2–3)
Treatment duration, days	7.5 (7–11.5)
Complete closure of the perforation, n (%)	10 (100)
Clinical follow-up, months, median (IQR)	8 (1.3–18.3)

IQR, interquartile range; EGD, esophagogastroduodenoscopy; EVT, endoscopic vacuum therapy.

TTS clips was not sufficient, as shown the next day on a computed tomography (CT) scan with oral contrast; thus, EVT was started 1 day after perforation. In another case, the perforation was suspected 2 days after pneumatic dilation based on the increase of C-reactive protein and confirmed endoscopically, leading to delayed initiation of EVT. In all but two cases, the sponge was placed intraluminally; in the remaining two cases, the patients were treated initially with intracavitary placement due to the large size of the perforation. In seven of 10 cases, a CT scan was performed after diagnosis of perforation was made to access mediastinitis and extraluminal fluid collections.

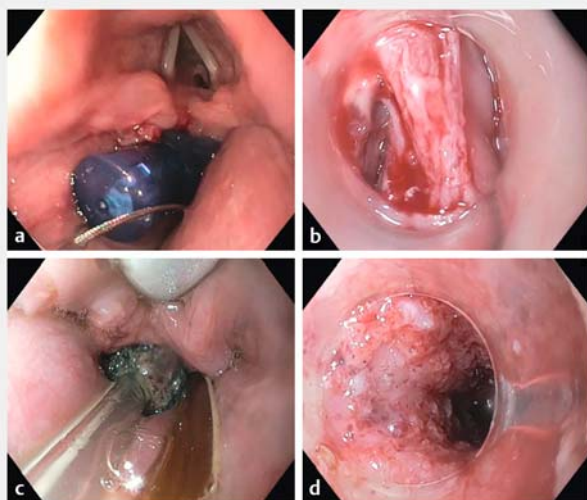Primary and secondary outcomes

The median duration of EVT was 7.5 days (IQR 7–11.5) with a median number of 2.5 sponge changes (IQR 2–3), leading to successful closure of the perforation in all cases (n = 10/10),

► **Table 2** Detailed patient and procedure characteristics.

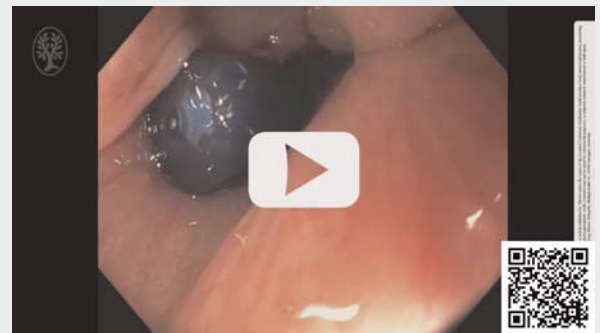Case	Age, years	Sex	Etiology of perforation	Anatomical location	Size, mm	Days after perforation to sponge placement	Position of the sponge	Eso-SPONGE changes, n	Treatment duration, days	Complete closure
1	66	F	Diagnostic EGD; pemphigus vulgaris	Upper esophagus	10	1	Intraluminal	2	7	+
2	25	M	Foreign body (glass piece)	Upper esophagus	20	0	Intraluminal	3	12	+
3	33	F	Foreign body (pen)	Upper esophagus	10	0	Intraluminal	2	8	+
4	79	F	Endoscopic-assisted-diverticulotomy	Upper esophagus	15	0	Intraluminal	1	3	+
5	59	M	Removal of food bolus	Middle esophagus	15	0	Intraluminal	2	7	+
6	3	F	Caustic stricture	Middle esophagus	20	0	Intraluminal	3	10	+
7	73	F	Pneumatic dilation, achalasia	Lower esophagus	50	0	Intracavitary and intraluminal	5	21	+
8	78	M	Pneumatic dilation, achalasia	Lower esophagus	20	0	Intraluminal	1	4	+
9	79	M	Pneumatic dilation, achalasia	Lower esophagus	30	0	Intraluminal	3	7	+
10	71	F	Pneumatic dilation, achalasia	Lower esophagus	20	2	Intracavitary and intraluminal	5	20	+

EGD, esophagogastroduodenoscopy; F, female; M, male.

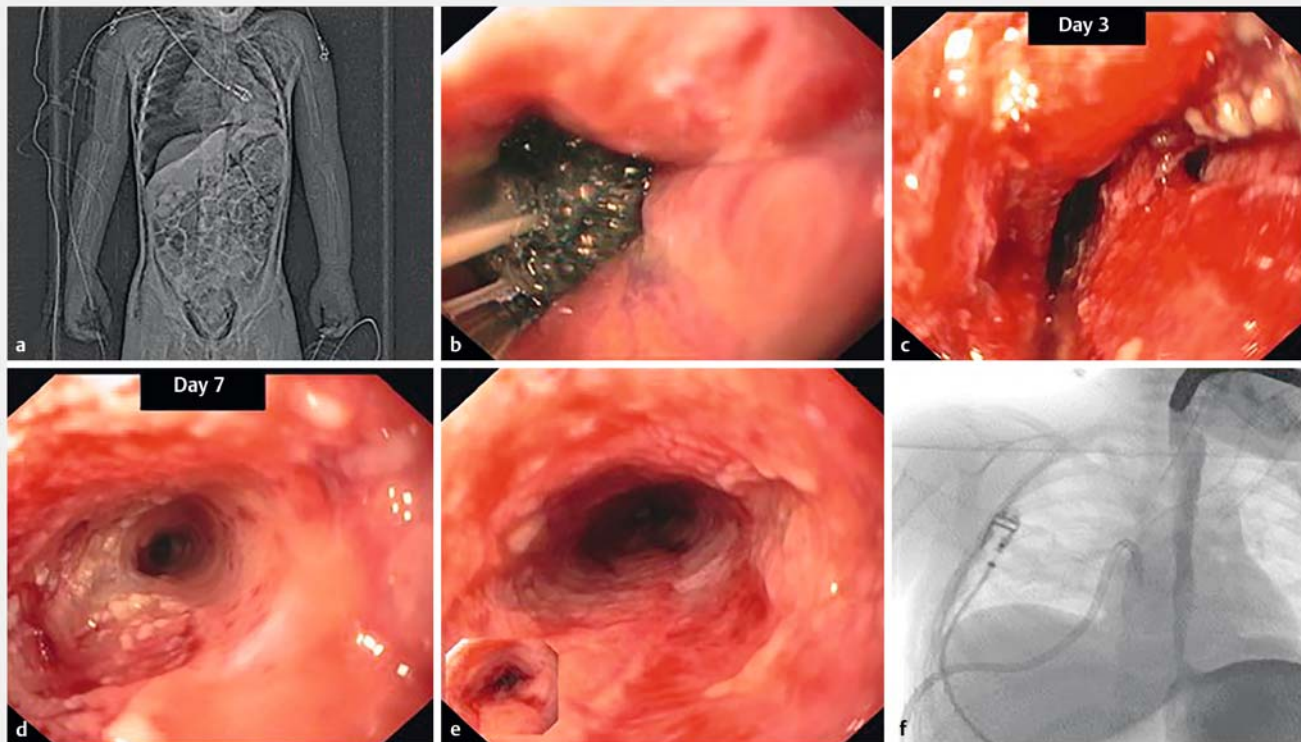


► **Fig. 2** Perforation of the upper esophagus after ingestion of a pen. **a** The pen was captured with a snare. **b** Perforation after removal of the pen. **c** Intraluminal placement of the sponge just below the upper esophageal sphincter. **d** Perforation closure endoscopically confirmed.

► **VIDEO**

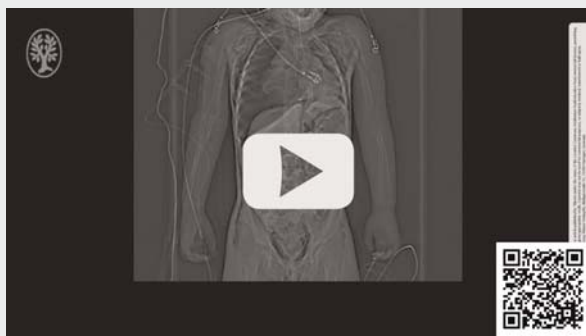


► **Video 1** Management with EVT of an acute perforation of the upper esophagus that occurred after ingestion of a pen.



► **Fig. 3** Perforation of the middle esophagus in a child with caustic stricture. **a** CT scan topogram of a tension pneumothorax. **b** Intraluminal placement of the sponge. **c** Site of perforation on Day 3. **d** Perforation closure on Day 7. **e** End of EVT on Day 10. **f** Complete closure documented after injection of contrast through the scope in the esophagus.

VIDEO



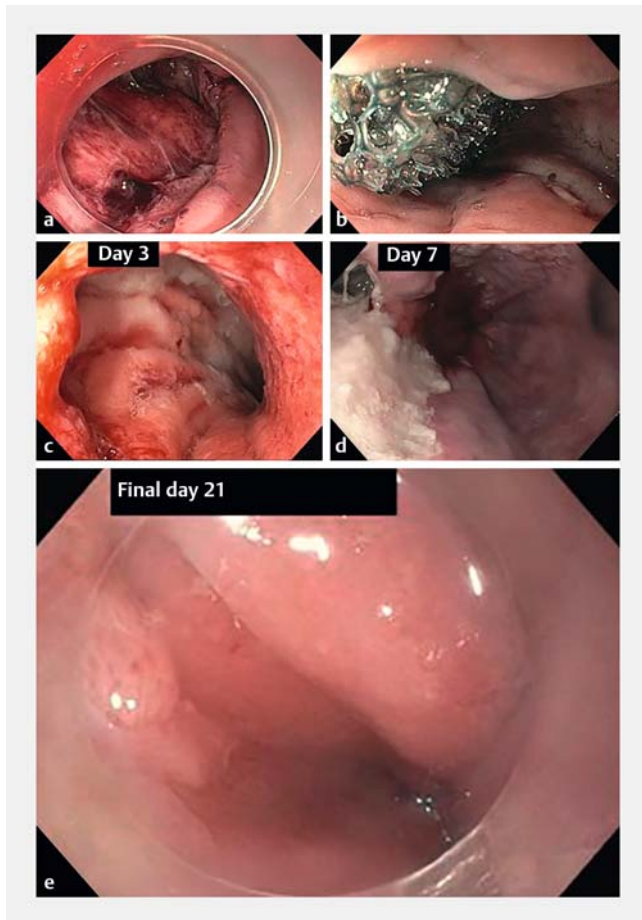
► **Video 2** Management with EVT of an acute iatrogenic perforation of the middle esophagus that occurred during diagnostic gastroscopy in a child with caustic stricture.

confirmed endoscopically. No procedure-related complication has been documented. Clinical follow-up data are available for all 10 patients (median 8 months, IQR 1.3–18.3). Sufficient oral intake confirmed the good clinical course in all of them.

Discussion

Esophageal perforation remains a challenging clinical condition with no treatment consensus so far. Current guidelines from the European Society of Gastrointestinal Endoscopy recommend a first-step endoscopic approach over surgery [2]. A high mortality rate is the major concern about surgery. Open surgery for esophageal perforation has a reported overall mortality rate of around 20% [6]. A systematic review of non-comparative studies also showed a mortality rate of 17% with surgical management, whereas SEMS placement had a mortality rate of 7.5% [7].

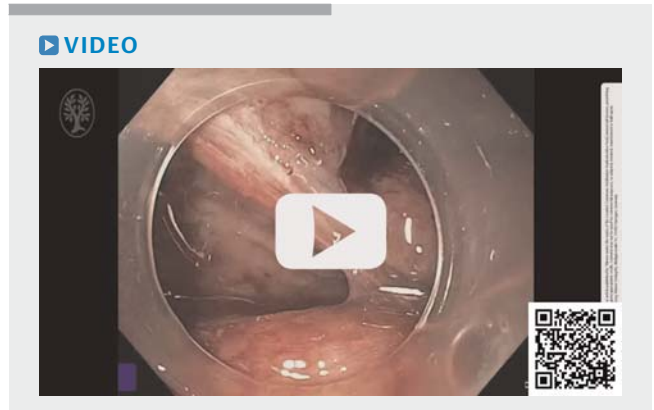
While TTS and OTSC are supposed to be a good option for rather smaller defects [8], for many years, SEMS placement has been the main alternative to surgery, especially for larger defects [2]. In recent years, EVT has emerged as a definitive treatment of esophageal perforation and many retrospective studies and case reports have reported very encouraging success rates, as shown in ► **Table 3** [3–5, 9–16]. According to a meta-analysis by Jung et al., EVT has a significantly higher closure rate and a lower mortality rate than SEMS placement [17]. However, their data were extracted from retrospective studies with almost exclusively anastomotic leaks. To the best of our knowledge, there is only one comparative study, which included only two patients with perforations in the EVT arm and eight patients with perforations in the SEMS arm [18]. That study demonstrated promising results in favor of EVT compared with



► **Fig. 4** Perforation of the lower esophagus after pneumatic balloon dilation for achalasia. **a** Large perforation with a mediastinal cavity at an early stage (Day 0). **b** Intracavitary placement of the sponge. **c** Condition after 3 days of EVT. **d** Smaller perforation defect after 7 days of EVT. **e** Perforation closure endoscopically confirmed.

SEMS, regarding closure rate (84.4% vs 53.8%) and stricture rate (9.4% vs 28.2%). Thus, to date, there are very limited comparative data for EVT and SEMS or other endoscopic treatments in the setting of esophageal perforation. Besides the well-known complications of SEMS, including stent migration and tissue overgrowth, the main clinical concern about SEMS, from our perspective, remains the inability to perform endoscopic lavage and to drain the wound cavity, as well as to control the healing process, as can be done during every sponge change.

Our retrospective analysis showed complete perforation closure in all patients ($n = 10/10$, 100%) using only EVT. This very promising outcome is comparable to the results of the other, mostly retrospective studies (57.1%–100%) [3–5,9–16]. The results of these retrospective studies are difficult to compare due to the different clinical settings and therapeutic algorithms used in each center. In the study of Ooi et al., EVT was initiated only due to failure of other treatments, which included surgery and placement of external drains, endoscopic closure, and percutaneous external drainage [11]. This might have led to the lower success rate of 60%.



► **Video 3** Management with EVT of an acute iatrogenic perforation of the lower esophagus that occurred after pneumatic balloon dilation for achalasia.

Moreover, another well-known, important parameter for successful treatment is the time from perforation to initiation of EVT. Heits et al. reported that the length of EVT and hospital stay was significantly longer for patients with an interval of more than 24 hours before initiating EVT [16]. In our cohort, EVT was initiated immediately after perforation in eight of 10 cases, in one case the next day and in the last case after 2 days. This might explain the shorter duration and higher success rate of EVT in our study. Loske et al. also reported having started EVT immediately after diagnosis, which may contribute to complete closure in all patients and to short treatment duration of median 5 days [15]. In our cohort, therapy duration was slightly longer (median 7.5 days). Notably, our case in which EVT was started 2 days after perforation had the longest duration of therapy (21 days), which led to an increase in the median value for treatment duration in our series.

Furthermore, in our case series, intraluminal placement of the sponge, for the most part, was sufficient for defect closure, except in two patients in whom the sponge was placed initially intracavitary. In keeping with previous series, we suggest intraluminal placement of the sponge at an early stage after perforation and intracavitary placement for larger perforations or when perforation is diagnosed late, which often is associated with mediastinal fluid collection [13, 15].

Conclusions

In conclusion, our data confirm promising results with EVT for acute esophageal perforation published so far. EVT seems to be an effective and safe definitive treatment option, provided that perforation is early detected and a patient's healing process is evaluated every 3 to 4 days.

► **Table 3** EVT for esophageal perforations.

Author	Journal	Pa-tients	De-fect size, mm	Success rate, n (%)	Mortal-ity rate, n (%)	Complica-tion rate, n (%)	Days after per-fo-ration to sponge place-ment	Spong-e chang-es, n, medi-an	Dura-tion of therapy, days, median	Posi-tion of the sponge
Mastoridis et al.[9]	Minim Inva-sive Ther Allied Technol. 2020	3	NA	3 (100)	0 (0)	0/3 (0)	1 (0–8)	3	13	IL 3/ IC 0
Jung et al. [4]	Digestion 2020	7	NA	5 (71.4)/ 4 (57.1) ¹	1 (14.3)	NA	NA	6.4	25.5	IL 4/ IC 3
Leeds et al.[5]	J. Gastrointest. Surg. 2019	17	NA	16 (94)	NA	NA	12.8	5.2	23.8	NA
Bludau et al.[3]	Surg. Endosc. 2018	18	NA	13 (72.2)	3 (16.7)	NA	NA	2.8 ² / 4.5 ³	8.8 ² / 15.6 ³	IL 14/ IC 5 ⁴
Pournaras et al.[10]	World J. Surg. 2018	14	NA	13 (92.9)	2 (14.9)	NA	NA	NA	NA	NA
Ooi et al. [11]	ANZ J. Surg. 2018	5	20	3 (60)	1 (20)	NA	5	6	20	NA
Laukoetter et al. [12]	Surg. Endosc. 2017	13	NA	49 (94.2)/ 42 (80.8) ^{1,5}	0	0	5 ² /5.5 ³	6 ² /5 ³	23.5 ² / 25 ³	NA
Kuehn et al.[13]	J. Gastrointest. Surg. 2016	10	NA	10 (100)	NA	0	NA	5	15	NA
Moschler et al.[14]	Endosc. Int. Open 2015	5	NA	5 (100)	NA	NA	NA	0 (range 0–6)	5	IL 3/ IC 2
Loske et al.[15]	Endosc. Int. Open 2015	10	12,5	10 (100)	0	0	0	1	5	IL 8/ IC 2
Heits et al. [16]	Ann. Thorac. Surg. 2014	10	NA	9 (90)/ 7 (70) ¹	1 (10)	7 (70)	NA	5.4	NA	NA

EVT, endoscopic vacuum therapy; NA, not available; IL, intraluminal; IC, intracavitary.

¹ EVT alone.

² spontaneous perforations.

³ Iatrogenic perforations.

⁴ Combination possible.

⁵ Overall success, not separately for perforations.

Competing interests

The authors declare that they have no conflict of interest.

References

- [1] Sdralis EIK, Petousis S, Rashid F et al. Epidemiology, diagnosis, and management of esophageal perforations: systematic review. *Dis Esophagus* 2017; 30: 1–6
- [2] Paspatis GA, Arvanitakis M, Dumonceau JM et al. Diagnosis and management of iatrogenic endoscopic perforations: European Society of Gastrointestinal Endoscopy (ESGE) Position Statement – Update 2020. *Endoscopy* 2020; 52: 792–810
- [3] Bludau M, Fuchs HF, Herbold T et al. Results of endoscopic vacuum-assisted closure device for treatment of upper GI leaks. *Surg Endosc* 2018; 32: 1906–1914
- [4] Jung CFM, Müller-Dornieden A, Gaedcke J et al. Impact of endoscopic vacuum therapy with low negative pressure for esophageal perforations and postoperative anastomotic esophageal leaks. *Digestion* 2021; 102: 469–479
- [5] Leeds SG, Mencio M, Ontiveros E et al. Endoluminal vacuum therapy: How I do it. *J Gastrointest Surg* 2019; 23: 1037–1043
- [6] Brinster CJ, Singhal S, Lee L et al. Evolving options in the management of esophageal perforation. *Ann Thorac Surg* 2004; 77: 1475–1483

- [7] Persson S, Rouvelas I, Irino T et al. Outcomes following the main treatment options in patients with a leaking esophagus: a systematic literature review. *Dis Esophagus* 2017; 30: 1–10
- [8] Lee HL, Cho JY, Cho JH et al. Efficacy of the over-the-scope clip system for treatment of gastrointestinal fistulas, leaks, and perforations: a Korean multi-center study. *Clin Endosc* 2018; 51: 61–65
- [9] Mastoridis S, Chana P, Singh M et al. Endoscopic vacuum therapy (EVT) in the management of oesophageal perforations and post-operative leaks. *Minim Invasive Ther Allied Technol* 2020; 10: 1–9
- [10] Pournaras DJ, Hardwick RH, Safranek PM et al. Endoluminal vacuum therapy (E-Vac): a treatment option in oesophagogastric surgery. *World J Surg* 2018; 42: 2507–2511
- [11] Ooi G, Burton P, Packiyathan A et al. Indications and efficacy of endoscopic vacuum-assisted closure therapy for upper gastrointestinal perforations. *ANZ J Surg* 2018; 88: E257–E263
- [12] Laukoetter MG, Mennigen R, Neumann PA et al. Successful closure of defects in the upper gastrointestinal tract by endoscopic vacuum therapy (EVT): a prospective cohort study. *Surg Endosc* 2017; 31: 2687–2696
- [13] Kuehn F, Schiffmann L, Janisch F et al. Surgical endoscopic vacuum therapy for defects of the upper gastrointestinal tract. *J Gastrointest Surg* 2016; 20: 237–243
- [14] Möschler O, Nies C, Mueller MK. Endoscopic vacuum therapy for esophageal perforations and leakages. *Endosc Int Open* 2015; 3: E554–E558
- [15] Loske G, Schorsch T, Dahm C et al. Iatrogenic perforation of esophagus successfully treated with Endoscopic Vacuum Therapy (EVT). *Endosc Int Open* 2015; 3: E547–E551
- [16] Heits N, Stapel L, Reichert B et al. Endoscopic endoluminal vacuum therapy in esophageal perforation. *Ann Thorac Surg* 2014; 97: 1029–1035
- [17] Jung DH, Yun HR, Lee SJ et al. Endoscopic vacuum therapy in patients with transmural defects of the upper gastrointestinal tract: a systematic review with meta-analysis. *J Clin Med* 2021; 10(11): 2346
- [18] Brangewitz M, Voigtländer T, Helfritz FA et al. Endoscopic closure of esophageal intrathoracic leaks: stent versus endoscopic vacuum-assisted closure, a retrospective analysis. *Endoscopy* 2013; 45: 433–438