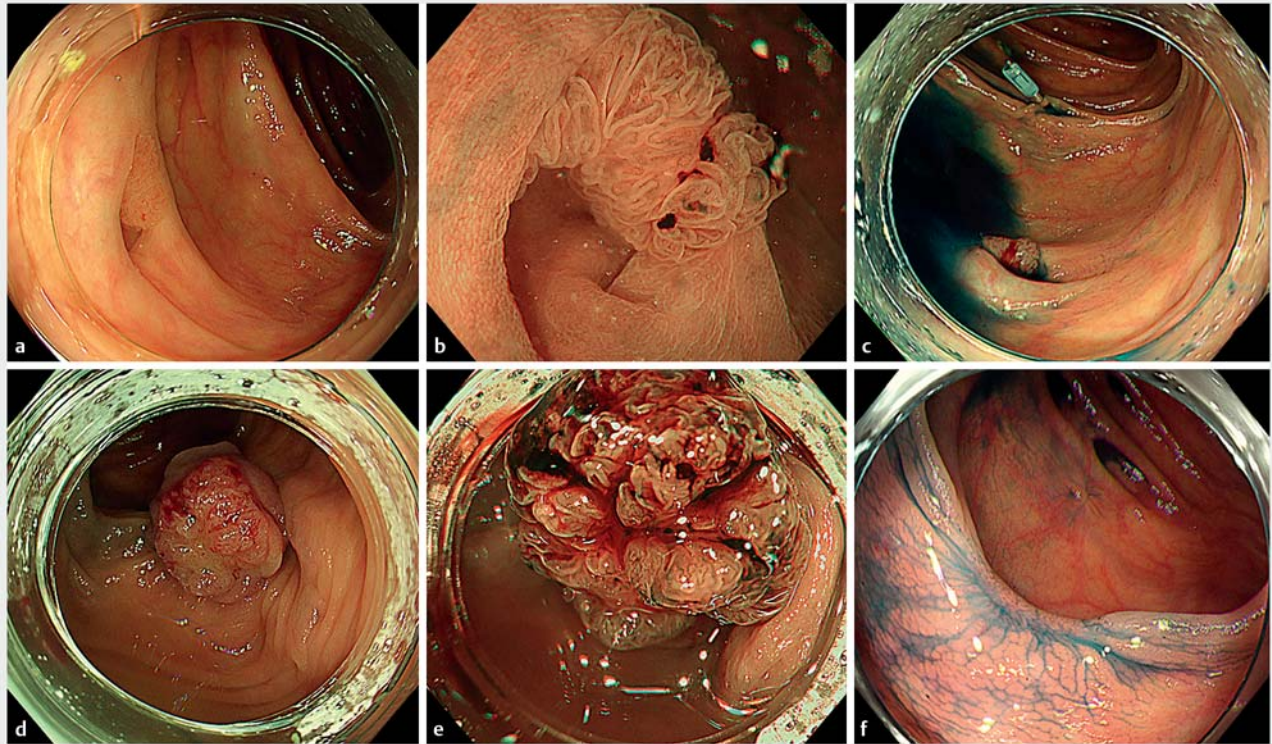
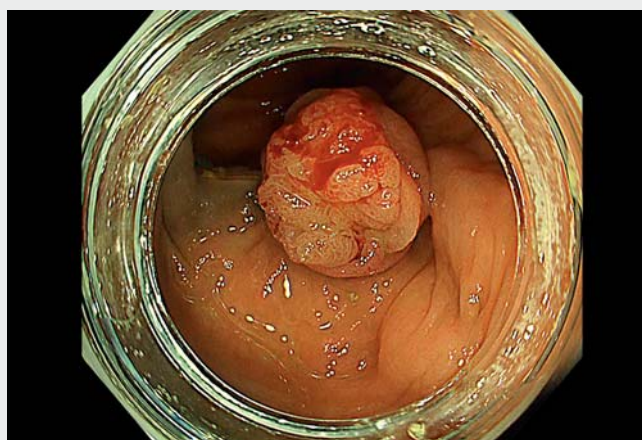


## Endoscopic band ligation for the removal of colonic polyp invading the diverticulum



**► Fig. 1** Before and after endoscopic band ligation (EBL) for the removal of a colonic polyp invading the diverticulum. **a** On the day of EBL, a 5-mm Ila lesion invading the diverticulum of ascending colon was identified. **b** Magnified endoscopy showed Japan NBI Expert Team (JNET) type 2A. **c** A marking clip was placed at the oral side of the lesion. **d** After EBL, the lesion was 15-mm Ila. **e** Magnified endoscopy showed JNET 2A. **f** At follow-up, 3 months after EBL, no remnant was found.

Endoscopic mucosal resection (EMR) is one of the primary treatment approaches for colonic polyps [1, 2]. However, polyps invading the colonic diverticulum are difficult to identify on whole endoscopic images, making EMR or endoscopic submucosal dissection (ESD) difficult. Moreover, perforation may occur during EMR or ESD for this type of polyp. Endoscopic full-thickness resection can be an alternative approach, albeit costly. Endoscopic band ligation (EBL) is a simple and effective modality to prevent colonic diverticular hemorrhage [3–5]. Here, we present the utility of EBL for the removal of colonic polyps invading the diverticulum. A 5-mm Ila lesion invading the diverticulum was identified in the ascending colon. Initially, as much of the visible por-



**► Video 1** Endoscopic band ligation for the removal of a colonic polyp invading the diverticulum of the ascending colon.

tion as possible was removed with cold snare polypectomy (CSP) and cold forceps polypectomy (CFP). Thereafter, a pathological diagnosis of tubulovillous adenoma was established. Approximately 6 months after CSP and CFP, the polyp had not disappeared and almost retained its original shape (► Fig. 1 a, b). After placement of a marking clip (► Fig. 1 c), EBL was performed with lower endoscopy (PCF-H290Z; Olympus Medical Systems, Tokyo, Japan) and an EBL device (MD-48912B; Sumitomo Bakelite Co., Ltd., Tokyo, Japan) (► Fig. 1 d, ► Video 1). EBL allowed the whole polyp to be clearly visualized. The polyp was a 15-mm Ila lesion of Japan NBI Expert Team (JNET) type 2A (► Fig. 1 e). Biopsy was performed on the polyp after EBL to confirm the pathological findings. The results of the biopsy revealed a tubulovillous adenoma. At follow-up 3 months after EBL, the polyp and diverticulum had completely disappeared (► Fig. 1 f). The biopsy from the scar showed no tumor remnant.



EBL for the removal of colonic polyp invading the diverticulum was thought to be effective and minimally invasive. As an entire specimen cannot be obtained with EBL, preoperative biopsy and/or evaluation with magnified endoscopy should be performed.

Endoscopy\_UCTN\_Code\_TTT\_1AQ\_2AD

## Competing interests

The authors declare that they have no conflict of interest.

## The authors

**Kenichiro Okimoto** , **Tomoaki Matsumura** , **Naoki Akizue**, **Yuki Ohta**, **Takashi Taida**, **Jun Kato**, **Naoya Kato**

Department of Gastroenterology, Graduate School of Medicine, Chiba University, Chiba, Japan

## Corresponding author

**Kenichiro Okimoto, MD**

Department of Gastroenterology, Graduate School of Medicine, Chiba University, Inohana 1-8-1, Chiba City, 260-8670, Japan  
okimoto-k@chiba-u.jp

## References

- [1] Kudo S. Endoscopic mucosal resection of flat and depressed types of early colorectal cancer. *Endoscopy* 1993; 25: 455–461
- [2] Yokota T, Sugihara K, Yoshida S. Endoscopic mucosal resection for colorectal neoplastic lesions. *Dis Colon Rectum* 1994; 37: 1108–1111
- [3] Farrell JJ, Graeme-Cook F, Kelsey PB. Treatment of bleeding colonic diverticula by endoscopic band ligation: an in-vivo and ex-vivo pilot study. *Endoscopy* 2003; 35: 823–829
- [4] Ishii N, Itoh T, Uemura M et al. Endoscopic band ligation with a water-jet scope for the treatment of colonic diverticular hemorrhage. *Dig Endosc* 2010; 22: 232–235
- [5] Nakano K, Ishii N, Ikeya T et al. Comparison of long-term outcomes between endoscopic band ligation and endoscopic clipping for colonic diverticular hemorrhage. *Endosc Int Open* 2015; 3: E529–E533

## Bibliography

*Endoscopy* 2022; 54: E713–E714

DOI 10.1055/a-1769-4897

ISSN 0013-726X

published online 28.2.2022

© 2022. Thieme. All rights reserved.

Georg Thieme Verlag KG, Rüdigerstraße 14, 70469 Stuttgart, Germany

**ENDOSCOPY E-VIDEOS**  
<https://eref.thieme.de/e-videos>



*Endoscopy E-Videos* is an open access online section, reporting on interesting cases

and new techniques in gastroenterological endoscopy. All papers include a high quality video and all contributions are freely accessible online. Processing charges apply (currently EUR 375), discounts and waivers acc. to HINARI are available.

This section has its own submission website at  
<https://mc.manuscriptcentral.com/e-videos>