

Analysis of the Thickness of the Outer Retinal Layer Using Optical Coherence Tomography – A Predictor of Visual Acuity in Schizophrenia

Analyse der äußeren Netzhautschichtdicke als Prädiktor der Sehschärfe mittels optischer Kohärenztomografie bei Schizophrenie

Authors

Erman Bozali, Duygu Yalinbas 

Affiliation

Sivas Cumhuriyet University Faculty of Medicine, Department of Ophthalmology, Sivas, Turkey

Key words

schizophrenia, optical coherence tomography, outer retinal layer thickness

Schlüsselwörter

Schizophrenie, optische Kohärenztomografie, Dicke der äußeren Netzhautschicht

received 3. 10. 2021
accepted 13. 1. 2022
published online 23. 3. 2022

Bibliography

Klin Monatsbl Augenheilkd 2022; 239: 1232–1238

DOI 10.1055/a-1741-7988

ISSN 0023-2165

© 2022, Thieme. All rights reserved.

Georg Thieme Verlag KG, Rüdigerstraße 14,
70469 Stuttgart, Germany

Correspondence

Dr. Erman Bozali

Sivas Cumhuriyet University, Faculty of Medicine, Department of Ophthalmology, 58140 Sivas, Turkey

Phone: +90 54 45 17 99 84, Fax: +90 34 62 19 11 55

ermanbozali@gmail.com

ABSTRACT

Background The aim of this study was to evaluate the thickness of the outer retinal layer (ORL) together with macular thickness and changes in the retinal nerve fiber layer (RNFL) in patients with schizophrenia in comparison with healthy controls.

Methods This study included 114 eyes of 57 patients diagnosed with schizophrenia and 114 eyes of 57 healthy controls.

Central foveal thickness (CFT), central macular thickness (CMT), and ORL thickness were measured in both groups via the images obtained by spectral-domain optical coherence tomography (SD-OCT). RNFL was also assessed in four quadrants (inferior, superior, temporal, nasal). CMT measurements were presented as the average thickness of the macula in the central 1 mm area on the Early Treatment Diabetic Retinopathy Study (ETDRS) grid. The ORL thickness was defined as the distance between the external limiting membrane and retinal pigment epithelium at the center of the foveal pit.

Results The mean age of 57 patients was 37 ± 10 years, of whom 34 (60%) were male and 23 (40%) female. No statistically significant difference was found between groups in terms of age and gender ($p = 0.8$ for age, $p = 0.9$ for gender). There was no statistically significant difference in the mean CMT between the two groups ($p = 0.1$). The mean ORL thickness in the two groups was 99.8 ± 8.3 and 103.7 ± 6.2 , respectively, and was significantly decreased in the schizophrenia group ($p = 0.005$). RNFL analysis demonstrated significant thinning in the inferior and superior quadrants compared to healthy controls ($p < 0.001$ and $p = 0.017$, respectively).

Conclusions SD-OCT findings – especially ORL and RNFL thickness – may be related to the neurodegenerational changes in schizophrenia.

ZUSAMMENFASSUNG

Hintergrund Das Ziel dieser Studie war es, die Dicke der äußeren Netzhautschicht (ORL) zusammen mit der Makuladicke und Veränderungen in der retinalen Nervenfaserschicht (RNFL) bei Patienten mit Schizophrenie im Vergleich zur gesunden Kontrollgruppe zu bewerten.

Methoden Diese Studie umfasste 114 Augen von 57 Patienten mit diagnostizierter Schizophrenie und 114 Augen von 57 gesunden Kontrollpersonen. Die Dicke der zentralen Fovea (CFT), die Dicke der zentralen Makula (CMT) und die ORL-Dicke wurden in beiden Gruppen über die Bilder gemessen, die durch optische Kohärenztomografie im Spektralbereich (SD-OCT) erhalten wurden. RNFL wurde auch in 4 Quadranten

(untere, obere, temporale, nasale) beurteilt. CMT-Messungen wurden als durchschnittliche Dicke der Makula im zentralen 1-mm-Bereich im Raster der Early Treatment Diabetic Retinopathy Study (ETDRS) dargestellt. Die ORL-Dicke wurde als der Abstand zwischen der äußeren Grenzmembran und dem retinalen Pigmentepithel im Zentrum der Foveagrube definiert.

Ergebnisse Das Durchschnittsalter von 57 Patienten betrug 37 ± 10 Jahre, davon waren 34 (60%) männlich und 23 (40%) weiblich. Es wurde kein statistisch signifikanter Unterschied zwischen den Gruppen in Bezug auf Alter und Geschlecht gefunden ($p = 0,8$ für Alter, $p = 0,9$ für Geschlecht). Es gab kei-

nen statistisch signifikanten Unterschied in der mittleren CMT zwischen den beiden Gruppen ($p = 0,1$). Die mittlere ORL-Dicke in den beiden Gruppen betrug $99,8 \pm 8,3$ und $103,7 \pm 6,2$ und war in der Schizophreniegruppe signifikant verringert ($p = 0,005$). Die RNFL-Analyse zeigte eine signifikante Ausdünnung im unteren und oberen Quadranten im Vergleich zu gesunden Kontrollen ($p < 0,001$ bzw. $p = 0,017$).

Schlussfolgerungen Die SD-OCT-Befunde – insbesondere die ORL und RNFL-Dicke – können mit den neurodegenerativen Veränderungen bei Schizophrenie zusammenhängen.

Introduction

Schizophrenia is a severe chronic debilitating mental disorder of early adulthood causing a lifelong healthcare burden that has a prevalence of about 1%. The pathophysiology of the disease remains obscure. Based on clinical assessment, the diagnosis of schizophrenia consists of positive, negative, and cognitive symptoms [1].

Neuroectoderm gives rise to the retina as well as the brain, which is the sole component of the central nervous system that can be observed with the naked eye in its natural state in living organisms [2]. Several studies revealed that in patients with schizophrenia, magnetic resonance imaging demonstrates enlarged ventricles and a decrease in total brain volume, especially in multiple gray matter regions [3]. However, it is interesting to note that spectral-domain optical coherence tomography (SD-OCT) parameters have been shown to be in correlation with intracranial volume, even in healthy subjects [4]. Furthermore, electrophysiological studies reported numerous electroretinogram (ERG) abnormalities. Moghimi et al. reported decreased b wave amplitudes in the photopic negative response (PhNR) of the light-adapted flash-electroretinogram (PhNR-fERG) compared to healthy controls [5]. The abnormal biopathological retinal findings including decreased ERG wave amplitudes and reduced macular volume in schizophrenia patients are appraised as potential biomarkers that may assist in the early identification of at-risk individuals and facilitate early treatment options [6].

SD-OCT is a noninvasive high depth and resolution imaging technique used to gather cross-sectional images of the retina and the optic disc. Recent evolution and advancement of SD-OCT scan resolution favored measurements of individual retinal layers such as the outer retinal layer (ORL) thickness. The ORL thickness consists of the myoid, ellipsoid zone, outer segment of photoreceptors, and interdigitating zone. The photoreceptor layer, a portion of the outer retina, contributes spatial information in the course of visual processing [7]. Deterioration in visual function following the disruption of photoreceptors and the ellipsoid zone has been demonstrated [8]. It is noteworthy that the literature encloses some controversial studies regarding the correlation between macular thickness and visual acuity. Several studies reported moderate to strong correlations between macular thickness and visual acuity, however, some reported weak or no correlation [9–12], given the fact that the alterations or disruption of

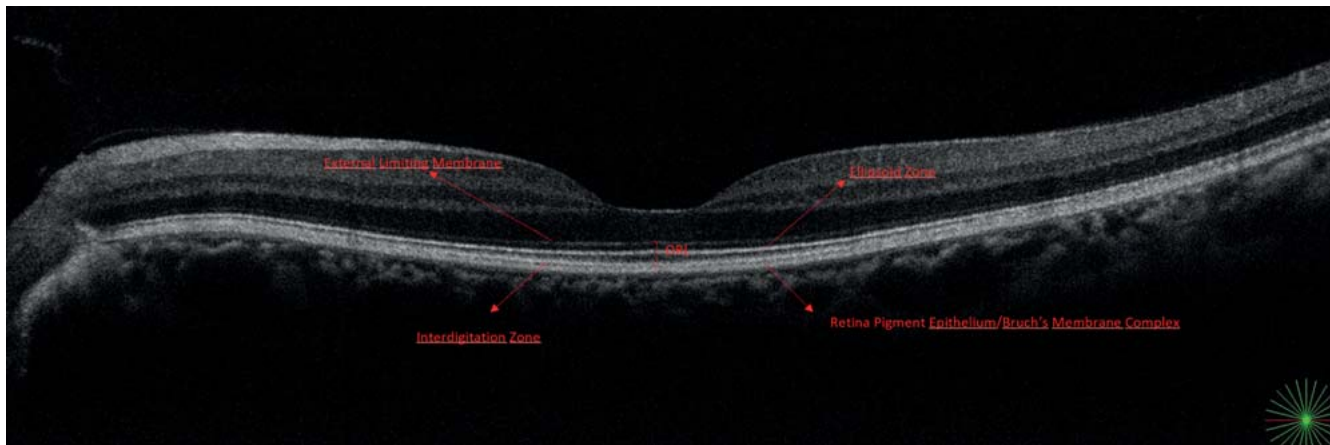
particular retinal sublayers, including ORL, may be associated with visual acuity.

SD-OCT has also been used to evaluate the retinal nerve fiber layer (RNFL) in a variety of diseases, including neurodegenerative disorders like multiple sclerosis, Parkinson's, and Alzheimer's disease [4, 13, 14]. A meta-analysis concerning schizophrenia and bipolar disease demonstrated a significant thinning in RNFL compared to healthy controls [15]. However, in some studies, SD-OCT findings in schizophrenia patients remain controversial and demonstrate either confined alterations or no changes at all [16–18]. To the best of our knowledge, this is the first study evaluating ORL thickness in patients with schizophrenia alongside other retinal structural changes in OCT.

The aim of this study was to investigate the association between the occurrence and nonoccurrence of schizophrenia on the retinal structures, especially on ORL and RNFL thickness alongside other SD-OCT parameters such as macular thickness, and to identify retinal potential biomarkers that could be correlated with schizophrenia.

Materials and Methods

A total of 114 eyes of 57 patients diagnosed with schizophrenia and 114 eyes of 57 age- and gender-matched healthy control subjects was included in this retrospective study. Patients were diagnosed with schizophrenia according to the Diagnostic and Statistical Manual of Mental Disorders, Fifth Edition (DSM-5), criteria by an experienced and certified psychiatrist [19]. This study adheres to the tenets of the Declaration of Helsinki and approval of the local Ethics Committee of Sivas Cumhuriyet University Faculty of Medicine was obtained. Demographic data of the subjects and a comprehensive ophthalmic examination including best-corrected visual acuity, intraocular pressure measurement, slit lamp biomicroscopy findings of anterior or posterior segments, and SD-OCT images were obtained from the medical records of the participants. All OCT image acquisition was done in the same hospital by a single experienced technician on the same day following the aforementioned examinations after the dilation of the pupils with tropicamide 0.5% eye drops. Based on the quality scoring of the images obtained by the SD-OCT, only the scans meeting the signal strength of 6 and above were included in the study. The central foveal thickness (CFT), central macular thickness (CMT), and ORL thickness were measured in both groups via the images ob-



► Fig. 1 Representative SD-OCT image of retinal structures and measurement method.

tained using an SD-OCT device (Nidek RS-3000 Advance, Gama-gori, Japan) with software version 1.5.1. Peripapillary RNFL scans were obtained using the Disc Map method with eye tracking, which performs a centered scan on the optic nerve head in a $6 \times 6 \text{ mm}^2$ field. For the macular measurements, the macula radial method with eye tracking, which utilizes 12 radial cross-sectional images of the macula centered on the foveal pit, was used. Ellipsoid zone (EZ) integrity was also assessed via evaluating any EZ disruptions in all 12 radial scans. All measurements were performed by an experienced ophthalmologist (E.B.) who was masked to the diagnosis of the patients. CMT measurements were presented as the average thickness of the macula in the central 1 mm area on the Early Treatment Diabetic Retinopathy Study (ETDRS) grid. The ORL thickness was defined as the distance between the external limiting membrane and retinal pigment epithelium at the center of the foveal pit. Representative segmentations of external limiting membrane (ELM) and retinal pigment epithelium (RPE) on SD-OCT images and the manual measurement method are shown in ► Fig. 1. RNFL thickness was also assessed in four quadrants (inferior, superior, nasal, temporal). The inclusion criteria were as follows: participants with a refractive error of ± 3.0 diopters or less, intraocular pressure less than 21 mmHg, and no present optic disc or macular pathology. Participants with ocular pathologies including macular degeneration, any retinopathies, optic neuropathies, glaucoma, or history of ocular trauma, or any ocular surgery that might interfere with the OCT measurements were excluded from the study. Participants with known systemic or inflammatory diseases such as diabetes mellitus, media opacities intercepting ophthalmic examination, or OCT scans and who had more than ± 3.0 diopters of refractive error were also excluded from the study.

Statistical Analysis

Analyses were performed with Statistical Package for the Social Science (SPSS version 20.0. IBM Corp., Armonk, NY) software for Windows. The data distribution was determined using the Kolmogorov-Smirnov test. The homogeneity of variables was determined using the one-way ANOVA homogeneity of variance test.

Continuous variables are reported as means \pm standard deviation. Categorical variables are reported by percentages. No statistically significant difference was determined between the two eyes of the participants in terms of ORL thickness, CFT, CMT, and RNFL thickness. Therefore, the mean values of both eyes were used in the analysis. Since the parametric assumptions were fulfilled (Kolmogorov-Smirnov), the independent samples t-test was used to compare the measurements obtained from two independent groups. We also provided the t value with the 95% confidence interval of the difference. Cohen's d calculation was performed to determine the effect size of significant differences. Dots in the box and whisker graphs were depicted to convey the distribution of SD-OCT findings. The Mann-Whitney U Test was applied since the data of CMT, ORL, CFT, and RNFL in the temporal quadrant was not normally distributed. Independent samples t-test was applied since the RNFL inferior, superior, and nasal data was normally distributed. A value of $p < 0.05$ was considered statistically significant.

Results

In the schizophrenia group, the mean age of 57 patients was 37 ± 10 of whom 34 (60%) were male and 23 (40%) were female. No statistically significant difference was found between groups in terms of age and gender ($p = 0.8$ for age, $p = 0.9$ for gender). The best-corrected visual acuity was 20/20 in both groups. Demographics and patient characteristics are summarized in ► Table 1.

► Table 2 presents the SD-OCT findings of the participants. The mean CMT was $255.5 \pm 25.8 \mu\text{m}$ in the schizophrenia group and $262.2 \pm 17.6 \mu\text{m}$ in the control group ($p = 0.1$). The mean ORL thickness was $99.8 \pm 8.3 \mu\text{m}$ and significantly lower in the schizophrenia group compared to $103.7 \pm 6.2 \mu\text{m}$ in the control group with a medium effect size ($p = 0.005$; Cohen's $d = 0.490368$). The mean RNFL thickness in the inferior quadrant was $126.5 \pm 16.9 \mu\text{m}$ in the schizophrenia group and $138.1 \pm 15.1 \mu\text{m}$ in the control group and the difference was significant with a medium effect size ($p < 0.001$; Cohen's $d = 0.723856$). The mean RNFL thickness in the superior quadrant was $127.1 \pm 17.7 \mu\text{m}$ in the schizophrenia group and that of the controls was

► **Table 1** Demographics of the study population.

	Schizophrenia group (n = 57)	Control group (n = 57)	t value (95% confidence interval of the difference)	p value
Age, y (mean ± SD)	37.2 ± 9.9	36.8 ± 9.6	0.220 (– 3.228 and 4.035)	0.8
Gender (F/M)	23/34	24/33	NA	0.9
Medical treatment (%/n)				
▪ Clozapine	31.6% (n = 18)	NA	NA	NA
▪ Quetiapine	19.2% (n = 11)	NA	NA	NA
▪ Risperidone	17.5% (n = 10)	NA	NA	NA
▪ Aripiprazole	15.7% (n = 9)	NA	NA	NA
▪ Sulpiride	12.3% (n = 7)	NA	NA	NA
▪ Olanzapine	10.5% (n = 6)	NA	NA	NA
▪ Zyklophenthol	7% (n = 4)	NA	NA	NA
▪ Paliperidone	7% (n = 4)	NA	NA	NA
▪ Haloperidol	5.2% (n = 3)	NA	NA	NA

F: female, M: male, NA: not applicable.

► **Table 2** Comparison of SD-OCT features of patients with schizophrenia and healthy controls.

	Schizophrenia group (n = 114 eyes) mean ± SD	Control group (n = 114 eyes) mean ± SD	t value (95% confidence interval of the difference)	p value
ORL thickness, μm	99.8 ± 8.3	103.7 ± 6.2	– 2.851 (– 6.708 and – 1.206)	0.005
CFT, μm	210 ± 18.2	213.4 ± 20.4	– 0.928 (– 10.777 and 3.903)	0.35
CMT, μm	255.5 ± 25.8	262.2 ± 17.6	– 1.632 (– 15.095 and 1.462)	0.1
Inferior RNFL, μm	126.5 ± 16.9	138.1 ± 15.1	– 3.789 (– 17.657 and – 5.528)	< 0.001
Superior RNFL, μm	127.1 ± 17.7	134.6 ± 14.9	– 2.415 (– 13.718 and – 1.349)	0.017
Nasal RNFL, μm	74.9 ± 13.4	76.6 ± 11.8	– 0.661 (– 6.383 and 3.189)	0.5
Temporal RNFL, μm	74.3 ± 19.6	73.1 ± 9.0	0.438 (– 4.451 and 6.978)	0.6

ORL: outer retinal layer, CFT: central foveal thickness, CMT: central macular thickness, RNFL: retinal nerve fiber layer

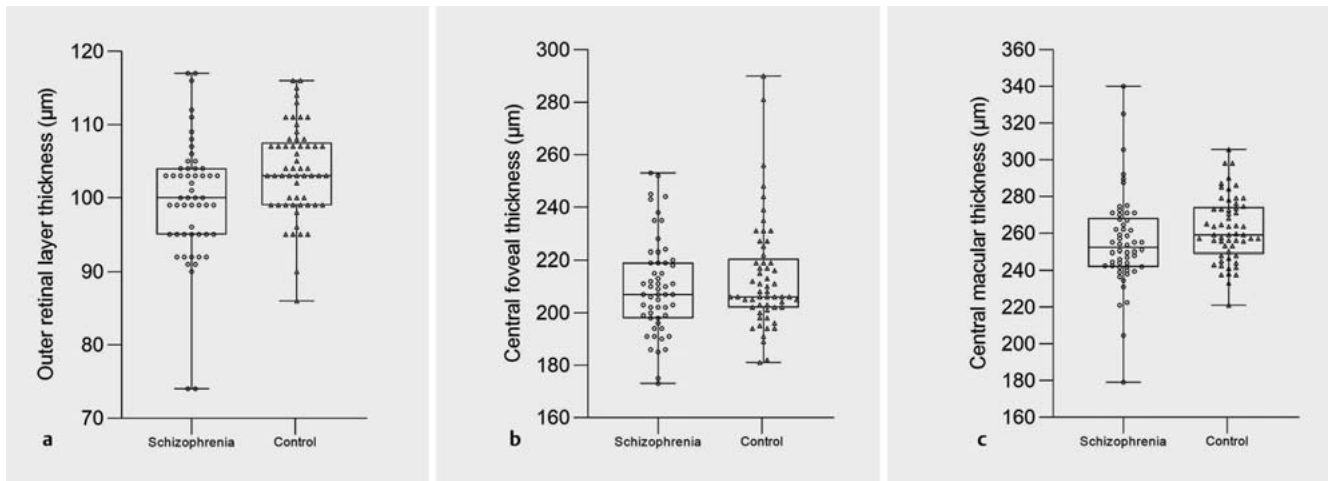
134.6 ± 14.9 μm and the difference was significant with a medium effect size ($p = 0.017$; Cohen's $d = 0.458435$). Although the RNFL analysis demonstrated a significant thinning in the inferior and superior quadrants in patients with schizophrenia, there was no significant difference in the temporal and nasal quadrants between groups. No impairment was observed regarding the EZ integrity in the patient group. The data distribution of the schizophrenia and control groups is demonstrated in ► **Fig. 2** and **3**.

Discussion

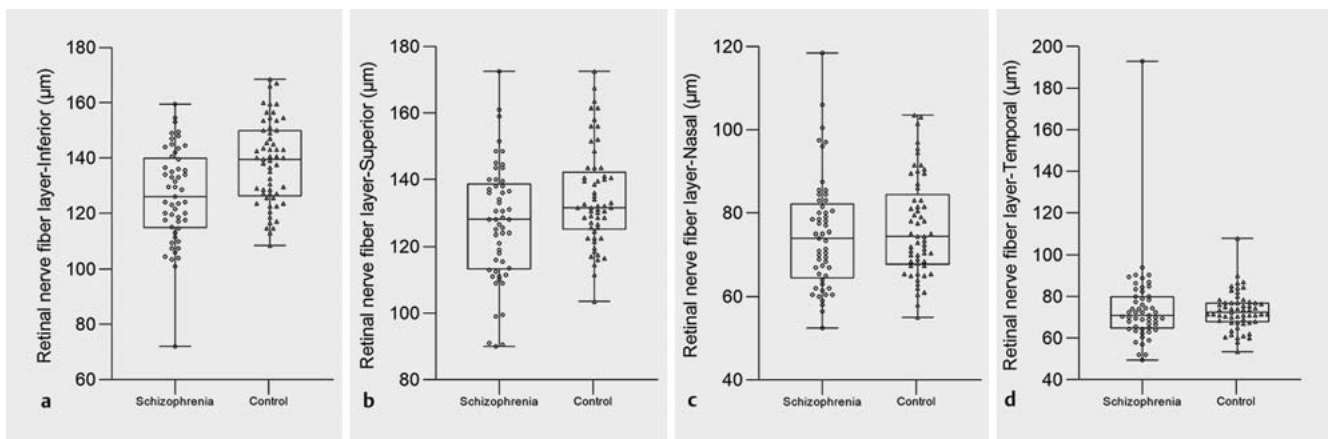
Schizophrenia is a debilitating neurodegenerative disorder. Deficits in visual processing is a substantial measure that needs to be taken seriously in patients with schizophrenia [20,21]. Evaluation of the retinal structures with SD-OCT may be useful to demonstrate the structural changes that may be associated with the def-

icits in visual perception and processing. In the current study, the ORL and peripapillary RNFL thickness were significantly thinner in patients with schizophrenia compared to healthy controls.

In the literature, there are studies evaluating RNFL and macular thickness in schizophrenia. Yilmaz et al. observed decreased overall and nasal RNFL thicknesses in schizophrenia patients [17]. Chu et al. investigated RNFL thickness and macular volume in patients with schizophrenia and observed no significant change regarding RNFL thickness and macular volume [18]. However, the authors stated that the findings of the study might be compromised since they used low-resolution OCT [18]. Ascaso et al. examined OCT findings of schizophrenia patients having a recent illness episode and compared them with healthy controls [16]. They observed only non-recent illness episode patients had significantly decreased macular volume and RNFL measurements. However, Cabezón et al. reported thinning only in peripapillary RNFL, not



► **Fig. 2** Distribution of data including (a) outer retinal layer thickness, (b) central foveal thickness, and (c) central macular thickness. Data are shown as the mean \pm SD.



► **Fig. 3** Distribution of data including retinal nerve fiber layer thickness in four quadrants (a inferior, b superior, c nasal, d temporal). Data are shown as the mean \pm SD.

in the macular region [22]. Samani et al. brought up a relatively diverse viewpoint on the subject where they segmented retinal layers and found that total retinal and photoreceptor complex thickness was reduced in schizophrenia patients [23]. In a recent study, Alizadeh et al. reported that patients with acute schizophrenia spectrum disorder showed the lowest macular thickness and largest atrophy in RNFL thickness [24]. Our findings correlate with the results of the aforementioned studies. We observed a significant reduction in RNFL thickness, especially in the inferior and superior quadrants, in schizophrenia patients compared to healthy controls. Nonetheless, differences in CFT and CMT were not statistically significant between the two groups. We also assessed ORL thickness, which has been found to be significantly lower in schizophrenia patients. Recent studies revealed that the inflammatory pathways play a significant role in the pathogenesis of schizophrenia [25]. Considering the progressive inflammation in schizophrenia over the years, this may result in a damage to the photoreceptors and even thinning in the ORL.

In schizophrenia patients, magnetic resonance imaging studies have revealed advancing reduction in the grey matter volume, especially as the disease progresses [26]. Braus et al. also observed widespread deficits in the cortical and subcortical brain regions [27]. This study is also in harmony with the current evidence in the literature that schizophrenia is a neurodegenerative disease [3]. Since the retina consists of neurons, such changes are likely to affect retinal structural integrity. On the other hand, the reduction of visual functions was found to be correlated with the disruption of the hyperreflective lines, mostly the EZ [28]. However, we did not observe any impairment in EZ integrity in the patient group. This result may be related to the relatively young age of our study population.

There are controversial outcomes in terms of the correlation between macular thickness and visual acuity. A previous study revealed a moderate correlation between visual acuity and foveal thickening [29]. On the other hand, correlation coefficients regarding the central retinal thickness and visual acuity have been

shown to be low [30]. In a study by Wong et al., they observed ORL thickness correlated more with visual acuity than the total retinal thickness [31]. Eliwa et al. observed reduced ORL thickness in patients with diabetic macular edema and determined a greater correlation with ORL thickness compared to central foveal point thickness regarding visual acuity [32]. In the current study, all participants had a best-corrected visual acuity of 20/20 since they were young or middle-aged adults. Hence, it is not amenable to point out a correlation between visual acuity and ORL thickness in our study population. However, it might be a potential indicator for possible imminent visual deficits during the progression of schizophrenia. There are several studies revealing the effects of oxidative stress and inflammation on the pathogenesis of schizophrenia [33,34]. A previous study conducted on experimental mice under induced oxidative stress revealed the death of photoreceptor cells and gradual decline in the ERG response and thinning of the outer nuclear layer with the help of SD-OCT [35]. Therefore, it is plausible that we observed a significant reduction in ORL thickness in schizophrenia patients. Taken together, our findings demonstrate the reduced ORL coheres with the aforementioned studies, considering ORL comprises both rod and cone photoreceptors and is in close relation with the outer nuclear layer.

There are limitations to this study. Since the study population consisted of mostly young and middle-aged adults, we were not able to correlate visual acuity with the reduction in ORL thickness since all patients had 20/20 visual acuity. The duration subsequent to the initial diagnosis of schizophrenia and the classification of the disease duration as acute or chronic was not considered. The chronicity of the disease may result in alterations of the findings. Besides, most of the patients were receiving psychotropic treatment at the time of participation in the study. Some of the patients were receiving multiple antipsychotic medications, therefore, evaluating the possible effect of each drug separately was not applicable. These medications might have interfered with the results.

Conclusion

The RNFL and ORL thicknesses were significantly lower in schizophrenia patients. The ORL thickness may be associated with visual deterioration during the course of the disease. Although we could not demonstrate an association between visual acuity and ORL thickness, long-term randomized studies with larger sample sizes are needed. Consequently, OCT may help facilitate the clinical diagnosis of schizophrenia and substantially may be considered as a potential early biomarker for monitoring the progressive neurodegeneration in schizophrenia. However, future studies evaluating OCT findings and their correlation with alterations of brain neuroimaging would be of benefit to determine retinal changes.

Conflict of Interest

The authors declare that they have no conflict of interest.

References

- [1] McCutcheon RA, Marques TR, Howes OD. Schizophrenia—An Overview. *JAMA Psychiatry* 2020; 77: 201–210
- [2] Silverstein SM, Rosen R. Schizophrenia and the eye. *Schizophr Res Cogn* 2015; 2: 46–55. doi:10.1016/j.scog.2015.03.004
- [3] Haukvik UK, Hartberg CB, Agartz I. Schizophrenia—what does structural MRI show? *Tidsskr Nor Laegeforen* 2013; 133: 850–853. doi:10.4045/tidsskr.12.1084
- [4] Saidha S, Sotirchos ES, Oh J et al. Relationships between retinal axonal and neuronal measures and global central nervous system pathology in multiple sclerosis. *JAMA Neurol* 2013; 70: 34–43. doi:10.1001/jamaneurol.2013.573
- [5] Moghimi P, Torres Jimenez N, McLoon LK et al. Electoretinographic evidence of retinal ganglion cell-dependent function in schizophrenia. *Schizophr Res* 2020; 219: 34–46. doi:10.1016/j.schres.2019.09.005
- [6] Adams SA, Nasrallah HA. Multiple retinal anomalies in schizophrenia. *Schizophr Res* 2018; 195: 3–12. doi:10.1016/j.schres.2017.07.018
- [7] Ye J, Shen M, Huang S et al. Visual Acuity in Pathological Myopia Is Correlated With the Photoreceptor Myoid and Ellipsoid Zone Thickness and Affected by Choroid Thickness. *Invest Ophthalmol Vis Sci* 2019; 60: 1714–1723. doi:10.1167/iovs.18-26086
- [8] Cheng C, Teo K, Tan CS et al. Myopic Retinoschisis in Asians: Structural Features and Determinants of Visual Acuity and Prognostic Factors for Progression. *Retina* 2016; 36: 717–726. doi:10.1097/iae.0000000000000757
- [9] Paovic J, Paovic P, Sredovic V. Correlation between Ocular Manifestations and Their Complications as Opposed to Visual Acuity and Treatment in Behçet's Disease. *Autoimmune Dis* 2013; 2013: 842673. doi:10.1155/2013/842673
- [10] Tran TH, de Smet MD, Bodaghi B et al. Uveitic macular oedema: correlation between optical coherence tomography patterns with visual acuity and fluorescein angiography. *Br J Ophthalmol* 2008; 92: 922–927. doi:10.1136/bjo.2007.136846
- [11] Takeuchi M, Iwasaki T, Kezuka T et al. Functional and morphological changes in the eyes of Behçet's patients with uveitis. *Acta Ophthalmol* 2010; 88: 257–262. doi:10.1111/j.1755-3768.2009.01536.x
- [12] Corrêa TP, Arantes TE, Lima VC et al. Structural evaluation of posterior pole in patients with Behçet's disease. *Arq Bras Oftalmol* 2011; 74: 395–399. doi:10.1590/s0004-27492011000600002
- [13] Moschos MM, Tagaris G, Markopoulos I et al. Morphologic changes and functional retinal impairment in patients with Parkinson disease without visual loss. *Eur J Ophthalmol* 2011; 21: 24–29. doi:10.5301/ejo.2010.1318
- [14] Lu Y, Li Z, Zhang X et al. Retinal nerve fiber layer structure abnormalities in early Alzheimer's disease: evidence in optical coherence tomography. *Neurosci Lett* 2010; 480: 69–72. doi:10.1016/j.neulet.2010.06.006
- [15] Lizano P, Bannai D, Lutz O et al. A Meta-analysis of Retinal Cytoarchitectural Abnormalities in Schizophrenia and Bipolar Disorder. *Schizophr Bull* 2020; 46: 43–53. doi:10.1093/schbul/sbz029
- [16] Ascaso FJ, Rodriguez-Jimenez R, Cabezón L et al. Retinal nerve fiber layer and macular thickness in patients with schizophrenia: Influence of recent illness episodes. *Psychiatry Res* 2015; 229: 230–236. doi:10.1016/j.psychres.2015.07.028
- [17] Yılmaz U, Küçük E, Ülgen A et al. Retinal nerve fiber layer and macular thickness measurement in patients with schizophrenia. *Eur J Ophthalmol* 2016; 26: 375–378. doi:10.5301/ejo.5000723
- [18] Chu EM, Kolappan M, Barnes TR et al. A window into the brain: an *in vivo* study of the retina in schizophrenia using optical coherence tomography. *Psychiatry Res* 2012; 203: 89–94. doi:10.1016/j.psychresns.2011.08.011

- [19] American Psychiatric Association. Diagnostic and statistical manual of mental disorders: DSM-5. 5th ed. Arlington, VA: American Psychiatric Association; 2013
- [20] Lalor EC, De Sanctis P, Krakowski MI et al. Visual sensory processing deficits in schizophrenia: is there anything to the magnocellular account? *Schizophr Res* 2012; 139: 246–252. doi:10.1016/j.schres.2012.05.022
- [21] Butler PD, Silverstein SM, Dakin SC. Visual perception and its impairment in schizophrenia. *Biol Psychiatry* 2008; 64: 40–47. doi:10.1016/j.biopsych.2008.03.023
- [22] Cabazon L, Ascaso F, Ramiro P et al. Optical coherence tomography: a window into the brain of schizophrenic patients. *Acta Ophthalmol* 2012; 90: 0–0. doi:10.1111/j.1755-3768.2012.T123.x
- [23] Samani NN, Proudlock FA, Siram V et al. Retinal Layer Abnormalities as Biomarkers of Schizophrenia. *Schizophr Bull* 2018; 44: 876–885. doi:10.1093/schbul/sbx130
- [24] Alizadeh M, Delborde Y, Ahmadpanah M et al. Non-linear associations between retinal nerve fibre layer (RNFL) and positive and negative symptoms among men with acute and chronic schizophrenia spectrum disorder. *J Psychiatr Res* 2021; 141: 81–91
- [25] Anderson G, Berk M, Dodd S et al. Immuno-inflammatory, oxidative and nitrosative stress, and neuroprogressive pathways in the etiology, course and treatment of schizophrenia. *Prog Neuropsychopharmacol Biol Psychiatry* 2013; 42: 1–4. doi:10.1016/j.pnpbp.2012.10.008
- [26] Dietsche B, Kircher T, Falkenberg I. Structural brain changes in schizophrenia at different stages of the illness: A selective review of longitudinal magnetic resonance imaging studies. *Aust N Z J Psychiatry* 2017; 51: 500–508. doi:10.1177/0004867417699473
- [27] Braus DF, Weber-Fahr W, Tost H et al. Sensory information processing in neuroleptic-naive first-episode schizophrenic patients: a functional magnetic resonance imaging study. *Arch Gen Psychiatry* 2002; 59: 696–701. doi:10.1001/archpsyc.59.8.696
- [28] Wong IY, Lu LP, Koizumi H et al. The inner segment/outer segment junction: what have we learnt so far? *Curr Opin Ophthalmol* 2012; 23: 210–218. doi:10.1097/ICU.0b013e3283524162
- [29] Islam F. Retinal Thickness and Visual Acuity in Diabetic Macular Edema: An Optical Coherence Tomography-Based Study. *J Coll Physicians Surg Pak* 2016; 26: 598–601
- [30] Deák GG, Schmidt-Erfurth UM, Jampol LM. Correlation of Central Retinal Thickness and Visual Acuity in Diabetic Macular Edema. *JAMA Ophthalmol* 2018; 136: 1215–1216. doi:10.1001/jamaophthalmol.2018.3848
- [31] Wong RL, Lee JW, Yau GS et al. *Relationship between Outer Retinal Layers Thickness and Visual Acuity in Diabetic Macular Edema. *Biomed Res Int* 2015; 2015: 981471. doi:10.1155/2015/981471
- [32] Eliwa TF, Hussein MA, Zaki MA et al. Outer Retinal Layer Thickness as Good Visual Predictor in Patients with Diabetic Macular Edema. *Retina* 2018; 38: 805–811. doi:10.1097/IAE.0000000000001599
- [33] Amminger GP, Schäfer MR, Schlägelhofer M et al. Longer-term outcome in the prevention of psychotic disorders by the Vienna omega-3 study. *Nat Commun* 2015; 6: 7934. doi:10.1038/ncomms8934
- [34] Tomasik J, Rahmoune H, Guest PC et al. Neuroimmune biomarkers in schizophrenia. *Schizophr Res* 2016; 176: 3–13. doi:10.1016/j.schres.2014.07.025
- [35] Mao H, Seo SJ, Biswal MR et al. Mitochondrial oxidative stress in the retinal pigment epithelium leads to localized retinal degeneration. *Invest Ophthalmol Vis Sci* 2014; 55: 4613–4627. doi:10.1167/iovs.14-14633