Accepted Manuscript online: 2022-01-12 Article published online: 2022-03-07

Endoscopic retrograde appendicitis therapy versus laparoscopic appendectomy for uncomplicated acute appendicitis

OPEN ACCESS

INFOGRAPHIC

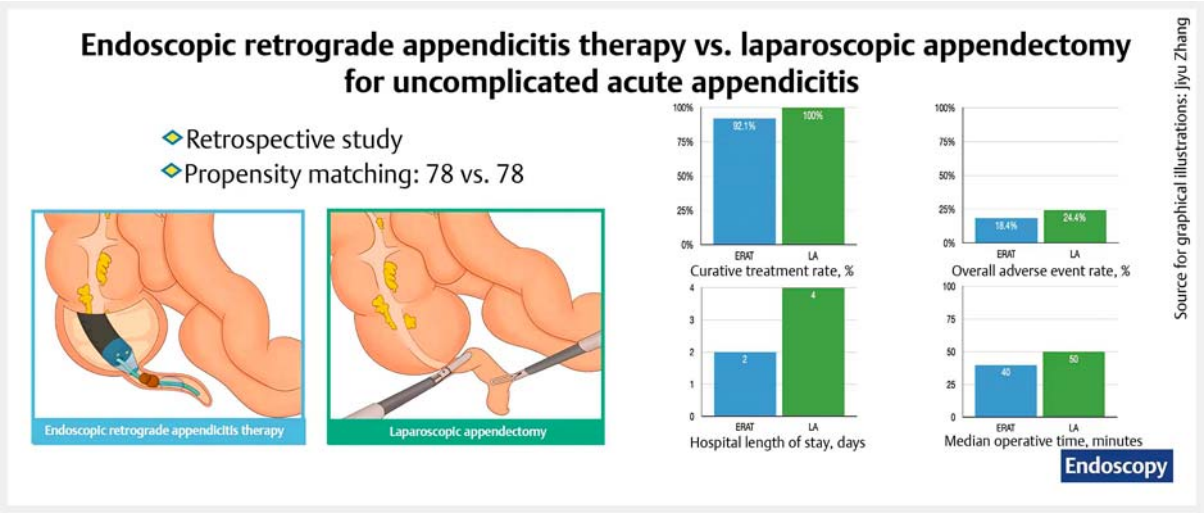

Authors

Baohong Yang[1,2], Lingjian Kong[1], Saif Ullah[1], Lixia Zhao[1], Dan Liu[1], Deliang Li[1], Xuezhong Shi[3], Xiaocan Jia[3], Paras Dalal[4], Bingrong Liu[1]

Institutions

1 Department of Gastroenterology, The First Affiliated Hospital of Zhengzhou University, Zhengzhou, Henan, China
2 Department of Oncology, Weifang People's Hospital (The First Affiliated Hospital of Weifang Medical University), Weifang, Shandong, China
3 Department of Epidemiology and Biostatistics, College of Public Health, Zhengzhou University, Zhengzhou, China
4 Department of Radiology, Harefield Hospital, Harefield, United kingdom

submitted 20.6.2021
accepted after revision 13.12.2021
published online 12.1.2022

Bibliography
Endoscopy 2022; 54: 747–754
DOI 10.1055/a-1737-6381
ISSN 0013-726X

Georg Thieme Verlag KG, Rüdigerstraße 14, 70469 Stuttgart, Germany

Scan this QR-Code for the author commentary.

Fig. 1 s, Table 1 s
Supplementary material is available under https://doi.org/10.1055/a-1737-6381

Corresponding author
Bingrong Liu, MD, PhD, Department of Gastroenterology, The First Affiliated Hospital of Zhengzhou University, The 1st street of Jianshe East Road, Zhengzhou 450000, China
fccliubr@zzu.edu.cn

ABSTRACT

Background Endoscopic retrograde appendicitis therapy (ERAT) is a new and minimally invasive technique for the treatment of acute appendicitis. This study aimed to assess the efficacy and clinical outcomes of ERAT versus laparoscopic appendectomy for patients with uncomplicated acute appendicitis.

Methods We adopted propensity score matching (1:1) to compare ERAT and laparoscopic appendectomy in patients with uncomplicated acute appendicitis between April 2017 and March 2020. We reviewed 2880 patients with suspected acute appendicitis, of whom 422 patients with uncomplicated acute appendicitis met the matching criteria (ERAT 79; laparoscopic appendectomy 343), yielding 78 pairs of patients.

Results The rate of curative treatment within 1 year after ERAT was 92.1% (95% confidence interval [CI] 83.8% to 96.3%). The percentage of patients recording visual analog scale values of ≤3 for pain at 6 hours after treatment was 94.7% (95%CI 87.2% to 97.9%) in the ERAT group, which was significantly higher than that in the laparoscopic appendectomy group (83.3%; 95%CI 73.5% to 90.0%). Median procedure time and median hospital length of stay were significantly lower in the ERAT group compared with the laparoscopic appendectomy group. At 1 year, the median recurrence time was 50 days (interquartile range 25–127) in the ERAT group. The overall adverse event rate was 24.4% (95%CI 14.8% to 33.9%) in the laparoscopic appendectomy group and 18.4% (95%CI 9.7% to 27.1%) in the ERAT group, with no significant difference between the two groups.

Conclusion ERAT was a technically feasible method of treating uncomplicated acute appendicitis compared with laparoscopic appendectomy.

Introduction

Appendicitis is a common abdominal surgical emergency condition that occurs most often between the ages of 10 and 20 years, with a male:female ratio of 1.4:1 [1]. Abraham Groves performed the first recorded appendectomy in 1883 [2]. A century later in 1983, Semm first introduced laparoscopic appendectomy [3]. While appendectomy remains the most effective treatment in cases of uncomplicated appendicitis, it causes complications and carries the risk of negative appendectomy (removal of a normal appendix) [4].

Endoscopic retrograde appendicitis therapy (ERAT) is a new and minimally invasive alternative method for the diagnosis and treatment of acute appendicitis. Liu et al. first introduced and implemented the technique in 2012 [5]. ERAT is inspired by endoscopic retrograde cholangiopancreatography (ERCP) technology. The basic principle involves the use of an endoscope with a transparent cap at its distal end to intubate the appendix and thereby decompress the lumen; the appendix cavity is fully drained using a Seldinger technique. The novel technique requires direct endoscopic imaging or fluoroscopic endoscopic retrograde appendicography (ERA) to distinguish between suspected acute appendicitis and actual acute appendicitis. For patients with uncomplicated acute appendicitis, we performed ERAT to relieve the appendiceal lumen obstruction. Studies have shown that up to 93.8%–95% of uncomplicated acute appendicitis did not have a recurrence following ERAT [6, 7].

To date, there are no reports comparing ERAT with laparoscopic appendectomy for uncomplicated acute appendicitis. Therefore, we conducted this noninferiority retrospective study to assess the feasibility of ERAT compared with laparoscopic appendectomy in patients who were hospitalized with acute appendicitis.

Methods

Patient selection

Following approval by the institutional review board, we retrospectively reviewed data of patients admitted to The First Affiliated Hospital of Zhengzhou University between April 2017 and March 2020 for treatment for appendix disease.

The inclusion criteria for this study were patients aged 18–60 years with uncomplicated acute appendicitis (appendix > 6 mm in diameter with wall thickening, along with periappendiceal edema and/or a small collection of fluid, without appendiceal stones, perforation, abscess, or suspected tumor) confirmed by computed tomography (CT), and opting for laparoscopic appendectomy or ERAT.

We excluded patients who had any of the following: 1) age younger than 18 years or older than 60 years; 2) complicated acute appendicitis found on preoperative examination or intraoperatively. Patients with suspected tumors were excluded if any of the following criteria applied: 1) CT scan showed an appendix > 5 mm with thickened or irregular walls; 2) colonoscopy for ERAT showed an involuted, mass-like protrusion, mucus, or polyp-like tissue at the opening of the appendix; 3) ERA showed a filling defect in the appendiceal lumen that remained after repeated flushing, with confirmed absence of fecal stone. Patients were also excluded if they could not be contacted during the follow-up period. Both ERAT and laparoscopic appendectomy procedures were carried out independently by experienced doctors or by beginners under the supervision of an experienced doctor.

We gathered the following clinical data: age, sex, body temperature, white blood cell count, C-reactive protein (CRP), level of abdominal pain (resulting in presentation to hospital), procedure duration, length of hospital stay, comorbidities, and adverse events. The visual analog scale (VAS) was applied to assess the level of abdominal pain (0–10 cm line; 0 = no pain; 0.1–3.0 = mild pain; 3.1–7.0 = moderate pain; 7.1–9.9 = severe

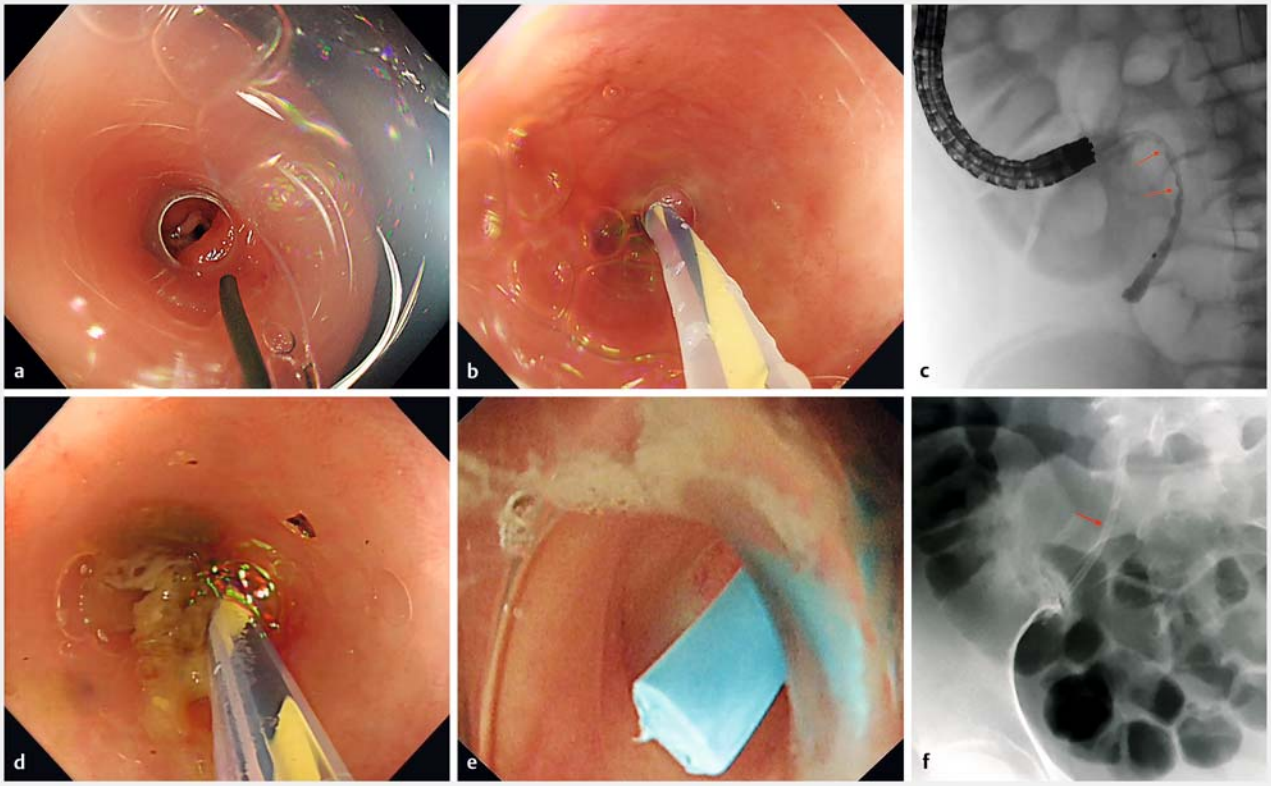

▶ **Fig. 1** The endoscopic retrograde appendicitis therapy (ERAT) procedure. **a** Appendiceal orifice. **b** Appendiceal lumen cannulation. **c** Filling defect in the appendiceal lumen visible on imaging (red arrows). **d** Flushing out of pus or appendiceal fecal stone. **e** Stent placement. **f** Radiograph after ERAT (red arrow indicates the stent).

pain; 10 = unbearable pain). All enrolled patients were followed up by telephone and/or medical records.

Description of ERAT technique

Preparation for ERAT included bowel cleansing using either 2 L polyethylene glycol electrolyte solution or low-pressure cleansing enemas (300–500 mL per enema) given five times. For patients with mild/moderate symptoms, the oral preparation was given 4–6 hours before the procedure. For clinically severe cases or patients with anorexia or nausea/vomiting, low-pressure cleansing enemas were given about 30 minutes prior to endoscopy [8].

The ERAT procedure was performed as described previously [5]. 1) An endoscope with a transparent cap attached to the tip was inserted to the cecum to the level of Gerlach's valve. 2) Gerlach's valve was then pushed aside using the transparent cap, and the appendix was intubated using the guidewire–catheter technique. 3) Under radiographic surveillance, the lumen of the appendix was then imaged with a water-soluble contrast agent to observe the morphology and internal diameter of the appendiceal lumen, and to evaluate whether there is *filling defects of leakage of the contrast agent, to confirm whether have the appendiceal stones or appendiceal perforation*. Appendiceal stones are commonly found in the appendiceal cavity and should be removed with mesh baskets, balloons, etc. 4) The appendiceal lumen was then repeatedly flushed with 50–100 mL of saline. 5) For patients with a large amount of pus or narrowing of the appendiceal lumen, a 7–8.5-Fr plastic stent (5–7 cm length; Cook Medical, Bloomington, Indiana, USA) was placed over the guidewire under X-ray surveillance to drain the pus and support the luminal stenosis to continuously reduce the pressure in the appendiceal lumen. After 2–4 weeks, patients underwent abdominal radiography to determine whether the stent should be removed. In some patients, the stent may dislodge on its own. Endoscopic images of the ERAT procedure are shown in ▶ **Fig. 1**.

Primary and secondary outcomes

The primary outcome was the rate of curative treatment. In the ERAT group, we defined curative treatment as successful appendiceal intubation and no recurrence of appendicitis during the 1-year follow-up period. In the laparoscopic appendectomy group, we identified curative treatment as a successful appendectomy without converting to open appendectomy.

Secondary outcomes included duration of treatment, rate of postoperative pain relief from moderate/severe to mild/no pain within 6 hours of treatment, length of hospital stay, short-term (within 30 days) adverse events, and long-term (> 30 days) adverse events. Overall adverse events included both short-term and long-term adverse events. In the ERAT group, short-term

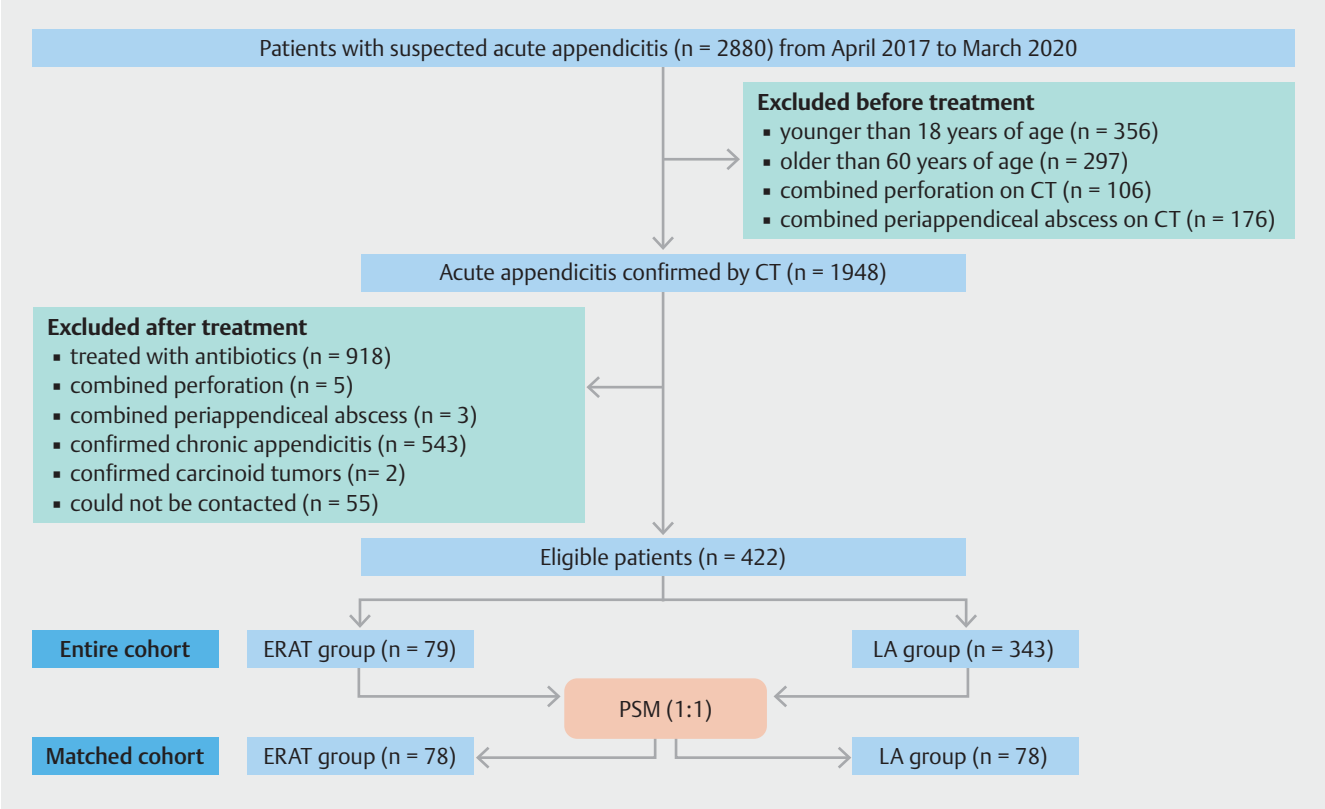

▶ **Fig. 2** Flow diagram of the entire and matched cohorts.

adverse events included recurrent appendicitis, gastrointestinal perforation, fever, bleeding and blood transfusion, abdominal abscess, contrast allergy, and systemic adverse events (pulmonary embolism, stroke, cardiac events, acute renal failure, and sepsis). Long-term adverse events included recurrent appendicitis, abdominal pain, diarrhea, constipation, and appendiceal tumors. In the laparoscopic appendectomy group, short-term adverse events included incisional infection, incisional pain, anastomotic leak, abdominal abscess, anesthesia-related events, and systemic adverse events. Long-term adverse events included bowel obstruction, abdominal pain, incisional hernia, diarrhea, and constipation. The definitions of adverse events are shown in **Table 1 s** in the online-only Supplementary material**.**

Sample size calculation

In this study, we assumed a 99 % success rate for uncomplicated acute appendicitis in the laparoscopic appendectomy group and a 95 % success rate in the ERAT group. A noninferiority margin of 11 % was used to calculate the sample size, meaning that the lower pass limit for ERAT would be 88 %. We estimated that a sample size of 74 patients per group would give an 80 % power to establish whether ERAT was noninferior to laparoscopic appendectomy regarding treatment success, using a one-sided significance α level of 0.05. The calculation was performed using Proc Power version 9.4 (SAS Institute Inc., Cary, North Carolina, USA) [9].

Statistical analysis

Propensity score matching (PSM) was used to minimize selection bias. The propensity score was estimated by logistic regression, with treatment as the dependent variable and independent variables, including sex and age. We matched patients 1:1 using the nearest-neighbor matching algorithm without replacement, with the caliper value fixed at 0.1 for the propensity matching scores [10]. Continuous variables (procedure duration, length of hospital stay, age, time to recurrence, and hospitalization cost) were expressed as medians with 95 % confidence intervals (CIs) and interquartile ranges (IQRs), and categorical variables were expressed as frequency and percentages with 95 %CIs. The Mann–Whitney *U* test was applied for continuous variables. The Pearson's chi-squared test or Fisher's exact test were used for categorical variables. We computed the cumulative incidence of recurrent appendicitis in the ERAT group using the Kaplan–Meier approach. We performed PSM and all calculations using Stata/SE 15.0 (Stata Corp., College Station, Texas, USA). All tests were two-sided. *P* values of <0.05 were considered statistically significant.

Results

Patient characteristics

From the inpatient database of The First Affiliated Hospital of Zhengzhou University, we extracted data of 2880 patients with suspected acute appendicitis between April 2017 and

▶ **Table 1** Baseline patient characteristics after propensity score matching.

Variable	ERAT (n = 78)	Laparoscopic appendectomy (n = 78)	*P* value
Sex, male, n (%)	40 (51.3)	41 (52.6)	0.86
Age, median (IQR), years	30 (21–35.3)	30 (22.8–34.3)	0.35
Temperature[1] > 37.2℃, n (%)	33 (42.3)	31 (39.7)	0.74
VAS[2] for pain, n (%)			
▪ Moderate (3.1–7.0)	29 (37.2)	35 (44.9)	0.33
▪ Severe (7.1–10.0	49 (62.8)	43 (55.1)	
CRP[3] > 5 mg/L, n (%)	63 (80.8)	57 (73.1)	0.25
Leukocytes count[4] > 10×10^9/L, n (%)	67 (85.9)	61 (78.2)	0.21

ERAT, endoscopic retrograde appendicitis therapy; IQR, interquartile range; PSM, propensity score matching; VAS, visual analog scale; CRP, C-reactive protein.
[1] Baseline temperature reference: 36.3–37.2℃.
[2] 0 = no pain; 0.1–3.0 = mild pain; 3.1–7.0 = moderate pain; 7.1–9.9 = severe pain; 10 = unbearable pain.
[3] Baseline CRP reference: 0–5 mg/L.
[4] Baseline leukocytes count reference: $0–10 \times 10^9$/L.

March 2020. Of these patients, we excluded 356 patients who were younger than 18 years, 297 patients who were older than 60 years, 103 patients with perforation on CT, and 176 patients with periappendiceal abscess on CT. A total of 1948 patients with uncomplicated acute appendicitis were confirmed by CT and opted for treatment. Then we excluded 918 patients who were treated with antibiotics, 3 patients with periappendiceal abscess diagnosed during laparoscopic appendectomy, 5 patients with perforation diagnosed during laparoscopic appendectomy, 2 patients with carcinoid tumors confirmed by postoperative pathology, 543 patients with chronic appendicitis confirmed by postoperative pathology, and 55 patients who could not be contacted (lost to follow-up). We identified 422 eligible patients for matching (ERAT 79; laparoscopic appendectomy 343). Propensity score matching yielded 78 patient pairs (▶ **Fig. 2**). **Fig. 1 s** presents the distribution of the propensity scores in the laparoscopic appendectomy and ERAT groups. ▶ **Table 1** shows the characteristics of the matched patients.

Primary outcome

In the ERAT group, three endoscopists performed ERAT for patients with uncomplicated acute appendicitis. Overall, 76 patients (97.4 %; 95 %CI 91.1 % to 99.3 %) underwent successful appendiceal intubation and 2 patients (2.6 %; 95 %CI 0.7 % to 8.9 %) were referred for surgery because of failed intubation during the ERAT process. In total, 70/76 patients (92.1 %; 95 % CI 83.8 % to 96.3 %) with uncomplicated acute appendicitis did not require surgical intervention during the 1-year follow-up period after ERAT. With a predetermined 11 % noninferiority margin for this study, we were able to demonstrate that ERAT was noninferior to laparoscopic appendectomy. A total of 28 patients (36.8 %; 95 %CI 26.9 % to 48.1 %) underwent saline flushing of the appendiceal lumen and placement of a stent, and 48 patients (63.2 %; 95 %CI 51.9 % to 73.1 %) underwent saline flushing of the appendiceal lumen alone. In the laparoscopic appendectomy group, all patients received laparoscopic surgical resection successfully. Intraoperative abdominal tubes were placed in three patients and removed after 24 hours of observation. Postoperative pathology confirmed uncomplicated acute appendicitis in all 78 patients, including 58 (74.4 %; 95 %CI 63.7 % to 82.8 %) with acute simple appendicitis and 20 (25.6 %; 95 %CI 17.3 % to 36.3 %) with acute suppurative appendicitis.

Intraoperative and postoperative outcomes

The median procedure time was 50 minutes (95 %CI 50 to 55) in the laparoscopic appendectomy group, which was significantly longer than that of the ERAT group (40 minutes [95 %CI 35 to 45]; $P < 0.001$; difference 10 minutes [95 %CI 6 to 15]). A total of 72 patients (94.7 %; 95 %CI 87.2 % to 97.9 %) had VAS ≤ 3 6 hours after treatment in the ERAT group compared with 65 patients (83.3 %; 95 %CI 73.5 % to 90.0 %) in the laparoscopic appendectomy group, with a statistical difference between the two groups ($P = 0.02$; difference 11.4 percentage points [95 % CI 1.7 to 21.1]). The median hospital length of stay was 4 days (95 %CI 3 to 4) in the laparoscopic appendectomy group, which was significantly longer than the hospital stay in the ERAT group (2 days [95 %CI 2 to 2]; $P < 0.001$; difference 2 days [95 %CI 1 to 2]). ▶ **Table 2** shows the main outcomes of the two matched groups.

Short- and long-term adverse events

The median follow-up time was 1 year. The overall short-term adverse event rate was 7.7 % (95 %CI 3.6 % to 15.8 %) in the laparoscopic appendectomy group and 6.6 % (95 %CI 1.0 % to 12.2 %) in the ERAT group, with no significant difference between the two groups. In one patient in the ERAT group, ERA showed a fecal stone in the distal appendiceal cavity. The contrast agent diffused into the abdominal cavity, thus confirming the appendiceal perforation. With the patient's consent, we placed two abdominal drains and administered peritoneal flushing. The patient recovered with no intra-abdominal abscesses or other adverse events, and was discharged after 7 days of conservative antibiotic treatment. A month later, we successfully performed ERAT once again using ultrafine chole-

▶ **Table 2** Outcomes of the two matched groups.

	ERAT (n = 76)	Laparoscopic appendectomy (n = 78)	Difference	*P* value
Procedure time, median [95 %CI], minutes	40 [35 to 45]	50 [50 to 55]	−10 [−15 to −6]	<0.001[6]
Hospital length of stay, median [95 %CI], days	2 [2 to 2]	4 [3 to 4]	−2 (−2 to −1)	<0.001[6]
Curative treatment rate, n (%) [95 %CI]	70 (92.1) [83.8 to 96.3]	78 (100) [100 to 100]	−8 (−7.9) [−14.0 to −1.8]	0.01[6]
VAS for pain ≤ 3 at 6 hours after treatment, n (%) [95 %CI]	72 (94.7) [87.2 to 97.9]	65 (83.3) [73.5 to 90.0]	7 (11.4) [1.7 to 21.1]	0.02[6]
Overall adverse event rate, n (%) [95 %CI]	14 (18.4) [9.7 to 27.1]	19 (24.4) [14.8 to 33.9]	−5 (−5.9) [−18.9 to 7.0]	0.37
Recurrence of appendicitis, n (%) [95 %CI]	6[1] (7.9) [3.7 to 16.2]	0	6	0.01[6]
Overall short-term adverse event rate, n (%) [95 %CI]	5[2] (6.6) [1.0 to 12.2]	6 (7.7) [3.6 to 15.8]	−1 (−1.1) [−9.2 to 7.0]	0.79
▪ Incisional infection	0	2 (2.6) [0.7 to 8.9]	−2	0.50
▪ Delayed awakening	0	1 (1.3) [0.2 to 6.9]	−1	>0.99
▪ Incisional pain	0	3 (3.8) [1.3 to 10.7]	−3	0.25
▪ Fever[3]	2 (2.6) [0.7 to 9.1]	0	2	0.24
▪ Appendiceal perforation	1 (1.3) [0.2 to 7.1]	0	1	0.49
Overall long-term adverse event rate, n (%) [95 %CI]	9[4] (11.8) [4.6 to 19.1]	13 (16.7) [10 to 26.5]	−4 (−4.8) [−15.8 to 6.2]	0.49
▪ Abdominal pain	5 (6.6) [2.8 to 14.5]	4 (5.1) [0.2 to 10.0]	1 (1.5) [−6.0 to 8.9]	0.75
▪ Diarrhea	0	9[5] (11.5) [6.2 to 20.5]	−9	0.003[6]

ERAT, endoscopic retrograde appendicitis therapy; CI, confidence interval; VAS, visual analog scale.
[1] Two patients experienced recurrence of appendicitis within 30 days after ERAT, and four patients had recurrence of appendicitis > 30 days after ERAT.
[2] Including two patients with recurrent appendicitis within 30 days after ERAT.
[3] Baseline temperature, reference: 36.3℃–37.2℃. Both patients had body temperatures < 38℃.
[4] Including four patients with recurrent appendicitis > 30 days after ERAT.
[5] Three patients with Grade 1 diarrhea (< 4 stools/day) and six patients with Grade 2 diarrhea (4–6 stools/day).
[6] Significant difference between the two groups.

dochoscopy (SpyGlass; Boston Scientific Corp., Marlborough, Massachusetts, USA) to break the fecal stone before removing it. The patient had no recurrence during the follow-up period. Two patients (2.6 %; 95 %CI 0.7 % to 9.1 %) in the ERAT group developed fever after treatment and recovered following conservative antibiotic treatment. During the 1-year follow-up period, there were no deaths in either group, no bowel obstruction or hernia in the laparoscopic appendectomy group, and no appendiceal tumors in the ERAT group. The overall long-term adverse event rate was 16.7 % (95 %CI 10.0 % to 26.5 %) in the laparoscopic appendectomy group and 11.8 % (95 %CI 4.6 % to 19.1 %) in the ERAT group (*P* = 0.49; difference 4.8 percentage points [95 %CI −6.2 to 15.8]). Five patients (6.6 %; 95 %CI 2.8 % to 14.5 %]) in the ERAT group had varying degrees of abdominal pain 2 months after treatment, three had spontaneous resolution of symptoms, and two went to the hospital for examination. One patient was diagnosed with enteritis and the other with pelvic infection; both patients recovered after conservative treatment. In the laparoscopic appendectomy group, three patients (3.9 %; 95 %CI 1.3 % to 10.7 %]) had Grade 1 diarrhea (< 4 stools/day) and six patients (7.7 %; 95 %CI 3.6 % to 15.8 %]) had Grade 2 diarrhea (4–6 stools/day), all of whom recovered after symptomatic treatment.

Recurrence in the ERAT group

There was no recurrence of appendicitis in patients who had stents placed, whereas appendicitis recurred in six patients (7.9 %; 95 %CI 3.7 % to 16.2 %]) without stents. Among the patients with recurrent appendicitis, two of them recurred within 30 days. The overall median recurrence time was 50 days (IQR 25–127). One patient underwent laparoscopic surgery 4 months after ERAT and recovered well after surgery. Postoperative pathology confirmed chronic appendicitis. The other five patients had recurrence of uncomplicated appendicitis. We performed ERAT again for one of them and placed a stent for adequate drainage; four other patients received antibiotic therapy. None of the five patients experienced recurrence during the follow-up period. ▶ **Fig. 3** shows the cumulative incidence of recurrent acute appendicitis in the ERAT group.

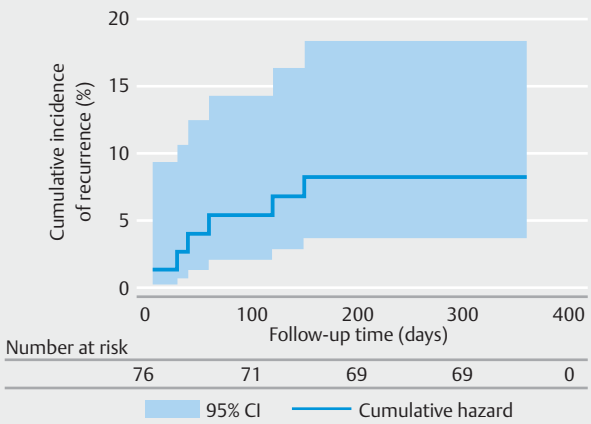

▶ **Fig. 3** Kaplan–Meier graph for time to recurrence after endoscopic retrograde appendicitis therapy at 1-year follow-up.

Discussion

The appendix is a lymphoid organ, the tissue of which begins to appear at birth and is fully developed by 12–20 years of age. The structure has an immune function, as evidenced by the fact that it can be a good host for biofilms that are essential for beneficial microorganisms [11]. In addition, a comprehensive study found that appendectomy was associated with a higher risk of Crohn's disease [12]. In 2009, a study from China demonstrated that the appendix may have a protective effect against colon cancer, and that appendectomy may be a risk factor for the development of colorectal cancer [13]. Furthermore, the appendix is closely associated with intestinal microecology. In 2014, Japanese researchers compared rats with and without appendectomy, and found that the appendix provides immune cells to the intestine and plays a role in maintaining intestinal bacterial homeostasis [14].

In recent years, appendectomy has been challenged as the "gold standard" for the management of acute appendicitis because of postoperative complications and a high rate of resection of the normal appendix [15–18]. The most recent guidelines recommend antibiotic treatment as a good option for patients with uncomplicated appendicitis [19]. The Appendicitis Acuta (APPAC) study showed that 73% of the 256 patients with uncomplicated acute appendicitis treated with antibiotics did not require surgical therapy during a 1 -year follow-up period [20]. In addition, a comprehensive review and meta-analysis showed that antibiotics could be a viable and effective treatment option for image-proven uncomplicated appendicitis [21]. Nevertheless, the use of antibiotics in treating uncomplicated acute appendicitis faces unavoidable problems: patients with appendiceal fecaliths are at higher risk of acute peritonitis because of complications of appendiceal perforation and have a higher recurrence rate after antibiotic treatment [20]. ERAT is useful for patients with appendiceal fecoliths, as it can flush the fecoliths out and remove the obstruction, thus relieving symptoms and considerably reducing the recurrence rate of appendicitis [22]. Another advantage of ERAT over antibiotics for uncomplicated acute appendicitis is that ERAT rapidly eliminates painful symptoms, whereas patients experience varying levels of pain during antibiotic treatment. The curative treatment rate of ERAT in the current study was better than the rate with antibiotic treatment in previous studies of uncomplicated acute appendicitis [23–27]. Further prospective studies are needed to compare ERAT and antibiotic treatment for uncomplicated acute appendicitis.

Although appendectomy is a routine surgical procedure, there remains a risk of surgical adverse events and negative appendectomy. Common complications include incisional infection (6%), abdominal infection (1.6%–3%), small-bowel adhesion obstruction (0.4%–1.3%), incisional hernia (0.4%), and other complications such as interstitial pneumonia (2.5%), urinary tract infection (1.1%), and cardiovascular accidents (1.1%) [28]. In our study, nine cases of diarrhea occurred after laparoscopic appendectomy surgery, which might be because of the imbalance of intestinal flora after appendectomy. Further exploration of changes in gut flora after ERAT and laparoscopic appendectomy may clarify the cause of diarrhea and bowel dysfunction. The six patients with recurrence in the ERAT group were treated with appendix flushing without stent placement for drainage. Interestingly, one patient with recurrence chose ERAT again and the condition did not recur after stent placement, suggesting that adequate drainage may be an effective means of reducing recurrence of appendicitis. Therefore, exploring and differentiating the population at high risk of recurrence after ERAT is a key direction for future research. The median length of hospital stay in the ERAT group was shorter than that in the laparoscopic appendectomy group. In China, patients usually choose to remain in hospital for an observation period of 2–4 days after laparoscopic or open surgery.

However, this study still has its limitations, including the retrospective design, relatively small sample size, and potential selection bias, in particular the possibility that healthier patients could have been selected for ERAT (unmeasured confounders). There are also issues that the study was not designed to investigate; for example, ERAT may exacerbate perforation, cancer diagnosis may be missed, and some patients need to undergo multiple colon examinations.

In conclusion, ERAT could be an effective and minimally invasive alternative approach for the treatment of uncomplicated acute appendicitis, with rapid postoperative abdominal pain relief, preservation of the appendix, and fast recovery, enabling daily life to return to normal as soon as possible. To further evaluate the safety and efficacy of ERAT, a comprehensive international, multicenter, randomized controlled prospective study is urgently needed.

Acknowledgment

The authors sincerely thank Jiyu Zhang, MD (The First Affiliated Hospital of Zhengzhou University) for valuable help in revision of the graphical abstract.

Funding

Outstanding foreign scientist studio project of Henan province No. GZS2020006

Competing interests

The authors declare that they have no conflict of interest.

References

[1] Humes DJ, Simpson J. Acute appendicitis. BMJ 2006; 333: 530–534

[2] Harris CW. Abraham Groves of Fergus: the first elective appendectomy? Can J Surg 1961; 4: 405–410

[3] Semm K. Endoscopic appendectomy. Endoscopy 1983; 15: 59–64

[4] Poprom N, Numthavaj P, Wilasrusmee C et al. The efficacy of antibiotic treatment versus surgical treatment of uncomplicated acute appendicitis: systematic review and network meta-analysis of randomized controlled trial. Am J Surg 2019; 218: 192–200

[5] Liu BR, Song JT, Han FY et al. Endoscopic retrograde appendicitis therapy: a pilot minimally invasive technique (with videos). Gastrointest Endosc 2012; 76: 862–866

[6] Liu BR, Ma X, Feng J et al. Endoscopic retrograde appendicitis therapy (ERAT): a multicenter retrospective study in China. Surg Endosc 2015; 29: 905–909

[7] Li Y, Mi C, Li W et al. Diagnosis of acute appendicitis by endoscopic retrograde appendicitis therapy (ERAT): combination of colonoscopy and endoscopic retrograde appendicography. Dig Dis Sci 2016; 61: 3285–3291

[8] Kong LJ, Liu D, Zhang JY et al. Digital single-operator cholangioscope for endoscopic retrograde appendicitis therapy. Endoscopy 2021: doi:10.1055/a-1490-0434

[9] Chow SC, Wang H, Shao J. Sample size calculations in clinical research.2nd edition New York: Taylor & Francis; 2007

[10] Austin PC. An introduction to propensity score methods for reducing the effects of confounding in observational studies. Multivariate Behav Res 2011; 46: 399–424

[11] Bollinger RR, Barbas AS, Bush EL et al. Biofilms in the large bowel suggest an apparent function of the human vermiform appendix. J Theor Biol 2007; 249: 826–831

[12] Andersson RE, Olaison G, Curt Tysk et al. Appendectomy is followed by increased risk of Crohn's disease. Gastroenterology 2003; 124: 40–46

[13] Meng W, Cai SR, Zhou L et al. Performance value of high risk factors in colorectal cancer screening in China. World J Gastroenterol 2009; 15: 6111–6116

[14] Masahata K, Umemoto E, Kayama H et al. Generation of colonic IgA-secreting cells in the caecal patch. Nat Commun 2014; 5: 3704

[15] Styrud J, Eriksson S, Nilsson I et al. Appendectomy versus antibiotic treatment in acute appendicitis. A prospective multicenter randomized controlled trial. World J Surg 2006; 30: 1033–1037

[16] Liu K, Fogg L. Use of antibiotics alone for treatment of uncomplicated acute appendicitis: a systematic review and meta-analysis. Surgery 2011; 150: 673–683

[17] Andersson R. Antibiotics versus surgery for appendicitis. Lancet 2011; 378: 1067–1068

[18] Livingston E, Vons C. Treating appendicitis without surgery. JAMA 2015; 313: 2327

[19] Podda M. Diagnosis and treatment of acute appendicitis: 2020 update of the WSES Jerusalem guidelines. World J Emerg Surg 2020; 15: 27

[20] Salminen P, Paajanen H, Rautio T et al. Antibiotic therapy vs appendectomy for treatment of uncomplicated acute appendicitis: the APPAC randomized clinical trial. JAMA 2015; 313: 2340–2348

[21] Podda M, Gerardi C, Cillara N et al. Antibiotic treatment and appendectomy for uncomplicated acute appendicitis in adults and children: a systematic review and meta-analysis. Ann Surg 2019; 270: 1028–1040

[22] Ye LP, Mao XL, Hai Y et al. Endoscopic retrograde appendicitis techniques for the treatment of patients with acute appendicitis. Zeitschrift Für Gastroenterologie 2018; 56: 899–904

[23] Barnes BA, Behringer GE, Wheelock FC et al. Treatment of appendicitis at the Massachusetts General Hospital (1937–1959). JAMA 1962; 180: 122–126

[24] Bhangu A, Søreide K, Di Saverio S et al. Acute appendicitis: modern understanding of pathogenesis, diagnosis, and management. Lancet 2015; 386: 1278–1287

[25] Davidson GH, Flum DR, Talan DA et al. Comparison of Outcomes of antibiotic Drugs and Appendectomy (CODA) trial: a protocol for the pragmatic randomised study of appendicitis treatment. BMJ Open 2017; 7: e016117

[26] Talan DA, Saltzman DJ, Mower WR et al. Antibiotics-first versus surgery for appendicitis: a US pilot randomized controlled trial allowing outpatient antibiotic management. Ann Emerg Med 2017; 70: 1–11

[27] Harnoss JC, Probst P, Büchler MW et al. Antibiotics versus appendicectomy for the treatment of uncomplicated acute appendicitis: an updated meta-analysis of randomised controlled trials by Rollins et al. World J Surg 2017; 41: 2411

[28] Margenthaler JA, Longo WE, Virgo KS et al. Risk factors for adverse outcomes after the surgical treatment of appendicitis in adults. Ann Surg 2003; 238: 59–66