

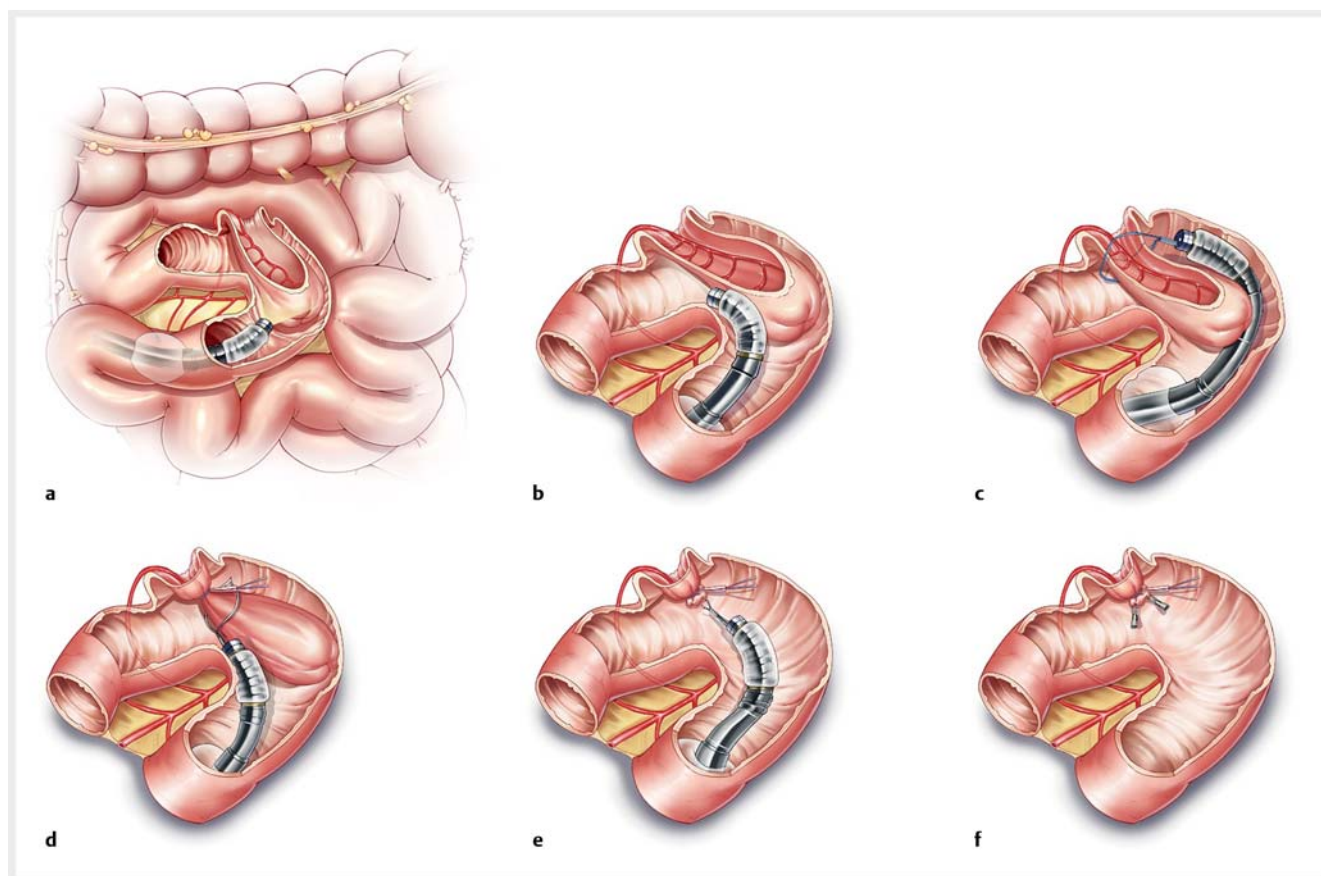
Novel technique for treating intussuscepted intestinal Meckel's diverticulum: enteroscopic intestinal diverticulum dissection (EIDD)

Meckel's diverticulum is a well-described anomaly of the small intestine caused by the incomplete closure of the omphalomesenteric or vitelline duct. It generally does not cause any symptoms [1]. Treatment is usually performed for complications, the most serious being gastrointestinal bleeding. Traditional treatments including diverticulum exclusion, varus suture, simple resection of the diverticu-

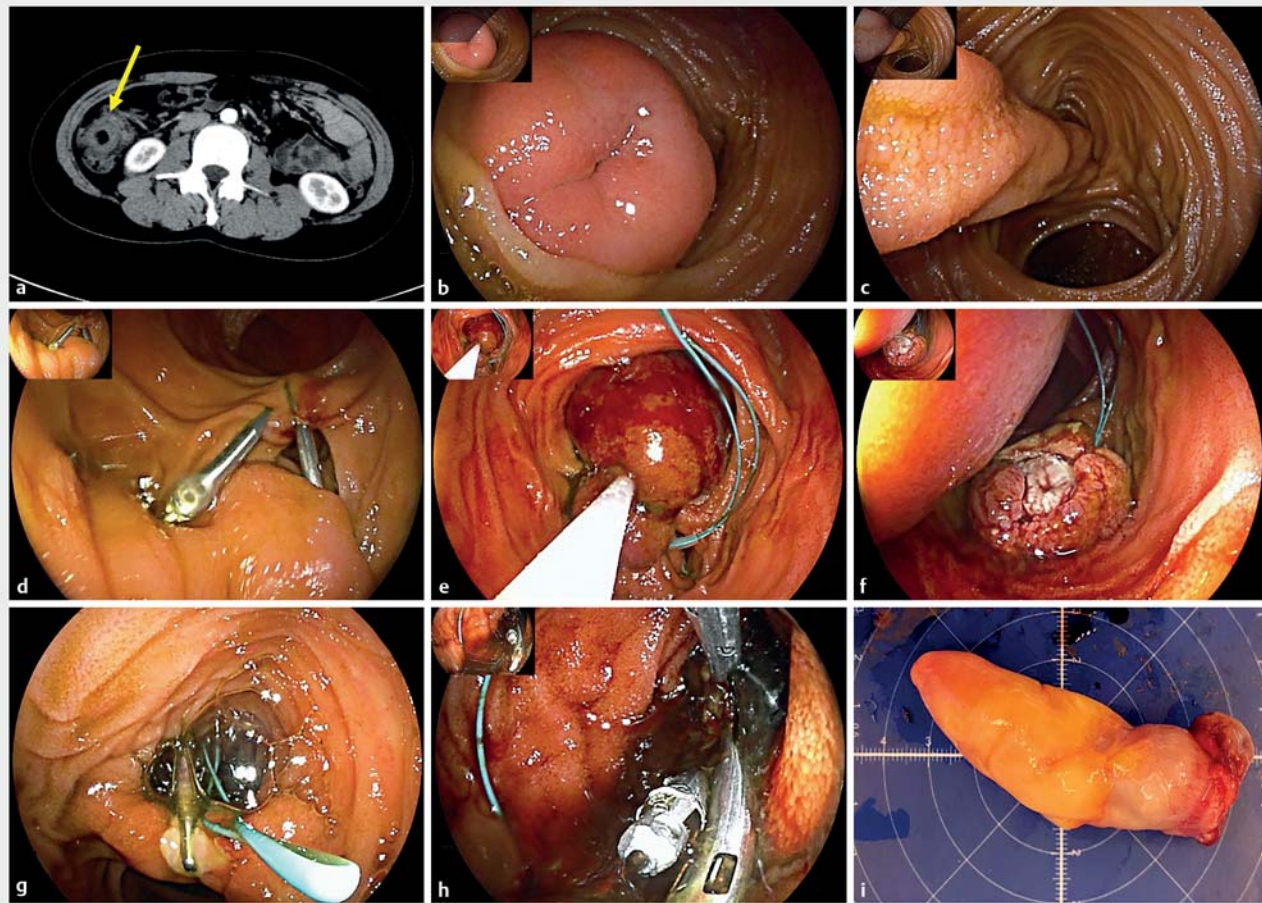
lum, and partial resection of the small intestine, are traumatic [2, 3]. Enteroscopic surgery is a recently developed treatment modality. Herein, we report on a novel technique, called enteroscopic intestinal diverticulum dissection (EIDD) (► **Fig. 1**), for treatment of intussuscepted intestinal Meckel's diverticulum.

A 30-year-old woman complained of tenderness in the lower abdomen. Con-

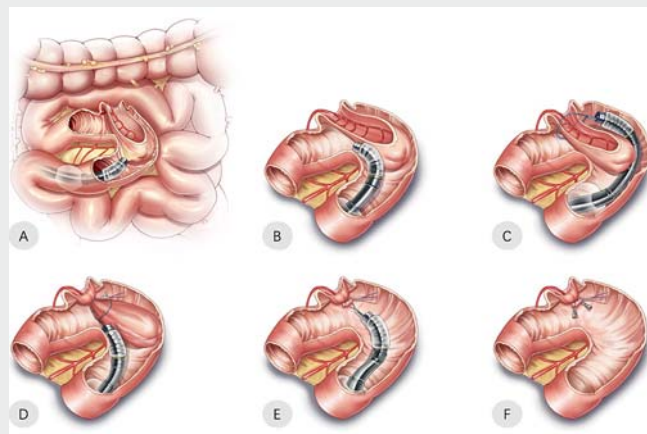
trast-enhanced computed tomography showed a long intussuscepted diverticulum. Double-balloon enteroscopy at our hospital located a 10-cm pedunculated mass protruding into the intestinal cavity, with an umbilicate depression at the center of the head of the mass. Two metallic clips were placed at the base of the diverticulum for future location. Two weeks later, symptoms remained and the pa-



► **Fig. 1** Illustration of the enteroscopic intestinal diverticulum dissection (EIDD) technique. The procedure is performed with the patient under general anesthesia with endotracheal intubation. Prophylactic intravenous antibiotics are introduced 30 minutes before the procedure. A transparent cap is attached to the tip of the gastroscope and carbon dioxide is used routinely during the procedure. The EIDD procedure includes 5 steps. **a, b** Step 1 – The diverticulum is located. The structure is examined carefully, including the head, body, and base of the intussuscepted diverticulum, especially the surface mucosa, umbilicus-like depression, and the structure inside the diverticulum, and whether there is heterotopic mucosa or intestinal wall structure. **c** Step 2 – An endoloop is positioned at the base of the stalk to block the blood vessels in the root while preventing perforation. **d, e** Step 3 – Snare diverticulectomy. The resection is performed using a combination of endocut and forced coagulation current (mainly forced coagulation); electrocoagulation is applied initially as forced coagulation and then in endocut mode, so that the current can conduct and coagulate the distal vessels. **f** Step 4 – Several metallic clips are placed above the endoloop to prevent post-resection bleeding. Step 5 – Tumor extraction. By using a snare, the diverticulum is retrieved from the intestine.



► **Fig. 2** Enteroscopic intestinal diverticulum dissection for the treatment of occult gastrointestinal bleeding caused by intussuscepted Meckel's diverticulum in a 30-year-old female patient. **a** Computed tomography showed a sheath-like structure. **b, c** Visualization of an inverted Meckel's diverticulum 100 cm from the ileocecal valve. **d** Location site. **e** The endoloop around the stalk. **f** Snare diverticulectomy. **g** Diverticulum inversion. **h** Hemoclips at the stalk. **i** Finger-like specimen: 7×2×2 cm in size.



► **Video 1** Enteroscopic intestinal diverticulum dissection for the treatment of intussuscepted Meckel's diverticulum in a 30-year-old female patient, with successful therapeutic double-balloon enteroscopy and an operative time of 40 minutes. The morphology showed a finger-like mass, 7×2×2 cm in size. Histologic examination showed that the diverticulum was composed of heterotopic pancreatic tissue.

tient opted for endoscopic treatment. The EIDD technique, which is applied in large pedunculated polyps, was performed and complete resection of the diverticulum was achieved, thus avoiding surgery (► **Fig. 2**, ► **Video 1**). The post-operative course was uneventful. The patient was discharged 3 days after enteroscopic surgery. Her symptoms resolved completely during follow-up. When considering EIDD, we should ensure that the diagnosis is clear preoperatively to exclude intestinal duplication, polyp, submucosal tumor, or intestinal wall varus. Standardization of the procedure should be established by constant accumulation and review of experience, including choice of instruments, method of resection, suture techniques, and so on. In this way, enteroscopic treatment can maintain intestinal integrity and lead

to rapid healing, free of postoperative adverse events, especially anastomotic complications. Further clinical studies with a larger number of patients are necessary to confirm this hypothesis.

Endoscopy_UCTN_Code_TTT_1AP_2AD

Acknowledgement

This study was supported by grants from the National Natural Science Foundation of China (81902394), Shanghai Dawnlight program (20CG07), and Excellent Young Scholar Foundation of Zhongshan Hospital (2021ZSYQ08).

Funding

National Natural Science Foundation of China

<http://dx.doi.org/10.13039/501100001809>
81902394

Shanghai Municipal Education Commission
<http://dx.doi.org/10.13039/501100003395>
20CG07

Zhongshan Hospital
<http://dx.doi.org/10.13039/501100010108>
2021ZSYQ08

Competing interests

The authors declare that they have no conflict of interest.

The authors

Ping-Ting Gao, Meng-Jiang He, Quan-Lin Li, Ping-Hong Zhou, Li-Li Ma

Endoscopy Center and Endoscopy Research Institute, Zhongshan Hospital, Fudan University, Shanghai, China.

Corresponding author

Li-Li Ma, MD

Endoscopy Center and Endoscopy Research Institute, Zhongshan Hospital, Fudan University, 180 Fenglin Road, Shanghai 200032, China
enteroscopy@126.com

References

- [1] Park JJ, Wolff BG, Tollefson MK et al. Meckel diverticulum: the Mayo Clinic experience with 1476 patients (1950–2002). *Ann Surg* 2005; 241: 529–533
- [2] Takagaki K, Osawa S, Ito T et al. Inverted Meckel's diverticulum preoperatively diagnosed using double-balloon enteroscopy. *World J Gastroenterol* 2016; 22: 4416–4420
- [3] Uchiyama S, Sannomiya I, Hidaka H et al. Meckel diverticulum diagnosed by double-balloon enteroscopy and treated laparoscopically: case report and review of the literature. *Surg Laparosc Endosc Percutan Tech* 2010; 20: 278–280

Bibliography

Endoscopy 2022; 54: E578–E580

DOI 10.1055/a-1704-6783

ISSN 0013-726X

published online 21.12.2021

© 2021. Thieme. All rights reserved.

Georg Thieme Verlag KG, Rüdigerstraße 14, 70469 Stuttgart, Germany

ENDOSCOPY E-VIDEOS

<https://eref.thieme.de/e-videos>



Endoscopy E-Videos is an open access online section, reporting on interesting cases

and new techniques in gastroenterological endoscopy. All papers include a high quality video and all contributions are freely accessible online. Processing charges apply (currently EUR 375), discounts and waivers acc. to HINARI are available.

This section has its own submission website at

<https://mc.manuscriptcentral.com/e-videos>