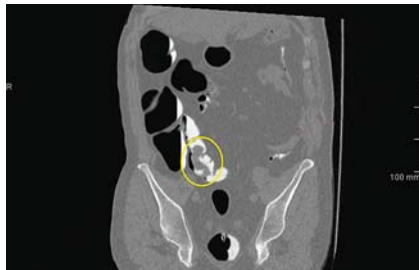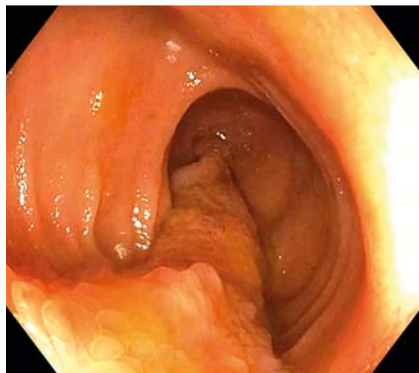


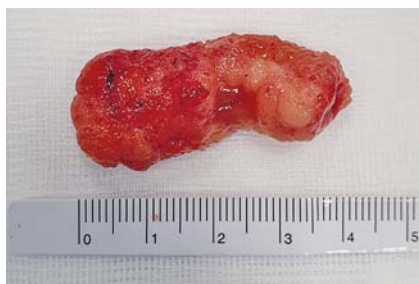## A transvalvular polypectomy of a giant ileal inflammatory fibroid polyp by retrograde single-balloon enteroscopy



► **Fig. 1** Computed tomography-based virtual colonoscopy showing the finger-like-shaped ileal polyp (yellow circle).

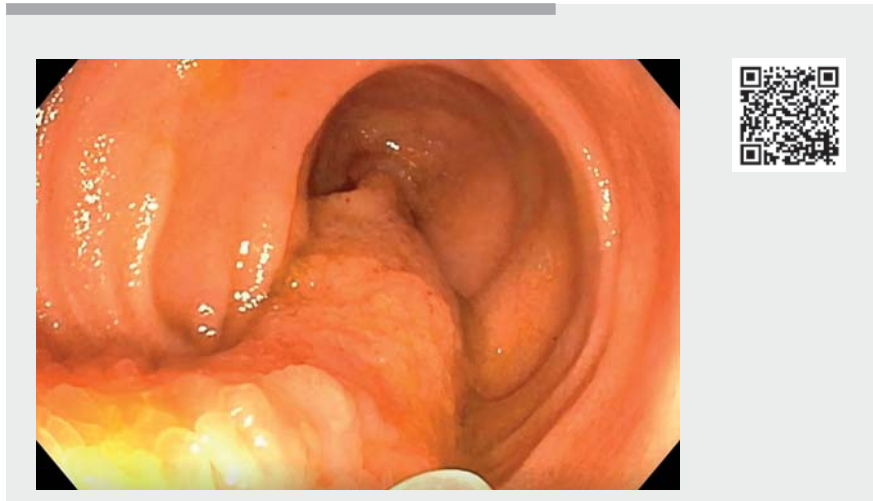


► **Fig. 2** Endoscopic view of the ileal polyp.

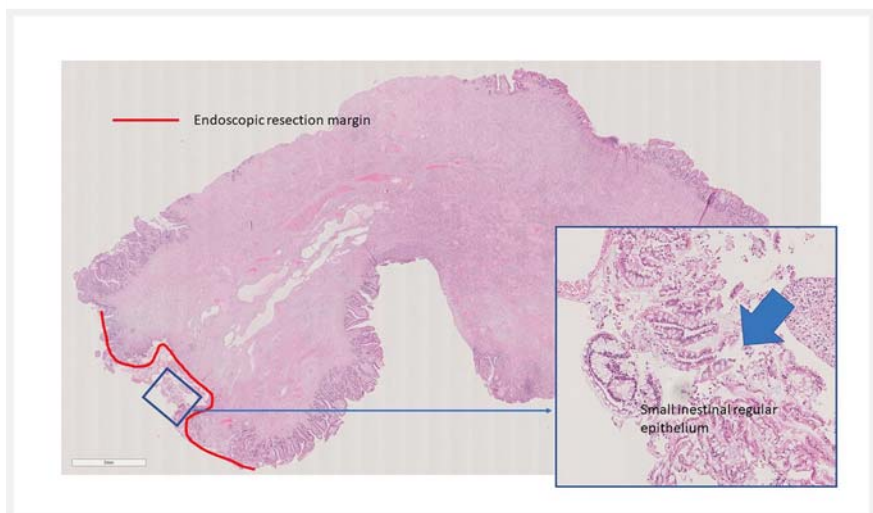


► **Fig. 3** Polyp 4 cm in length removed from the terminal ileum.

Small-bowel tumors, both malignant and benign, are rare lesions accounting for no more than 2% of gastrointestinal malignancies [1]. We report the case of an asymptomatic 61-year-old man who underwent a screening colonoscopy in an out-patient hospital conducted up to



► **Video 1** Transvalvular polypectomy of an ileal polyp.



► **Fig. 4** Histological specimen of inflammatory fibroid polyp completely removed (clear margins).

the ascending colon owing to a dolicho-colon. A cecal mass was observed that could not be correctly defined. A subsequent computed tomography (CT)-based virtual colonoscopy showed a 6-cm finger-like-shaped polyp with its base in the terminal ileum approximately 5 cm proximal to ileocecal valve (► **Fig. 1**). A repeat colonoscopy was again unsuccessful.

Apart from a left nephrectomy for a renal clear cell carcinoma in 2006, the patient's past medical history was otherwise unremarkable.

He was referred to our center to undergo a retrograde single-balloon enteroscopy (SBE) (SIF-Q180; Olympus, Tokyo, Japan), which revealed the ileal polyp protruding into the cecum. The ileocecal valve was

cannulated and the polyp's origin in the ileum was confirmed. It had a finger-like shape with a pedicle 6 cm long and 2 cm thick with its base 5 cm proximal to ileocecal valve and was covered with hyperemic mucosa (► **Fig. 2**). The thickness of the polyp, occupying more than half of the ileal lumen, and especially its unstable position, made polypectomy more difficult. An endoloop (Olympus) was deployed at the base of the thick stalk and, with the scope positioned in the cecum, a transvalvular hot snare polypectomy was performed (► **Video 1**). The procedure was uneventful. The polyp was retrieved with a basket (► **Fig. 3**).

Histological examination showed an inflammatory fibroid polyp with clear margins (R0 resection) (► **Fig. 4**). This is a rare benign mesenchymal neoplasm, usually solitary and intraluminal, that may affect any part of the GI tract, although in the majority of cases it affects the stomach (antrum 75% and corpus 16%) followed by the small bowel (4.3%) [2]. Treatment may be surgical but can also be endoscopic with appropriate precautions. Such polyps do not recur following removal [2–4].

Endoscopy\_UCTN\_Code\_TTT\_1AP\_2AD

### Competing interests

The authors declare that they have no conflict of interest.

### The authors

Felice Rizzi<sup>1</sup>, Marco Sacco<sup>1</sup>, Wilma Debernardi Venon<sup>1</sup>, Do An Andrea Trinh<sup>2</sup>, Marco Pennazio<sup>1</sup>

- 1 University Hospital City of Science and Health Turin, University Division of Gastroenterology, Digestive Endoscopy Unit, Torino, Piemonte, Italy
- 2 University Hospital City of Science and Health Turin, Surgical Pathology Unit, Torino, Piemonte, Italy

### Corresponding author

**Marco Pennazio, MD**

University Division of Gastroenterology, City of Health and Science University Hospital, Via Cavour 31, 10123 Turin, Italy  
Fax: +39-011-633-3623  
pennazio.marco@gmail.com

### References

- [1] Gill SS, Heuman DM, Mihas AA. Small intestinal neoplasms. *J Clin Gastroenterol* 2001; 33: 267–282
- [2] Unal Kocabey D, Cakir E, Dirilenoglu F et al. Analysis of clinical and pathological findings in inflammatory fibroid polyps of the gastrointestinal system: a series of 69 cases. *Ann Diagn Pathol* 2018; 37: 4750
- [3] Liu TC, Lin MT, Montgomery EA et al. Inflammatory fibroid polyps of the gastrointestinal tract: spectrum of clinical, morphologic, and immunohistochemistry features. *Am J Surg Pathol* 2013; 37: 586–592
- [4] Ozolek JA, Sasatomi E, Swalsky PA et al. Inflammatory fibroid polyps of the gastrointestinal tract: clinical, pathologic, and molecular characteristics. *Appl Immunohistochem Mol Morphol* 2004; 12: 59–66

### Bibliography

Endoscopy 2022; 54: E526–E527

DOI 10.1055/a-1662-4598

ISSN 0013-726X

published online 15.11.2021

© 2021. Thieme. All rights reserved.

Georg Thieme Verlag KG, Rüdigerstraße 14, 70469 Stuttgart, Germany

### ENDOSCOPY E-VIDEOS

<https://eref.thieme.de/e-videos>



*Endoscopy E-Videos* is an open access online section, reporting on interesting cases and new techniques in gastroenterological endoscopy. All papers include a high quality video and all contributions are freely accessible online. Processing charges apply (currently EUR 375), discounts and waivers acc. to HINARI are available.

This section has its own submission website at <https://mc.manuscriptcentral.com/e-videos>