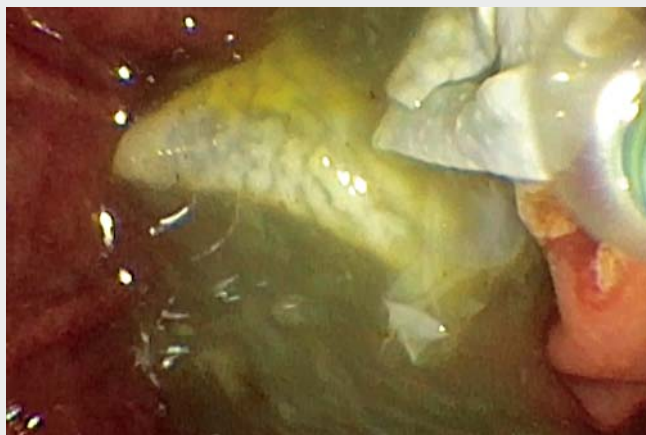
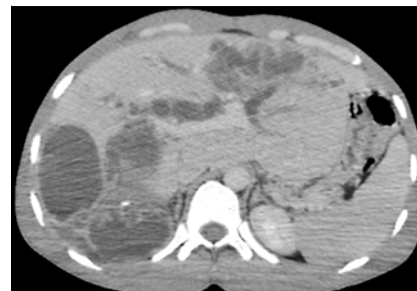


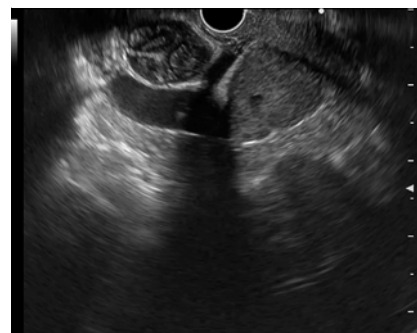Endoscopic treatment of a liver hydatid cyst with biliary rupture



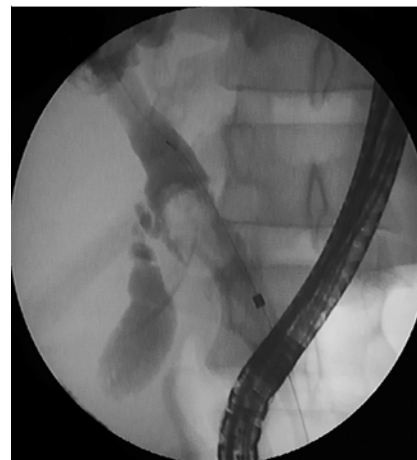▶ **Video 1** Endoscopic retrograde cholangiopancreatography in a 26-year-old man with cholangitis showing the removal of multiple hydatid membranes by balloon sweeps after endoscopic sphincterotomy.



▶ **Fig. 1** Computed tomography scan showing multiple hepatic hydatid cysts with biliary duct dilatation.



▶ **Fig. 2** Linear endoscopic ultrasound view showing multiple echogenic structures within the dilated common bile duct.



▶ **Fig. 3** Fluoroscopic view showing multiple filling defects within the proximal common bile duct.

Hydatid disease is a parasitic infection caused by the larva of *Echinococcus granulosus*, for which the liver represents the most common site of involvement [1]. One of the most serious complications of hepatic hydatid cyst disease is rupture of the cyst into the biliary tree, leading to jaundice and cholangitis. Recently endoscopic retrograde cholangiopancreatography (ERCP) has emerged as an alternative method of providing therapy for patients with biliary hydatid disease [2]. We present the case of 26-year-old man, with a history of pulmonary hydatid cyst surgery 13 years previously, who was admitted with cholangitis (▶ **Video 1**). The biochemistry tests showed hyperbilirubinemia at 6.5 mg/dL and high aminotransferase levels (>5 times normal), and he had a white blood cell count of 15000/mm³. A computed tomography scan showed multiple hepatic hydatid cysts with biliary duct dilatation and suspicion of a ruptured hydatid cyst (▶ **Fig. 1**). Linear endoscopic ultrasound performed before an ERCP showed multiple echogenic structures filling the dilated


common bile duct (CBD), evocative of hydatid membranes (▶ **Fig. 2**). Urgent ERCP was performed. The fluoroscopic view revealed multiple filling defects within the enlarged CBD (▶ **Fig. 3**). Endoscopic sphincterotomy, followed by sweeping of the bile duct with a balloon and basket, allowed removal of multiple hydatid membranes, along with debris and pus, with successful clearance of the biliary tree at the end of the procedure (▶ **Video 1**). A plastic stent (10 Fr×9 cm) was placed to ensure sufficient drainage. The endoscopic treatment resulted in a significant improvement in the patient's clinical and biochemical status, with a normal bile duct diameter at abdominal ultrasonography.

Endoscopy_UCTN_Code_CCL_1AZ_2AN

Competing interests

The authors declare that they have no conflict of interest.

The authors

Mohamed Borahma , **Yousra Jebari, Fatima Zahra Chabib, Nawal Lagdali, Imane Benelbarhdadi, Fatima Zahra Ajana**

Department of Gastroenterology C, Mohammed V University of Rabat, Ibn Sina Hospital, Rabat, Morocco

Corresponding author

Mohamed Borahma, MD

Mohammed V University of Rabat, Ibn Sina Hospital, Department of Gastroenterology C, Rabat, Morocco
borahmamed@gmail.com
m.borahma@um5r.ac.ma

References

- [1] Alghofaily KA, Saeedan MB, Aljohani IM et al. Hepatic hydatid disease complications: review of imaging findings and clinical implications. *Abdom Radiol* 2017; 42: 199–210
- [2] Borahma M, Afifi R, Benelbarhdadi I et al. Endoscopic retrograde cholangiopancreatography in ruptured liver hydatid cyst. *Indian J Gastroenterol* 2015; 34: 330–334

Bibliography

Endoscopy 2022; 54: E456–E457
DOI 10.1055/a-1625-4316
ISSN 0013-726X
published online 27.9.2021
© 2021. Thieme. All rights reserved.
Georg Thieme Verlag KG, Rüdigerstraße 14,
70469 Stuttgart, Germany

ENDOSCOPY E-VIDEOS

<https://eref.thieme.de/e-videos>



Endoscopy E-Videos is an open access online section, reporting on interesting cases and new techniques in gastroenterological endoscopy. All papers include a high quality video and all contributions are freely accessible online. Processing charges apply (currently EUR 375), discounts and waivers acc. to HINARI are available.

This section has its own submission website at
<https://mc.manuscriptcentral.com/e-videos>