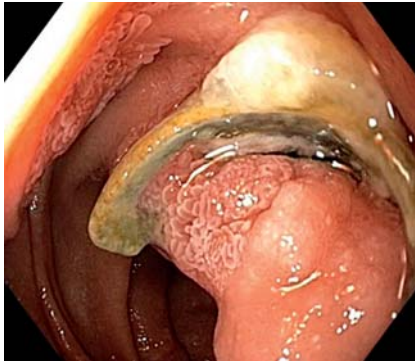
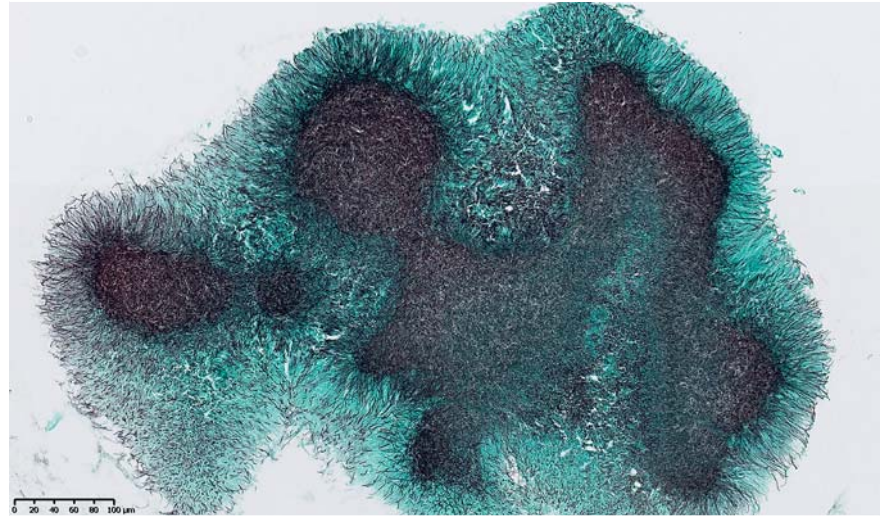


## Actinomycosis associated with a permanently implanted duodenal over-the-scope clip



► **Fig. 1** Endoscopic appearance of duodenal actinomycosis associated with an over-the-scope clip that had been in place for 11 years.

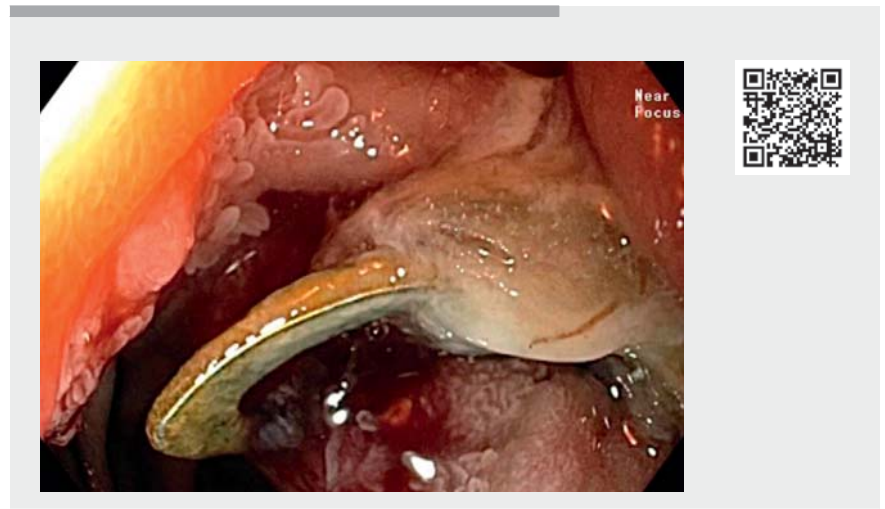

► **Fig. 2** Grocott staining showing the filamentous structures of *Actinomyces*.

The over-the-scope (OTS) clip system is a safe and effective endoscopic therapy for gastrointestinal bleeding, perforation, and leakage [1,2]. A recent review reported an overall complication rate of 1.7% [1]. We report the case of a 76-year-old woman with a complication that arose 11 years after the placement of two OTS clips (Ovesco Endoscopy AG, Tübingen, Germany).

The patient had undergone resection by hybrid endoscopic submucosal dissection of a 25-mm duodenal adenoma 11 years previously. The procedure was technically difficult owing to fibrosis and was ultimately complicated by a micro-perforation, which was managed by the placement of two OTS clips. Histology revealed a tubulovillous adenoma with low grade dysplasia.

Follow-up esophagogastroduodenoscopies showed no signs of recurrence. Biopsy specimens of the scar revealed regenerative mucosa with hyperplastic changes. Both OTS clips stayed in place for 8 years, after which spontaneous dislodgement of one OTS clip occurred. Endoscopic examination then revealed a non-dysplastic mucosal bridge – double lumen appearance of the duodenum – with one clip still correctly placed.



► **Video 1** Diagnosis, treatment and follow-up of actinomycosis associated with a permanently implanted duodenal over-the-scope clip.

Eventually 11 years after placement of the OTS clips, the mucosa surrounding the remaining clip had a villous aspect (► **Fig. 1**); biopsies were taken, which were positive for *Actinomyces* (► **Fig. 2**). A computed tomography scan was performed, which was negative for regional lymphadenopathy and regional spread. Following multidisciplinary discussion, a

penicillin-based treatment was proposed and the OTS clip was successfully extracted. A decision was made not to cut the mucosal bridge, because the patient was asymptomatic. At 6-month follow-up, no signs of recurrence were present (► **Video 1**). Abdominopelvic actinomycosis in immunocompetent people has been described

[3]. In the literature, an association with foreign bodies has been reported, predominantly with intrauterine contraceptive devices [3]. To our knowledge, this is the first published case of actinomycosis occurring in relation to an OTS clip.

Endoscopy\_UCTN\_Code\_CPL\_1AH\_2AC

### Competing interests

The authors declare that they have no conflict of interest.

### The authors

**Carina Leal**<sup>1,2</sup> , **Helene Dano**<sup>3</sup>, **Leila Belkhir**<sup>4</sup>, **Pierre H. Deprez**<sup>2</sup> 

- 1 Department of Gastroenterology, Centro Hospitalar de Leiria, Leiria, Portugal
- 2 Department of Gastroenterology, Cliniques universitaires Saint-Luc, Université catholique de Louvain, Brussels, Belgium
- 3 Department of Pathology, Cliniques universitaires Saint-Luc, Université catholique de Louvain, Brussels, Belgium
- 4 Department of Internal Medicine and Infectious diseases, Cliniques universitaires Saint-Luc, Université catholique de Louvain, Brussels, Belgium

### Corresponding author

**Carina Isabel Cordeiro Leal, MD**  
 Department of Gastroenterology, Centro Hospitalar de Leiria, Rua das Olhalvas, Leiria, 2410-197, Portugal  
 carina.leal@chleiria.min-saude.pt

### References

- [1] Kobara H, Mori H, Nishiyama N et al. Over-the-scope clip system: A review of 1517 cases over 9 years. *J Gastroenterol Hepatol* 2019; 34: 22–30
- [2] Tashima T, Ohata K, Sakai E et al. Efficacy of an over-the-scope clip for preventing adverse events after duodenal endoscopic submucosal dissection: a prospective interventional study. *Endoscopy* 2018; 50: 487–496
- [3] Wong VK, Turmezei TD, Weston VC. Actinomycosis. *BMJ* 2011; 343: d6099

### Bibliography

*Endoscopy* 2022; 54: E431–E432  
**DOI** 10.1055/a-1540-6468  
**ISSN** 0013-726X  
**published online** 8.9.2021  
 © 2021. Thieme. All rights reserved.  
 Georg Thieme Verlag KG, Rüdigerstraße 14, 70469 Stuttgart, Germany

#### ENDOSCOPY E-VIDEOS <https://eref.thieme.de/e-videos>



*Endoscopy E-Videos* is an open access online section, reporting on interesting cases and new techniques in gastroenterological endoscopy. All papers include a high quality video and all contributions are freely accessible online. Processing charges apply (currently EUR 375), discounts and waivers acc. to HINARI are available.

This section has its own submission website at  
<https://mc.manuscriptcentral.com/e-videos>