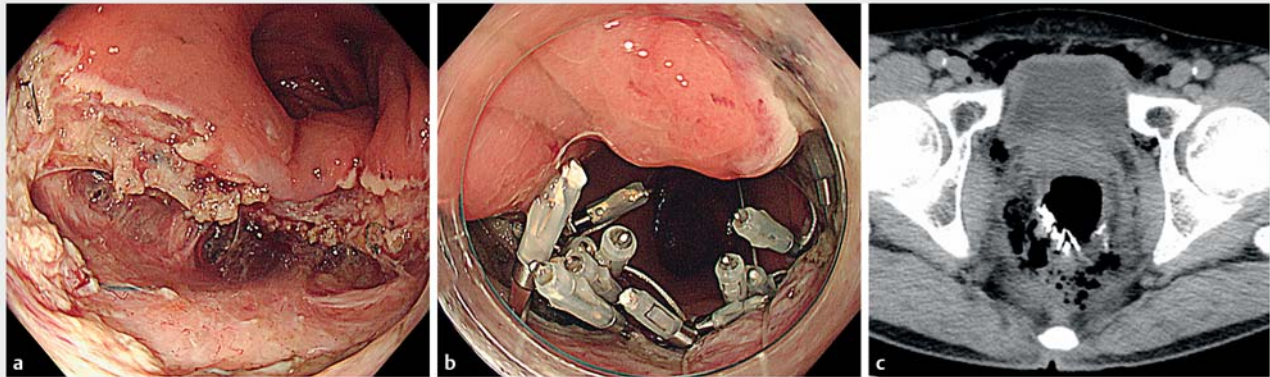


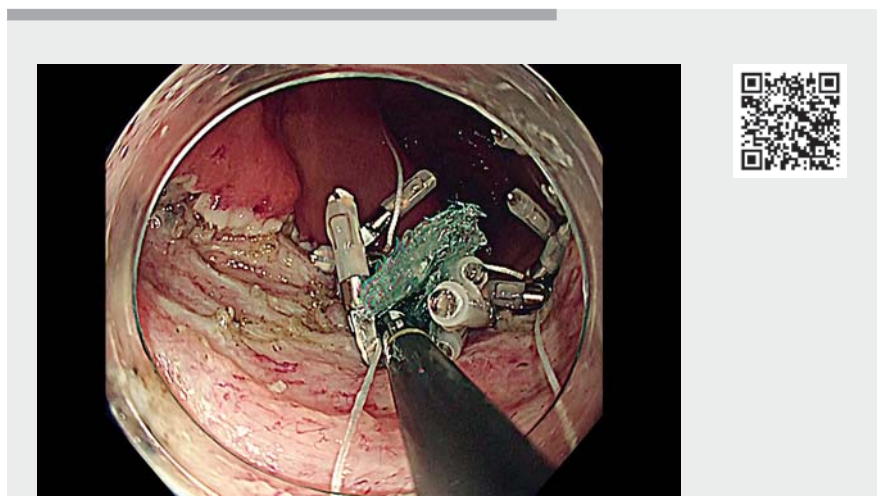
Successful closure of huge perforation during rectal endoscopic submucosal dissection using an endoscopic string clip suturing method and polyglycolic acid sheets and fibrin glue



► Fig. 1 Condition after endoscopic submucosal dissection (ESD). **a** After resection of the lesion, there was a huge perforation of about 30 mm. **b** Huge perforation during rectal ESD near the anastomosis site was closed using the endoscopic string clip suturing method and PGA sheets and fibrin glue. **c** Computed tomography after the treatment revealed a large amount of air behind the peritoneum.

Recently, endoscopic string clip suturing has been reported to be a useful suturing method [1], and polyglycolic acid (PGA) sheets and fibrin glue have been used to close perforations in the colon [2,3]. Here we report successful closure of a huge perforation during rectal endoscopic submucosal dissection (ESD) near the anastomosis site using an endoscopic string clip suturing method with the use of PGA sheets and fibrin glue.

ESD was performed in a 58-year-old man with a 20-mm adenocarcinoma on the lower rectum near the anastomosis site. During ESD, we observed very strong fibrosis and performed submucosal dissection with difficulty. We had unknowingly removed both the lesion and muscle layer. After resection of the lesion, there was a huge perforation of about 30 mm (► Fig. 1 a). We tried to close the perforation near the anastomosis site using an endoscopic string clip suturing method. Braided polyester (USP 3-0; Natsume Seisakusho Co., Ltd, Tokyo, Japan) was used as the suture thread. The site was closed using three suture clips with thread. This suture allowed the mucous membrane to be pulled to the anal side,

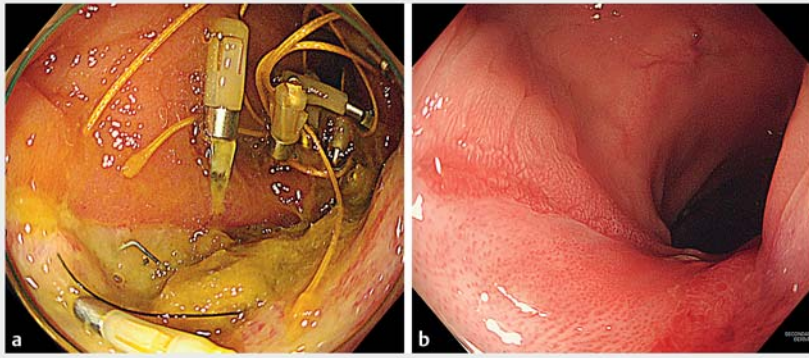


► Video 1 Closure of a huge perforation during rectal endoscopic submucosal dissection near the anastomosis site using an endoscopic string clip suturing method and polyglycolic acid sheets.

but there were gaps left in some places, making it an incomplete suture. Several small PGA sheets (2×1 cm) were packed in a gap using the method proposed by Takimoto et al. [4]. Finally, fibrin glue was sprayed (► Video 1, ► Fig. 1 b). Computed tomography after the procedure

revealed a large amount of air behind the peritoneum (► Fig. 1 c).

The ulcer was on a healing trend after 1 week (► Fig. 2 a). The length of hospital stay was 18 days. After about 2 months, the ulcer was completely cured (► Fig. 2 b).



► **Fig. 2** Endoscopic imaging of the clinical course. **a** The ulcer was on a healing trend after 1 week. **b** After about 2 months, the ulcer was completely cured.

An endoscopic string clip suturing method with the use of PGA sheets may be effective for minimizing adverse events.

Endoscopy_UCTN_Code_CPL_1AJ_2AH

Competing interests

The authors declare that they have no conflict of interest.

The authors

Satoshi Abiko^{1,2}, **Itsuki Sano**¹, **Ayumu Yoshikawa**¹, **Kazuaki Harada**¹, **Naoki Kawagishi**¹, **Hisashi Oda**¹, **Takuto Miyagishima**¹

- 1 Department of Gastroenterology, Kushiro Rosai Hospital, Kushiro, Japan
- 2 Department of Gastroenterology and Hepatology, Hakodate Municipal Hospital, Hakodate, Japan

Corresponding author

Satoshi Abiko, MD, PhD

Department of Gastroenterology and Hepatology, Hakodate Municipal Hospital, 1-10-1, Minato-cho, Hakodate, 041-8680, Japan
 Fax: +81-138-43-4434
 abiko1982@gmail.com

References

- [1] Yahagi N, Nishizawa T, Akimoto T et al. New endoscopic suturing method: string clip suturing method. *Gastrointest Endosc* 2016; 84: 1064–1065
- [2] Sakaguchi Y, Tsuji Y, Yamamichi N et al. Successful closure of a large perforation during colorectal endoscopic submucosal dissection by application of polyglycolic acid sheets and fibrin glue. *Gastrointest Endosc* 2016; 84: 374–375
- [3] Nagami Y, Fukunaga S, Kanamori A et al. Endoscopic closure using polyglycolic acid

sheets for delayed perforation after colonic endoscopic submucosal dissection. *Endoscopy* 2020; 52: E11–E12

- [4] Takimoto K, Toyonaga T, Matsuyama K. Endoscopic tissue shielding to prevent delayed perforation associated with endoscopic submucosal dissection for duodenal neoplasms. *Endoscopy* 2012; 44: E414–E415

Bibliography

Endoscopy 2022; 54: E290–E291

DOI 10.1055/a-1519-6555

ISSN 0013-726X

published online 2.7.2021

© 2021. Thieme. All rights reserved.

Georg Thieme Verlag KG, Rüdigerstraße 14, 70469 Stuttgart, Germany

ENDOSCOPY E-VIDEOS

<https://eref.thieme.de/e-videos>



Endoscopy E-Videos is an open access online section, reporting on interesting cases and new techniques in gastroenterological endoscopy. All papers include a high quality video and all contributions are freely accessible online. Processing charges apply (currently EUR 375), discounts and waivers acc. to HINARI are available.

This section has its own submission website at <https://mc.manuscriptcentral.com/e-videos>