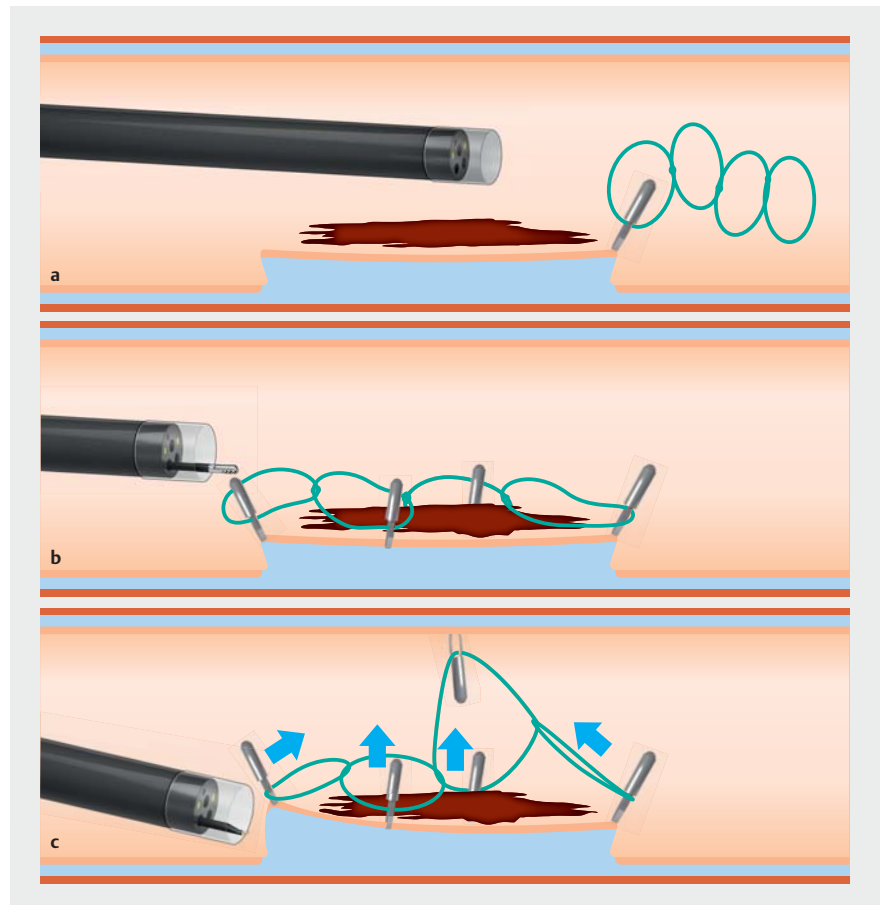


Diagnostic endoscopic submucosal dissection for invasive cancer with the four cardinal points traction strategy.

Endoscopic submucosal dissection (ESD) is the reference technique to achieve en bloc resection of a superficial neoplasm located in the gastrointestinal tract [1]. Nevertheless, this method is technically challenging, can be time-consuming, and is often reserved for experts. New strategies to facilitate the procedure are requested. Although countertraction strategies by enlarging the submucosal space, like in the clip and rubber band approach, make dissection easier in the front of the lesion, lateral side and distal incisions are sometimes difficult to dissect because of the angle effect [2–5]. Therefore, to avoid these limitations, we propose the new “four cardinal points strategy” to apply traction to the complete lesion with a wire with four loops attached at four opposite edges after circumferential incision.

We report the case of a 73-year-old woman referred to our center for ESD of a 2-cm adenocarcinoma situated in the rectum, 8 cm away from the anal margin. The lesion was classified as a pseudo-depressed non-granular laterally spreading tumor, with a Kudo Vn, Sano’s 3B 8-mm nodule. After circumferential incision, a wire with four loops was fixed with hemoclips at four opposite edges of the lesion. The four loops were then trapped with another metallic clip that was fixed to the opposite mucosal wall (► **Fig. 1**, ► **Video 1**). Thanks to the quadruple traction of this new strategy, a diagnostic resection of the lesion was made in 30 minutes.

This new procedure must be compared to other traction strategies but seems to offer strong countertraction with a perpendicular angle maintained for the complete lesion. Stretching all edges simul-



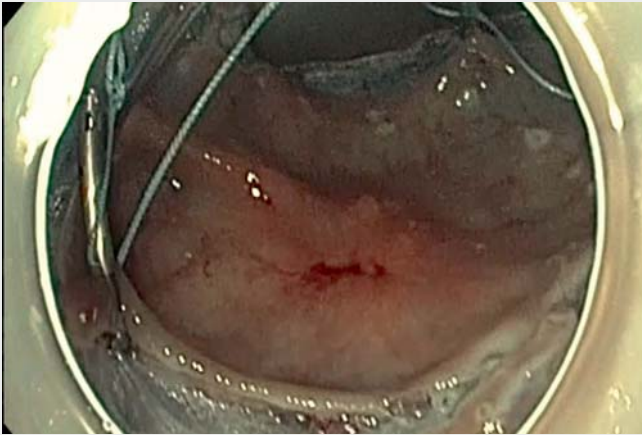► **Fig. 1** Schematic view of the “four cardinal points strategy”. **a** After circumferential incision, placement of first clip with the wire with four loops. **b** Placement of other clips at opposite edges. **c** Traction obtained by fixing all clips to the opposite mucosal wall, and dissection of the stretched submucosa.

taneously allows removing the muscle from the cutting line, and the traction remains constant throughout the dissection. This technique could facilitate ESD, especially in the case of diagnostic dissection for invasive cancer.

Endoscopy_UCTN_Code_TTT_1AQ_2AD

Competing interests

The authors declare that they have no conflict of interest.



Video 1 Diagnostic endoscopic submucosal dissection for invasive cancer using the four cardinal points traction strategy.

- [4] Jacques J, Legros R, Rivory J et al. The “tunnel + clip” strategy standardised and facilitates oesophageal ESD procedures: a prospective, consecutive bi-centric study. *Surg Endosc* 2017; 31: 4838–4847. doi:10.1007/s00464-017-5514-0
- [5] Lupu A, Jacques J, Rivory J et al. Endoscopic submucosal dissection with triangulated traction with clip and rubber band: the “wallet” strategy. *Endoscopy* 2018; 50: E256–E258. doi:10.1055/a-0624-1721

Bibliography

Endoscopy 2022; 54: E281–E282

DOI 10.1055/a-1516-3680

ISSN 0013-726X

published online 2.7.2021

© 2021. Thieme. All rights reserved.

Georg Thieme Verlag KG, Rüdigerstraße 14, 70469 Stuttgart, Germany

ENDOSCOPY E-VIDEOS

<https://eref.thieme.de/e-videos>



Endoscopy E-Videos is an open access online section, reporting on interesting cases and new techniques in gastroenterological endoscopy. All papers include a high quality video and all contributions are freely accessible online. Processing charges apply (currently EUR 375), discounts and waivers acc. to HINARI are available.

This section has its own submission website at

<https://mc.manuscriptcentral.com/e-videos>

The authors

Pierre Lafeuille¹, Jérôme Rivory¹, Jérémie Jacques², Florian Rostain¹, Paul Bonniaud¹, Thomas Lambin¹, Mathieu Pioche¹

- 1 Department of Endoscopy and Hepato-Gastroenterology, Pavillon L, Edouard Herriot Hospital, Lyon, France
- 2 Department of Gastroenterology and Endoscopy, Dupuytren University Hospital, Limoges, France

Corresponding author

Mathieu Pioche, MD

Endoscopy Unit – Digestive Disease Department, Pavillon L – Edouard Herriot Hospital, 69437 Lyon Cédex, France
mathieu.pioche@chu-lyon.fr

References

- [1] Pimentel-Nunes P, Dinis-Ribeiro M, Ponchon T et al. Endoscopic submucosal dissection: European Society of Gastrointestinal Endoscopy (ESGE) Guideline. *Endoscopy* 2015; 47: 829–854. doi:10.1055/s-0034-1392882
- [2] Utzeri E, Jacques J, Charissoux A et al. Traction strategy with clips and rubber band allows complete en bloc endoscopic submucosal dissection of laterally spreading tumors invading the appendix. *Endoscopy* 2017; 49: 820–822. doi:10.1055/s-0043-111713
- [3] Jacques J, Charissoux A, Legros R et al. Double-clip counter-traction using a rubber band is a useful and adaptive tool for colonic endoscopic submucosal dissection. *Endoscopy* 2018; 50: 179–181. doi:10.1055/s-0043-122596