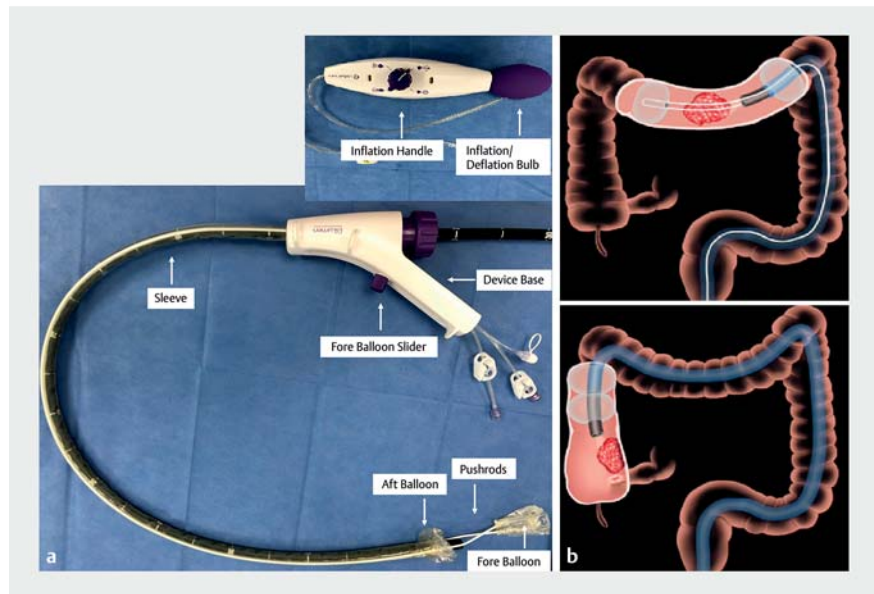


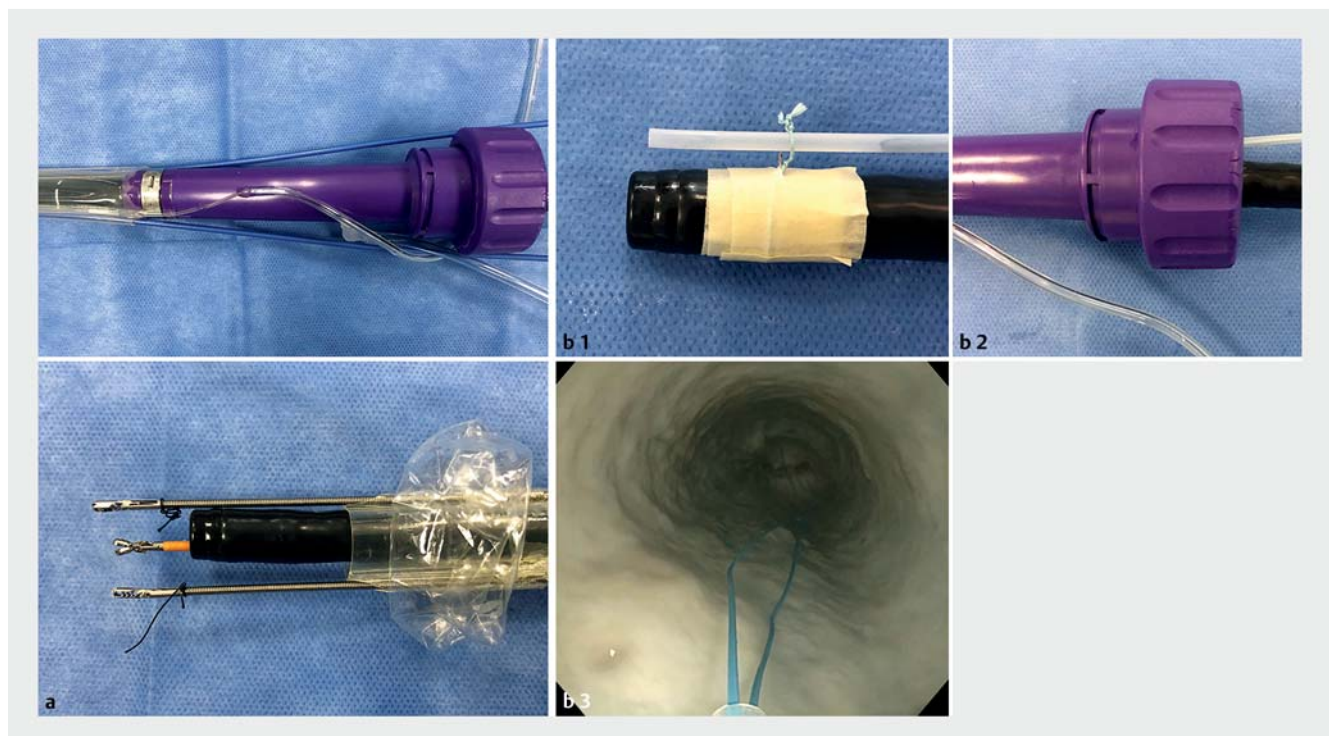
Use of endoscopic sleeve to achieve full-thickness endoscopic resection of malignant polyp under direct vision

Therapeutic decisions for early-stage colon cancer discovered after polypectomy are complex [1]. Surgical colectomy is associated with a low rate of residual cancer, but significant morbidity. In select patients, endoscopic full-thickness resection (EFTR) may be an option [2,3]. We report EFTR using an endoscopic sleeve (Dilumen; Lumendi) with multiple endoscopic tools.

The endoscopic sleeve has two balloons to improve the navigation and stability of the colon. The fore-balloon is extended using pushrods to create the “therapeutic zone” [4]. However, the fore-balloon cannot be deployed in the cecum or near an anastomosis (► Fig. 1). In the present case, the fore-balloon and pushrods were removed in order to use two additional instruments via the empty pushrod channels. Moreover, one additional tool

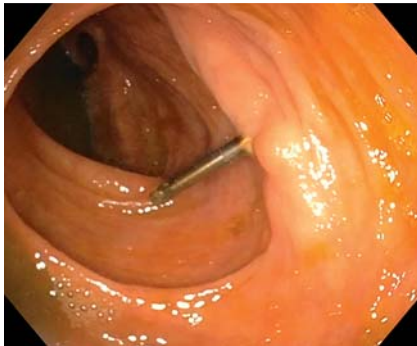


► Fig. 1 a An endoscopic sleeve (Dilumen, Lumendi). b Use of the endoscopic sleeve in the transverse colon and the cecum.



► Fig. 2 a Removal of fore-balloon and pushrods enables the use of two endoscopic tools through the sleeve channels. b A 3-0 silk loop was tied around the colonoscope at 6 o'clock, about 2 cm from the tip. A PolyLoop was passed through the 3-0 silk loop and reinserted through the sleeve alongside the colonoscope.

attached to the endoscope tip can be passed through the sleeve (► **Fig. 2**) [5]. A 73-year-old man underwent polypectomy near an ileocolic anastomosis. Pathology showed invasive adenocarcinoma and a residual lesion was suspected; therefore, EFTR was planned. A colonoscope (Olympus) with the sleeve was advanced to the scarred lesion (► **Fig. 3**). A



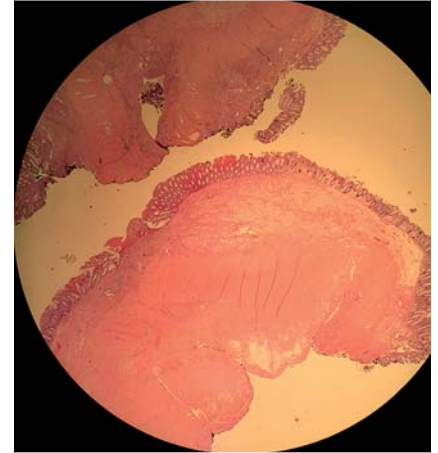
► **Fig. 3** An elevated and scarred lesion located near the ileocolic anastomosis.

PolyLoop (Olympus) attached to the endoscope tip was opened around the lesion. Two graspers (Steris) inserted through the sleeve channels were navigated to the lesion with a biopsy forceps (Boston Scientific) through the endoscopic channel, and the lesion was grasped and pulled up through the PolyLoop. The PolyLoop was positioned with the biopsy forceps. Once the PolyLoop was secured, the isolated lesion was excised with a snare (Boston Scientific). The defect was closed with clips (Boston Scientific), reinforcing the PolyLoop closure (► **Fig. 4**). Procedure time was 95 min. The patient was discharged on the day of the procedure without complications. Pathology showed no malignant cells in the full-thickness specimen (► **Fig. 5**; ► **Video 1**).

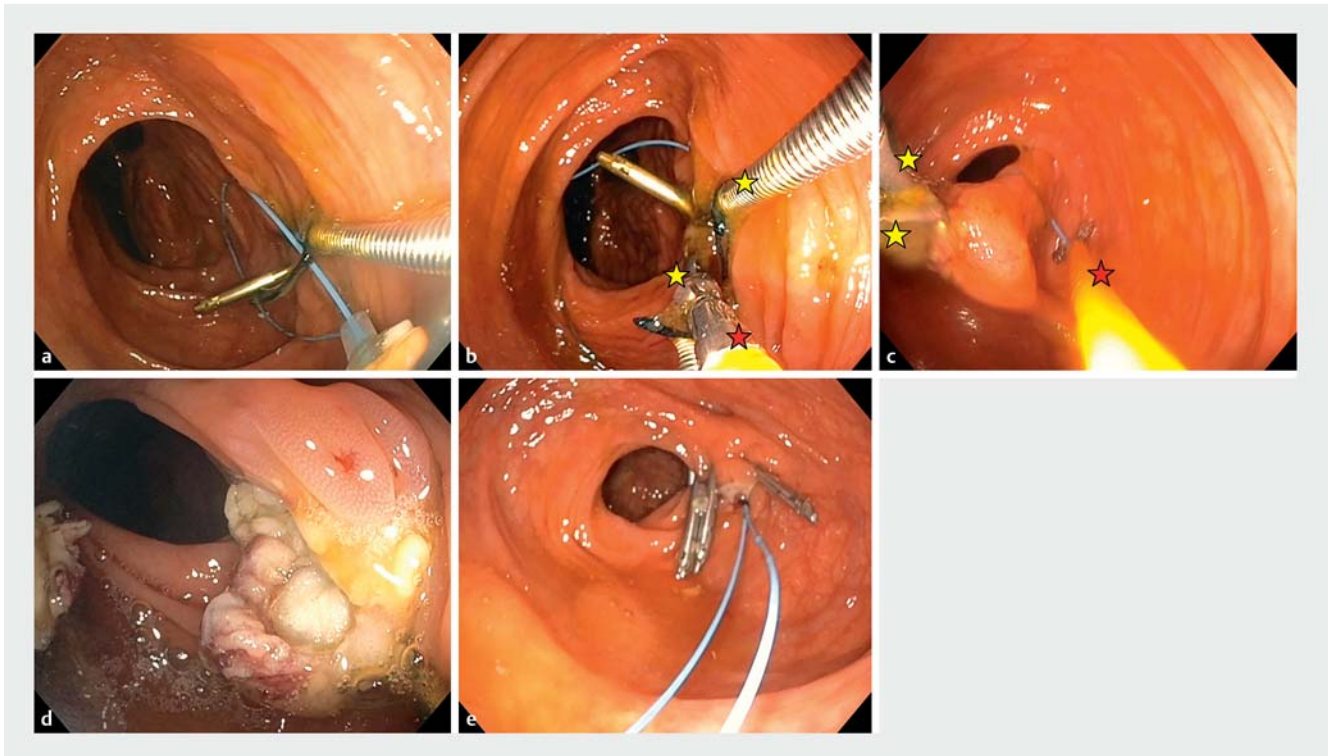
The use of two graspers and a PolyLoop could provide more retraction and enable the removal of larger lesions under direct vision. This type of endoscopic sleeve can be adapted to permit multiple

channels and tools, enabling EFTR in the colon.

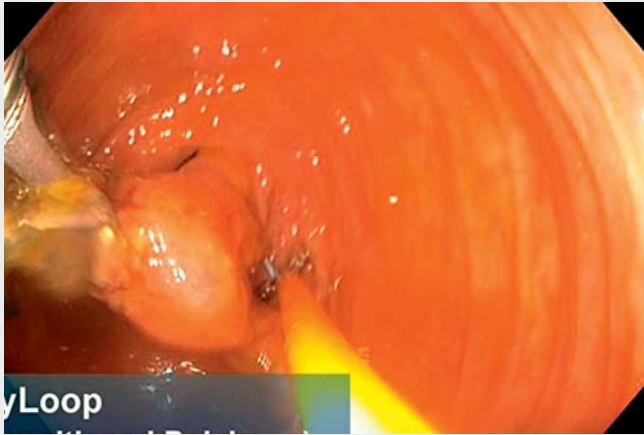
Endoscopy_UCTN_Code_TTT_1AQ_2AD



► **Fig. 5** Pathological findings revealed that the resected specimen included all layers from mucosa to serosa, and there were no malignant cells.



► **Fig. 4** Endoscopic full-thickness resection using an endoscopic sleeve with multiple endoscopic tools: **a** The PolyLoop was placed around the lesion. **b** The lesion was grasped with two graspers inserted through the sleeve channels. **c** The lesion was lifted using the graspers through the PolyLoop, and the PolyLoop was positioned with the biopsy forceps around the area of interest. **d** The PolyLoop was closed, and the lesion was then excised with an endoscopic snare. **e** Finally, the defect was closed with endoscopic clips. Red stars: endoscopic graspers; yellow stars: biopsy forceps.



Video 1 Endoscopic full-thickness resection near an ileocolic anastomosis using an endoscopic sleeve with multiple endoscopic tools.

Bibliography

Endoscopy 2022; 54: E350–E352

DOI 10.1055/a-1516-3635

ISSN 0013-726X

published online 19.7.2021

© 2021. Thieme. All rights reserved.

Georg Thieme Verlag KG, Rüdigerstraße 14,

70469 Stuttgart, Germany

ENDOSCOPY E-VIDEOS

<https://eref.thieme.de/e-videos>



Endoscopy E-Videos is an open access online section, reporting on interesting cases and new techniques in gastroenterological endoscopy. All papers include a high quality video and all contributions are freely accessible online. Processing charges apply (currently EUR 375), discounts and waivers acc. to HINARI are available.

This section has its own submission website at

<https://mc.manuscriptcentral.com/e-videos>

Competing interests

The authors declare that they have no conflict of interest.

The authors

Shinya Urakawa, Tejiro Hirashita, Yuka Hirashita, Kentaro Matsuo, Lea Lowenfeld, Jeffrey W. Milsom

Section of Colon and Rectal Surgery,
Department of Surgery, Weill Cornell Medicine/
New York-Presbyterian Hospital, New York, New
York, USA

Corresponding author

Jeffrey W. Milsom, MD

Department of Surgery, Weill Cornell
Medicine/New York-Presbyterian Hospital,
525 East 68th Street, K-801 New York, NY
10065, USA
jwm2001@med.cornell.edu

References

- [1] Shin JW, Han KS, Hyun JH et al. Risk of recurrence after endoscopic resection of early colorectal cancer with positive margins. *Endoscopy* 2018; 50: 241–247
- [2] Committee AT, Aslanian HR, Sethi A et al. ASGE guideline for endoscopic full-thickness resection and submucosal tunnel endoscopic resection. *VideoGIE* 2019; 4: 343–350
- [3] Fahmawi Y, Hanjar A, Ahmed Y et al. Efficacy and safety of full-thickness resection device (FTRD) for colorectal lesions endoscopic full-thickness resection: a systematic review and meta-analysis. *J Clin Gastroenterol* 2020. doi:10.1097/MCG.0000000000001410
- [4] Sharma SK, Momose K, Sedrakyan A et al. Endoscopic stabilization device evaluation using IDEAL framework: a quality improvement study. *Int J Surg* 2019; 67: 18–23
- [5] Urakawa S, Momose K, Hirashita T et al. Endoscopic submucosal dissection of large polyps in the right colon using an endoscopic snare with a double-balloon endoluminal interventional platform: an ex vivo study in a porcine colorectal model. *Surg Endosc* 2020. doi:10.1007/s00464-020-08100-7