

Celiac Artery Thrombosis and Splenic Infarction as a Consequence of Mild COVID-19 Infection: Report of an Unusual Case

Gokhan Arslan¹ 

¹ Department of Cardiovascular Surgery, Gulhane Faculty of Medicine, University of Health Sciences, Ankara, Turkey

Hamostaseologie 2022;42:193–194.

Address for correspondence Gokhan Arslan, MD, Department of Cardiovascular Surgery, Gulhane Faculty of Medicine, University of Health Sciences, 06010 Etlik, Ankara, Turkey (e-mail: drgokhanarslan@gmail.com).

Abstract

Keywords

- ▶ COVID-19
- ▶ thrombosis
- ▶ celiac artery thrombosis
- ▶ splenic infarction

COVID-19 has been associated with the hypercoagulable state in the literature. Patients who are admitted to the hospital with severe COVID-19 may have some thrombotic complications. These patients have a high risk for venous and arterial thrombosis of large and small vessels. Here, a 42-year-old female with celiac artery thrombosis and splenic infarction after a history of mild COVID-19 was presented.

Introduction

COVID-19 often causes venous thrombosis and rarely causes arterial thrombosis. These effects are mainly from the three main factors of thrombosis: endothelium, platelets, and coagulation factors.^{1,2} Here, we present a 42-year-old female patient with a history of mild COVID-19, treated for celiac artery thrombosis and splenic infarction.

Case Presentation

A 42-year-old female patient with nonsignificant past medical history was admitted to the hospital with the complaint of upper left quadrant abdominal pain. In the emergency department, she had a normal vital sign for a healthy adult at rest. Body mass index was 27 kg/m². On examination, she had left-upper-quadrant tenderness without rebound and guarding. Laboratory evaluation was remarkable for lactate dehydrogenase (284 U/L), fibrinogen (420 mg/dL), and C-reactive protein (35 mg/L). The complete blood cell count, D-dimer level, creatinine level, hepatic panel, blood sugar level, electrolytes, and coagulation tests results were normal. A wedge-shaped hypo-enhancing region of the spleen and also hypodense thrombus was identified in the trunk of

the celiac artery on the multiplanar reformats of the computed tomographic (CT) images (→Fig. 1). Transthoracic echocardiography was normal. The patient has no medical drug history of oral contraceptives or hormonal substitution therapy. Of note, she was diagnosed with COVID-19 infection 6 weeks earlier. She had mild flulike symptoms for a few days. She was treated by her family physician with 400 mg of hydroxychloroquine daily for 5 days as a result of the diagnosis of COVID-19 infection. SARS-CoV-2 RNA was detected in her respiratory samples by RT-PCR. Doctors of general surgery, haematology, and cardiovascular surgery evaluated the patient. Decided treatment was using 24-hour intravenous heparin therapy, followed by 1 mg/kg enoxaparin SC twice daily and acetylsalicylic acid 100 mg PO once daily for 3 months. No complications were observed in the patient during the 3-month follow-up. Control arterial phase CT images at 3 months after the treatment showed a reduction in spleen volume with wedge-shaped hypodense chronic infarct areas, the disappearance of the thrombus in the celiac artery, and development of focal intimal flap and ectasia at this location (→Fig. 2). Remarkably all the laboratory tests (antinuclear antibody, anti-phospholipid antibody panel, and hereditary thrombophilia panel) were negative.

received

February 2, 2021

accepted after revision

May 12, 2021

© 2021. Thieme. All rights reserved.
Georg Thieme Verlag KG,
Rüdigerstraße 14,
70469 Stuttgart, Germany

DOI <https://doi.org/10.1055/a-1508-7388>.
ISSN 0720-9355.

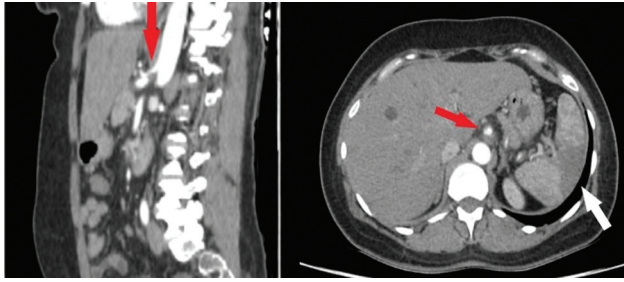


Fig. 1 Contrast-enhanced spiral CT shows a wedge-shaped hypodense region of the spleen consistent with splenic infarction (white arrow), and shows thrombus in the trunk of the celiac artery (red arrows).

Conclusion

It is emphasized that the splenic infarction in a young patient with mild COVID-19 infection is the result of a thrombotic event of SARS-CoV-2. Anticoagulants and antiplatelet therapy are not recommended to prevent venous thromboembolism or arterial thrombosis in outpatient clinics with COVID-19 patients.³ However, all clinicians, especially emergency physicians, should be aware that COVID-19 infection can cause thrombotic complications in both acute and subacute periods. The presented case suggests that mild COVID-19 infection may result in an increased risk of thromboembolic events, possibly due to viral endothelial involvement, even in the absence of thrombotic risk factors.^{4,5}

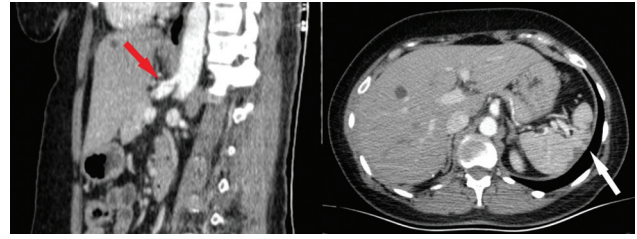


Fig. 2 Control arterial phase CT images at 3 months after treatment show reduction in spleen volume with wedge-shaped hypodense chronic infarct areas (white arrow) and disappearance of the thrombus in the celiac artery and developed focal intimal flap and ectasia at this location (red arrow).

Conflict of Interest

The author declares that he has no conflict of interest.

References

- 1 Becker RC. COVID-19 update: COVID-19-associated coagulopathy. *J Thromb Thrombolysis* 2020;50(01):54–67
- 2 Kamel MH, Yin W, Zavaro C, Francis JM, Chitalia VC. Hyperthrombotic milieu in COVID-19 patients. *Cells* 2020;9(11):2392
- 3 COVID-19 Treatment Guidelines Panel. Coronavirus Disease 2019 (COVID-19) Treatment Guidelines. National Institutes of Health Accessed May 31, 2021 at: <https://www.covid19treatmentguidelines.nih.gov/>
- 4 Varga Z, Flammer AJ, Steiger P, et al. Endothelial cell infection and endotheliitis in COVID-19. *Lancet* 2020;395(10234):1417–1418
- 5 Langer F, Kluge S, Klamroth R, Oldenburg J. Coagulopathy in COVID-19 and its implication for safe and efficacious thromboprophylaxis. *Hamostaseologie* 2020;40(03):264–269