

# AGO Recommendations for the Surgical Therapy of the Axilla After Neoadjuvant Chemotherapy: 2021 Update

## AGO-Empfehlungen zur operativen Therapie der Axilla nach neoadjuvanter Chemotherapie: Update 2021



### Authors

Michael Friedrich<sup>1</sup>, Thorsten Kühn<sup>2</sup>, Wolfgang Janni<sup>3</sup>, Volkmar Müller<sup>4</sup>, Maggie Banys-Paluchowski<sup>5,6</sup>, Cornelia Kolberg-Liedtke<sup>7</sup>, Christian Jackisch<sup>8</sup>, David Krug<sup>9</sup>, Ute-Susann Albert<sup>10</sup>, Ingo Bauerfeind<sup>11</sup>, Jens Blohmer<sup>7</sup>, Wilfried Budach<sup>12</sup>, Peter Dall<sup>13</sup>, Eva M. Fallenberg<sup>14</sup>, Peter A. Fasching<sup>15</sup>, Tanja Fehm<sup>16</sup>, Bernd Gerber<sup>17</sup>, Oleg Gluz<sup>18</sup>, Volker Hanf<sup>19</sup>, Nadia Harbeck<sup>20</sup>, Jörg Heil<sup>21</sup>, Jens Huober<sup>22</sup>, Hans-Heinrich Kreipe<sup>23</sup>, Sherko Kümmel<sup>24</sup>, Sibylle Loibl<sup>25</sup>, Diana Lüftner<sup>26</sup>, Michael Patrick Lux<sup>27</sup>, Nicolai Maass<sup>28</sup>, Volker Möbus<sup>29</sup>, Christoph Mundhenke<sup>28</sup>, Ulrike Nitz<sup>18</sup>, Tjong-Won Park-Simon<sup>30</sup>, Toralf Reimer<sup>17</sup>, Kerstin Rhiem<sup>31</sup>, Achim Rody<sup>32</sup>, Marcus Schmidt<sup>33</sup>, Andreas Schneeweiss<sup>21</sup>, Florian Schütz<sup>34</sup>, Hans-Peter Sinn<sup>35</sup>, Christine Solbach<sup>36</sup>, Erich-Franz Solomayer<sup>37</sup>, Elmar Stickeler<sup>38</sup>, Christoph Thomssen<sup>39</sup>, Michael Untch<sup>40</sup>, Isabell Witzel<sup>4</sup>, Achim Wöckel<sup>10</sup>, Marc Thill<sup>41</sup>, Nina Ditsch<sup>42</sup>

### Affiliations

- 1 Klinik für Frauenheilkunde und Geburtshilfe, HELIOS Klinikum Krefeld, Krefeld, Germany
- 2 Gynäkologie, Klinikum Esslingen, Esslingen, Germany
- 3 Frauenklinik, Klinikum der Universität Ulm, Ulm, Germany
- 4 Klinik und Poliklinik für Gynäkologie, Universitätsklinikum Hamburg-Eppendorf, Hamburg, Germany
- 5 Klinik für Frauenheilkunde und Geburtshilfe, UK-SH, Lübeck, Germany
- 6 Medizinische Fakultät, Heinrich-Heine-Universität Düsseldorf, Düsseldorf, Germany
- 7 Klinik für Gynäkologie mit Brustzentrum des Universitätsklinikums der Charité, Berlin, Germany
- 8 Klinik für Gynäkologie und Geburtshilfe, Sana Klinikum Offenbach, Offenbach, Germany
- 9 Universitätsklinikum Schleswig-Holstein, Klinik für Strahlentherapie, Campus Kiel, Kiel, Germany
- 10 Klinik für Frauenheilkunde und Geburtshilfe, Universitätsklinikum Würzburg, Würzburg, Germany
- 11 Frauenklinik, Klinikum Landshut gemeinnützige GmbH, Landshut, Germany
- 12 Strahlentherapie, Radiologie Düsseldorf, Universitätsklinikum Düsseldorf, Düsseldorf, Germany
- 13 Frauenklinik, Städtisches Klinikum Lüneburg, Lüneburg, Germany
- 14 Klinikum der Universität München, Campus Großhadern, Institut für Klinische Radiologie, München, Germany
- 15 Universitätsklinikum Erlangen, Frauenklinik, Erlangen, Germany
- 16 Klinik für Gynäkologie und Geburtshilfe, Universitätsklinikum Düsseldorf, Düsseldorf, Germany
- 17 Universitätsfrauenklinik am Klinikum Südstadt, Klinikum Südstadt Rostock, Rostock, Germany
- 18 Evangelisches Krankenhaus Bethesda, Brustzentrum, Mönchengladbach, Germany
- 19 Frauenklinik, Nathanstift Klinikum Fürth, Fürth, Germany
- 20 Brustzentrum, Klinik für Gynäkologie und Geburtshilfe, Klinikum der Ludwig-Maximilians-Universität, München, Germany
- 21 Universitäts-Klinikum Heidelberg, Brustzentrum, Heidelberg, Germany
- 22 Klinik für Gynäkologie und Geburtshilfe, Universitätsklinikum Ulm, Ulm, Germany
- 23 Institut für Pathologie, Medizinische Hochschule Hannover, Hannover, Germany
- 24 Evangelische Kliniken Essen Mitte, Essen, Germany
- 25 German Breast Group Forschungs GmbH, Neu-Isenburg, Germany
- 26 Medizinische Klinik mit Schwerpunkt Hämatologie, Onkologie und Tumorummunologie, Charité, Berlin, Germany
- 27 Kooperatives Brustzentrum Paderborn, Klinik für Gynäkologie und Geburtshilfe, Frauenklinik, St. Louise, Paderborn, St. Josefs-Krankenhaus, Salzkotten, St. Vincenz Krankenhaus GmbH, Germany
- 28 Klinik für Gynäkologie und Geburtshilfe, Universitätsklinikum Schleswig-Holstein, Campus Kiel, Kiel, Germany
- 29 Klinik für Gynäkologie und Geburtshilfe, Klinikum Frankfurt Höchst GmbH, Frankfurt am Main, Germany
- 30 Klinik für Gynäkologie und Geburtshilfe, Universitätsklinikum Hannover, Hannover, Germany
- 31 Zentrum Familiärer Brust- und Eierstockkrebs, Universitätsklinikum Köln, Köln, Germany
- 32 Klinik für Gynäkologie und Geburtshilfe, Universitätsklinikum Schleswig-Holstein, Campus Lübeck, Lübeck, Germany

- 33 Klinik und Poliklinik für Geburtshilfe und Frauengesundheit der Johannes-Gutenberg-Universität Mainz, Mainz, Germany
- 34 Klinik für Gynäkologie und Geburtshilfe, Diakonissen Krankenhaus Speyer, Speyer, Germany
- 35 Sektion Gynäkopathologie, Pathologisches Institut, Universitätsklinikum Heidelberg, Heidelberg, Germany
- 36 Klinik für Frauenheilkunde und Geburtshilfe, Universitätsklinikum Frankfurt, Frankfurt am Main, Germany
- 37 Klinik für Frauenheilkunde, Geburtshilfe und Reproduktionsmedizin, Universitätsklinikum des Saarlandes, Homburg, Germany
- 38 Klinik für Gynäkologie und Geburtsmedizin, Universitätsklinikum Aachen, Aachen, Germany
- 39 Universitätsfrauenklinik, Martin-Luther-Universität Halle-Wittenberg, Halle-Wittenberg, Germany
- 40 Klinik für Gynäkologie und Geburtshilfe, Helios Klinikum Berlin-Buch, Berlin, Germany
- 41 Klinik für Gynäkologie und Gynäkologische Onkologie, Agaplesion Markus Krankenhaus, Frankfurt am Main, Germany
- 42 Frauenklinik, Universitätsklinikum Augsburg, Augsburg, Germany

#### Key words

breast cancer, neoadjuvant chemotherapy, sentinel LNE, targeted axillary dissection

#### Schlüsselwörter

Mammakarzinom, neoadjuvante Chemotherapie, Sentinel-Lymphknoten-Entfernung, gezielte axilläre Dissektion

received 21. 4. 2021

accepted after revision 4. 5. 2021

#### Bibliography

Geburtsh Frauenheilk 2021; 81: 1112–1120

DOI 10.1055/a-1499-8431

ISSN 0016-5751

© 2021. The Author(s).

This is an open access article published by Thieme under the terms of the Creative Commons Attribution-NonDerivative-NonCommercial-License, permitting copying and reproduction so long as the original work is given appropriate credit. Contents may not be used for commercial purposes, or adapted, remixed, transformed or built upon. (<https://creativecommons.org/licenses/by-nc-nd/4.0/>)

Georg Thieme Verlag KG, Rüdigerstraße 14, 70469 Stuttgart, Germany

#### Correspondence

Prof. Michael Friedrich

HELIOS Klinikum Krefeld, Klinik für Frauenheilkunde und Geburtshilfe

Lutherplatz 40, 47805 Krefeld, Germany

michael.friedrich@helios-gesundheit.de



Deutsche Version unter:

<https://doi.org/10.1055/a-1499-8431>

#### ABSTRACT

For many decades, the standard procedure to treat breast cancer included complete dissection of the axillary lymph nodes. The aim was to determine histological node status, which was then used as the basis for adjuvant therapy, and to ensure locoregional tumour control. In addition to the debate on how to optimise the therapeutic strategies of systemic treatment and radiotherapy, the current discussion focuses on improving surgical procedures to treat breast cancer. As neoadjuvant chemotherapy is becoming increasingly important, the surgical procedures used to treat breast cancer, whether they are breast surgery or axillary dissection, are changing. Based on the currently available data, carrying out SLNE prior to neoadjuvant chemotherapy is not recommended. In contrast, surgical axillary management after neoadjuvant chemotherapy is considered the procedure of choice for axillary staging and can range from SLNE to TAD and ALND. To reduce the rate of false negatives during surgical staging of the axilla in pN<sup>+</sup><sub>CNB</sub> stage before NACT and ycN0 after NACT, targeted axillary dissection (TAD), the removal of > 2 SLNs (SLNE, no untargeted axillary sampling), immunohistochemistry to detect isolated tumour cells and micro-metastases, and marking positive lymph nodes before NACT should be the standard approach. This most recent update on surgical axillary management describes the significance of isolated tumour cells and micro-metastasis after neoadjuvant chemotherapy and the clinical consequences of low volume residual disease diagnosed using SLNE and TAD and provides an overview of this year's AGO recommendations for surgical management of the axilla during primary surgery and in relation to neoadjuvant chemotherapy.

#### ZUSAMMENFASSUNG

Über viele Jahrzehnte war die komplette Ausräumung der axillären Lymphknoten im Sinne einer Axilladisektion ein Standardverfahren in der Therapie des Mammakarzinoms. Die Zielsetzung lag in der Bestimmung des histologischen Nodalstatus für die Festlegung der adjuvanten Therapie sowie in der Sicherung der lokoregionären Tumorkontrolle. Neben der Diskussion zur Optimierung der Therapiestrategien in der systemischen Behandlung und in der Strahlentherapie fokussieren aktuelle Diskussionen insbesondere auch auf die Verbesserung der chirurgischen Maßnahmen beim Mammakarzinom. Unter Berücksichtigung der zunehmenden Bedeutung der neoadjuvanten Chemotherapie erfährt die operative Behandlung des Mammakarzinoms sowohl im Bereich der Brust als auch im Bereich der Achselhöhle einen Wandel. Basierend auf der derzeitigen Datenlage wird die SLNE vor einer neoadjuvanten Chemotherapie grundsätzlich nicht empfohlen. Demgegenüber wird die operative axilläre Intervention – von der SLNE über die TAD bis zur ALND – nach der neoadjuvanten Chemotherapie als Vorgehen der Wahl zum axillären Staging angesehen. Zur Verringerung der Falsch-negativ-Rate des operativen Stagings der Axilla bei pN<sup>+</sup><sub>CNB</sub> vor NACT und ycN0

nach NACT sind Targeted axillary Dissection (TAD), die Entfernung von > 2 SLNs (SLNE, kein ungezieltes axilläres Sampling), die Immunhistochemie zur Detektion von isolierten Tumorzellen oder Mikrometastasen und die Markierung von positiven Lymphknoten vor NACT als Standard anzusehen. In dem aktuellen Update zur operativen axillären Intervention wird auf die Bedeutung von isolierten Tumorzellen und Mikrometastasen

nach neoadjuvanter Chemotherapie und die klinischen Konsequenzen einer mittels SLNE und TAD diagnostizierten Low Volume residual Disease eingegangen und ein Überblick bez. der diesjährigen AGO-Empfehlungen zum operativen Management der Axilla im Rahmen der Primäroperation und im Zusammenhang mit der neoadjuvanten Chemotherapie gegeben.

## Introduction

Every year, the Breast Committee of the German Gynaecological Oncology Working Group (AGO) updates its recommendations on the prevention, diagnosis and therapy of breast cancer (Breast Care, 2021, in press; <https://www.ago-online.de/ago-kommissionen/kommission-mamma>).

For the first time, the current update on surgical axillary management is going into more detail about the significance of isolated tumour cells and micro-metastasis after neoadjuvant chemotherapy (NACT) and the clinical consequences of low volume residual disease diagnosed based on SLNE und TAD. This article provides an overview of this year's AGO recommendations (► **Tables 1 to 3**) on surgical management of the axilla in primary surgery and in relation to neoadjuvant chemotherapy [1].

## Surgical Management of the Axilla in Primary Surgery

For many decades, complete dissection of the ipsilateral axillary lymph nodes (ALND – axillary lymph node dissection) in addition to breast surgery was considered the standard procedure to treat breast cancer. The aim of lymph node dissection was to determine the histological node status (pN stage) as one of the most important parameters determining the appropriate adjuvant therapeutic approach. Moreover, ensuring locoregional tumour control by removing the tumour burden was considered an important objective of the procedure. However, ALND is associated with high morbidity rates, which have a sustained negative impact on the long-term quality of life of affected women [2].

In women who underwent primary surgery with no suspicion of axillary lymph node involvement, the use of ALND for staging has been replaced by sentinel lymph node excision (SLNE), which has a lower morbidity without compromising disease-free survival (DFS) or overall survival (OS) (NSABP B 32 [3]).

In women with a clinically normal lymph node status and limited SLN involvement, randomised studies showed that in certain cases it is possible to avoid ALND (ACOSOG Z0011, AMAROS) [4, 5]. According to the updated recommendations of the AGO Breast Committee, the German S3 guideline (registry number 032–0450L), and the NCCN and ESMO guidelines, ALND can be avoided in selected patients with 1–2 affected lymph nodes [6–9].

► **Table 1** Oxford Levels of Evidence (LoE).

LOE	Therapy/prevention, aetiology/harm	Prognosis
1a	Systematic review (with homogeneity) of randomised controlled trials	Systematic review (with homogeneity) of inception cohort studies; clinical decision rule validated in different populations
1b	Individual randomised controlled trials (with narrow confidence interval)	Individual inception cohort study with ≥ 80% follow-up; clinical decision rule validated in a single population
1c	All or none	All or none case-series
2a	Systematic review (with homogeneity) of cohort studies	Systematic review (with homogeneity) of either retrospective cohort studies or untreated control groups in randomised controlled trials
2b	Individual cohort study (including low quality randomised controlled trials; e.g., < 80% follow-up)	Retrospective cohort study or follow-up of untreated control patients in a randomised controlled trial; derivation of clinical decision rule or validated on split-sample only
2c	“Outcomes” research; ecological studies	“Outcomes” research
3a	Systematic review (with homogeneity) of case-control studies	
3b	Individual case-control study	
4	Case series (and poor-quality cohort and case-control studies)	Case series (and poor-quality prognostic cohort studies)
5	Expert opinion without explicit critical appraisal, or based on physiology, bench research or “first principles”	Expert opinion without explicit critical appraisal, or based on physiology, bench research or “first principles”

► **Table 2** Oxford Grades of Recommendation (GR).

A	Consistent level 1 studies
B	Consistent level 2 or 3 studies or extrapolations from level 1 studies
C	Level 4 studies or extrapolations from level 2 or 3 studies
D	Level 5 evidence or troublingly inconsistent or inconclusive studies of any level

► **Table 3** AGO Levels of Recommendation.

++	This examination or therapeutic intervention is of great benefit to the patient, can be <b>unreservedly recommended</b> and should be carried out.
+	This examination or therapeutic intervention is of limited benefit to the patient and <b>may be carried out</b> .
+/-	This examination or therapeutic intervention has not shown any benefits to date and may be <b>carried out in individual cases</b> . It is not possible to give a clear recommendation based on the current data.
-	This examination or therapeutic intervention may be detrimental to the patient and should <b>rather not be carried out</b> .
--	This examination or therapeutic intervention is detrimental and should be <b>avoided or omitted in all cases</b> .

## Surgical Management of the Axilla After Neoadjuvant Chemotherapy

### Sentinel lymphadenectomy and axillary dissection

When SLNE became the standard procedure, the aim was to combine the smallest possible surgical intervention with a precise diagnostic workup and the lowest side effect profile. Although the data on SLNE performed during primary surgery showed good results, for a long time the feasibility and safety of SLNE after neoadjuvant chemotherapy was considered to be controversial, particularly in cases with a positive axillary lymph node status before the start of therapy and conversion to clinically undetectable lymph node involvement after NACT (cN+ → ycN0 stage). Two large prospective multicentre studies reported a false-negative rate (FNR) of 12% and 14% respectively for this patient population, although the FNR decreased when increasing numbers of lymph nodes were removed [10, 11]. This figure exceeds the generally accepted (but arbitrarily selected) cut-off value of 10%. However, the clinical impact of an FNR of > 10% on oncological endpoints (DFS, OS) is still unclear. For this reason, numerous national guidelines still recommend carrying out ALND in this patient population [5, 6].

### Targeted axillary dissection (TAD)

In recent years, the question of how the FNR can be improved in patients with primary lymph node involvement (cN+) has been intensively discussed. In 2016, Caudle et al. published a report of a new procedure, TAD (targeted axillary dissection), in which both the SLN and one (or even several) lymph node(s) found to be affected prior to treatment are dissected after being marked with a clip before the start of therapy [12]. The initially biopsied and investigated lymph node is marked and is referred to as the target lymph node (TLN). When TAD (SLNE + TLNE) was used, the FNR was only 2.0% (95% CI: 0.05–10.7; p = 0.13), a figure that was significantly superior to a FNR of 10.1% with SLNE and a FNR of 4.2% when only the target lymph node was resected. These retrospectively evaluated data from a prospective database support the hypothesis that TAD could be a suitable procedure to improve the limited success rate of SLNE and additionally reduce the morbidity associated with ALND using a gentler form of surgery. A number of validation studies have been published in recent years which address the question of whether target lymph nodes need to be marked and which method should be used to mark them to ensure a reliably low FNR for TAD procedures. The studies did not just investigate the reproducibility of TAD, they also examined the clinical benefit of different marking techniques (carbon dye, clip, radioactive seed) [13, 14] (► **Table 4**)

In the report on the SENTA trial by Kümmel et al., the detection rate for the target lymph node was 77.3% and the FNR for TAD was 4.3% (95% CI: 0.5–14.8) [15]. In the RISAS trial, the reported FNR was 3.47% (95% CI: 1.38–7.16) with a relatively small confidence interval, and the detection rate was 98% [16, 17]. In contrast, Hartmann et al. reported a lower detection rate of 93.6% and a higher FNR of 9.1% for the TATTOO trial [18].

None of the above-mentioned studies collected data on oncological endpoints such as disease-free survival and overall survival, quality of life, or effort and expense, so that it still remains unclear to what extent the different FNRs of the various methods affect the clinical outcome. Recommendations on TAD are therefore based on the reported FNRs and their perceived clinical relevance. The continuous improvement of local therapies and the use of individualised systemic therapy have led to continuously increasing rates of complete histopathological remission (pCR). In some groups, the rate may be as high as 70% [19]. Even in women with an initially positive lymph node status, the lymph node conversion rate may be as high as 50% [11, 20]. This means that the percentage of patients who have a negative node status (ypN0) after NACT and are then overtreated by undergoing ALND is continually increasing. For this reason, limiting the extent of radical surgery required to determine node status is a matter of urgency, especially as the removal of clinically unremarkable axillary lymph nodes is increasingly viewed as being done for the purposes of staging alone.

According to verified data on the reduction of surgical radicality, the data on the long-term oncological outcome of minimally-invasive staging methods (SLNE, TAD) after conversion from cN1 to ycN0 has not yet been validated. For this reason, various surgical axillary procedures (ALND, TAD, SLNE, TLNE) are still carried out after NACT in Europe and worldwide (based on the assess-

► **Table 4** Trials evaluating different marking techniques.

Study	Country	Marking technique	Case numbers (n)	Detection rate	FNR
SENTA [15] (NCT 03012307)	D	clip placement	473	77.3%	4.30% (95% CI: 0.5–14.8)
RISAS [16, 17] (NCT 02800317)	NL	radioactive seed placement	227	98.0%	3.47% (95% CI: 1.38–7.16)
TATTOO [18] (DRKS 00013169)	D, S	dye (carbon tattooing)	110	93.6%	9.10%

► **Table 5** Surgical axillary interventions and NACT.

						Oxford		
						LoE	GR	AGO
SLNE after NACT						2b	B	++
SLNE before NACT						2b	B	–
cN status (before NACT)	pN status (before NACT)	cN status (after NACT)	Surgical axillary intervention (after NACT)	pN status (after NACT and surgery)	Surgical consequences of histological findings			
cN0	–	ycN0	SLNE alone	ypN0 (sn)	–	2b	B	++***
				ypN0 (i+) ypN1 <sub>mic</sub> (sn)	ALND	2b	C	+ (+/– with i+)
					none**	5	D	+/–
				ypN1 (sn)	ALND	2b	C	++
				none**	5	D	+/–	
cN+	pN <sup>+</sup> <sub>CNB</sub>	ycN0	SLNE alone*	ypN0	–	2b	B	+/-***
			TAD (TLNE + SLNE)*	ypN0		2b	B	***
			ALND*	ypN0		2b	B	***
			SLNE alone*	ypN+ incl. ypN0 (i+)	ALND	2b	B	+ (+/– with i+)
			TAD (TLNE + SLNE)*					
ALND	ypN+	–	2b	B	++			
none	n. d.	none**	5	D	–			
cN+	pN <sup>+</sup> <sub>CNB</sub>	ycN+	ALND	ypN+ incl. ypN0 (i+)	–	2b	B	++
			None	n. d.	none**	5	D	–

\* Participation in AXSANA trial recommended; \*\* only radiotherapy for ypN1 (sn), ypN+ not recommended; \*\*\* recommendation grade is referred to staging for cN0 and cN+ ypN0.

ment of the respective national professional societies and surgeons).

### Recommendation of the AGO Breast Committee to reduce the rate of false negatives during the surgical staging of biopsy-confirmed axillary lymph node metastasis (pN<sup>+</sup><sub>CNB</sub>) before NACT and ycN0

Using currently available data [21–60], the AGO has evaluated the following procedures to reduce false negative rates during the surgical staging of cases who are pN<sup>+</sup><sub>CNB</sub> before NACT and ycN0 after NACT with AGO + (► **Fig. 1**):

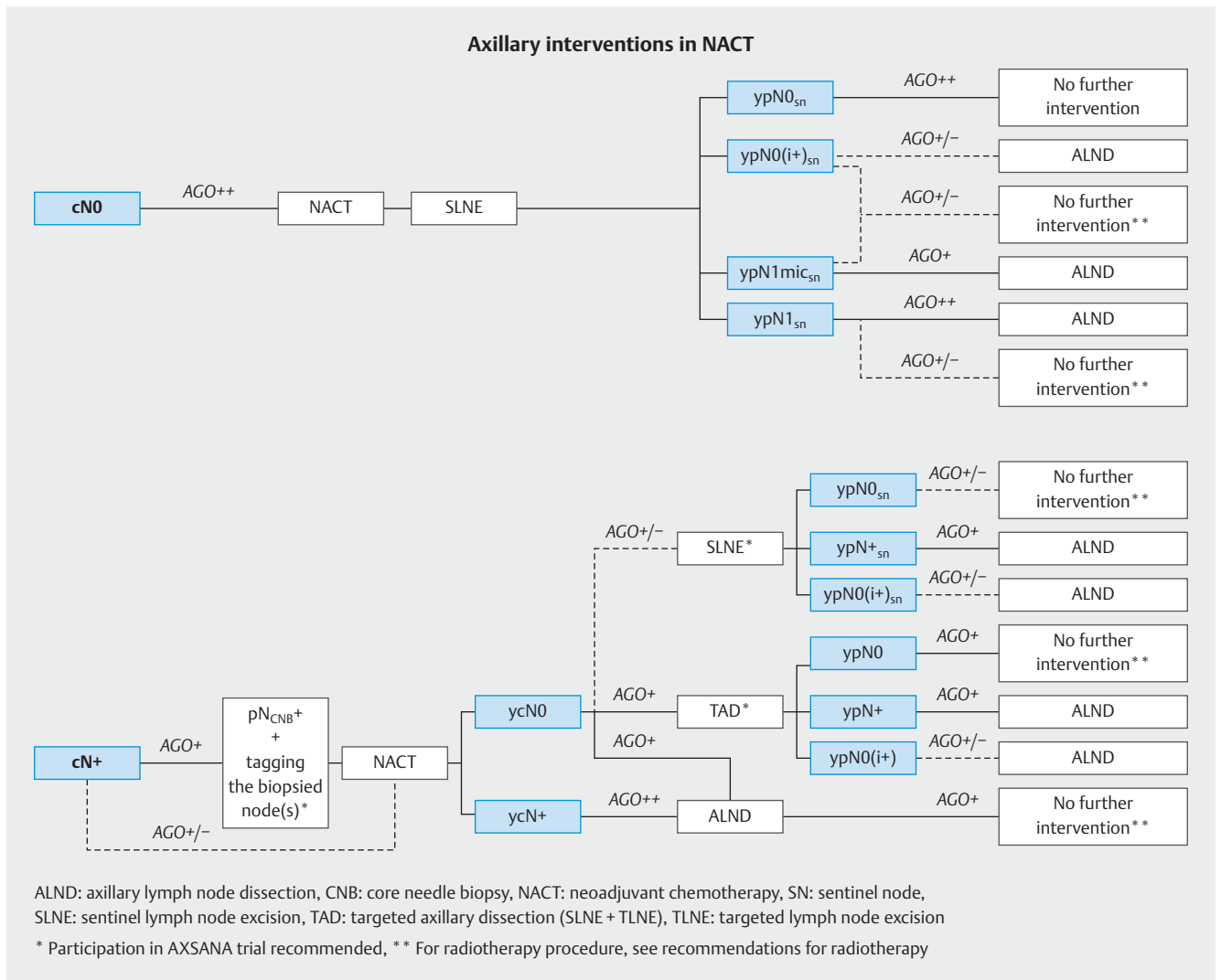
- Targeted axillary dissection (TAD) (LoE 2b, GR: B, AGO +)
- Dissection of > 2 SLNs (SLNE, no untargeted axillary sampling) (LoE 2a, GR: B, AGO +)
- Immunohistochemical evaluation to detect isolated tumour cells or micro-metastasis (LoE 2b, GR: B, AGO +)

In principle, the AGO classified performing SLNE before neoadjuvant chemotherapy as a minus (LoE 2b, GR: B, AGO –), which means it is no longer recommended (► **Table 5**). The prime reason for this is that pCR assessment is no longer possible when SLNE is performed prior to NACT, and the patient is additionally subjected to an unnecessary surgical procedure.

In contrast, carrying out axillary staging after systemic NACT therapy is recommended.

In this case, it is important to differentiate between two baseline situations (► **Fig. 1** and **Table 5**):

1. Patients who are node-negative on clinical and ultrasound examination before NACT
2. Patients who are node-positive on clinical and ultrasound examination before NACT



► **Fig. 1** Algorithm of axillary surgical procedures before and after NACT. [rerif]

### Patients who are node-negative on clinical and ultrasound examination before NACT

In clinically node-negative patients, SLNE should be carried out after neoadjuvant chemotherapy. If the histomorphological findings for SLN are normal, i.e., ypN0(sn), then no further axillary procedures are necessary.

If **macro-metastasis** is present in the SLN after NACT, then axillary dissection is indicated and classified as ++ (LOE 2b, GR: C, AGO +).

If **micro-metastasis** is present in the SLN after NACT, then ALND is an option and is classified as + (LOE 2b, GR: C, AGO +), as additional LN metastases outside the SLN tend to be present in this setting in around 60% of cases [45].

If **isolated tumour cells** are detected in SLN after NACT, the AGO classifies ALND as +/- (LOE 2b, GR: C, AGO +/-) and ALND may be considered in selected cases. Based on the currently available data, additional LN metastases may be present in around 17% of cases [45].

### Patients who are node-positive on clinical and ultrasound examination before NACT

If there is a primary suspicion of axillary lymph node involvement, a punch biopsy (pN<sub>CNB</sub>) carried out prior to NACT for histopathological verification is recommended, with marking of the suspicious axillary lymph node (LOE 2b, GR: B, AGO +) to permit TAD after NACT.

If the axilla are normal on clinical and ultrasound examination after NACT (ycN0), ALND and TAD are considered to be equivalent treatment options (LOE 2b, GR: B, AGO +), although TAD is a less invasive procedure with a low false-negative rate [12]. Lymph nodes which are found to be histomorphologically normal with TAD (ypN0) require no further surgical axillary intervention. Therapeutic ALND is recommended in cases with histologically verified lymph node involvement after TAD (ypN1), and the AGO classifies this as + (LOE 2b, GR: B, AGO +). ALND may be considered in selected cases with evidence of isolated tumour cells in LNs after TAD (ypN0(i+)); the AGO classifies this as +/- (LOE 2b, GR: B, AGO +/-).



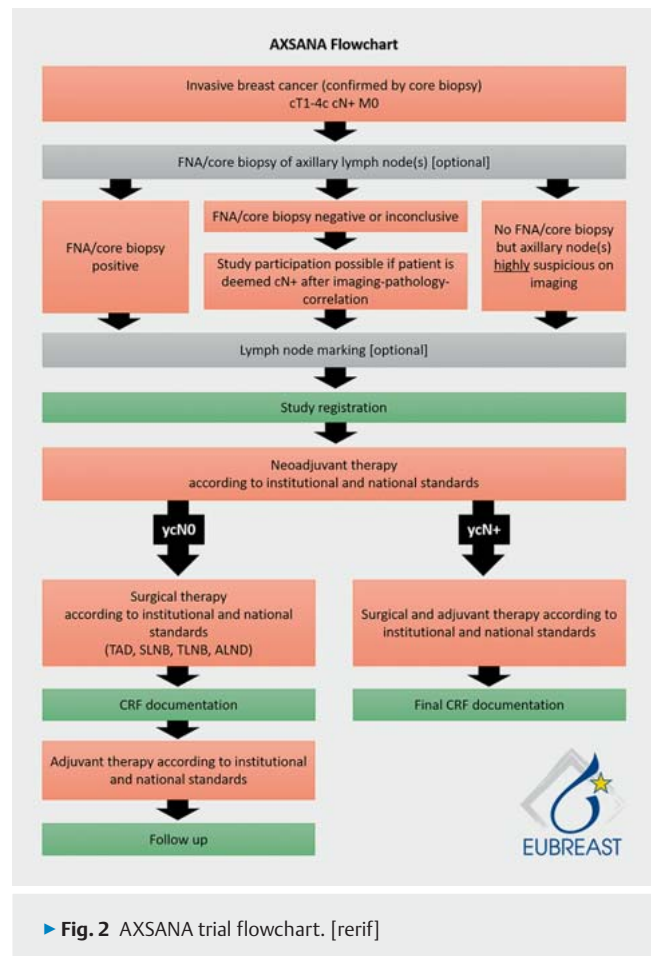
ALND is indicated in cases with axillary involvement (ycN+) detected on clinical or ultrasound examination (LOE 2b, GR: B, AGO ++). Further axillary procedures such as radiotherapy of the operated area are not indicated after complete ALND.

Because of its high false-negative rate of almost 17%, caution should be used with regard to SLNE alone after NACT in cases with conversion from cN+ → ycN0 [45]. The AGO therefore classifies this option as +/- (LOE 2b, GR: B, AGO +/-).

A lot of questions with regard to currently used surgical procedures still remain unsolved. Because of the lack of data, recommendations for patient populations which are ycN0 after NACT [conversion from pN+<sub>CNB</sub> (after punch biopsy)] vary greatly across the world. The current ESMO guideline permits SLNE alone; if the findings are negative, no further lymph nodes need to be removed in selected cases. However, the ESMO guideline emphasises that the FNR of SLNE alone can be improved by marking the lymph nodes which were positive on the initial biopsy, followed by targeted dissection. The guideline recommendations in Germany also vary. After its last revision in 02/2020, the S3 guideline still recommends ALND as the preferred procedure for primary node-positive patients after NACT. In contrast, the AGO amended its recommendations in 2019 to the effect that it now classes TAD an equivalent procedure. However, ALND is still the only accepted standard procedure in a number of European countries, (Sweden, Norway, Finland). In other countries (Italy), SLNE is carried out as a routine procedure without additional marking of a TLN. The American NCCN guidelines recommend carrying out TAD as an optional procedure. A prospective comparison of the different techniques with regard to their feasibility, safety, morbidity and surgical cost is urgently required. Because of the complexity and costs involved and the very different guideline recommendations, carrying out a randomised comparison would not be useful to generate the necessary data which could resolve the many outstanding issues within a short space of time.

The therapeutic axillary approach in cases where the initial node status on clinical examination is normal but lymph node metastasis is detected following histopathological examination after NACT (cN0 → ycN0 → ypN1) is not yet been investigated much, meaning that ALND continues to be the standard recommended approach in most guidelines. Although the AMAROS trial proved that radiotherapy was equivalent to ALND in patients with a clinically occult nodal status who underwent primary surgery and the ACOSOG Z0011 trial has shown that axillary interventions can successfully be dispensed with in patients with positive SLNs, it is not clear whether these data can be transferred to cases with chemotherapy-resistant lymph node involvement (after NACT) [4, 5]. The Alliance A011202 trial should provide important answers to this question [60].

There is even less evidence available on the appropriate approach for small metastases (micro-metastasis, isolated tumour cells) after NACT (ypN1mi or ypN0i+). Although minimal lymph node involvement in patients who underwent primary surgery has no impact on adjuvant therapy planning, it is not clear whether ALND might be necessary for diagnostic purposes (because of the high rate of downstream non-SLNs which might lead to an upgrade of patients' nodal status) or for therapeutic reasons (tumour cells resistant to systemic therapy) in cases with limited lymph node involvement after NACT.



► Fig. 2 AXSANA trial flowchart. [rerif]

Innovative methods have reduced the radicality of axillary surgery, but this reduced radicality should always be considered in the context of other therapeutic modalities. Even though studies have demonstrated the local efficacy of radiotherapy, with much of the data extrapolated from the adjuvant setting, carrying out the smallest possible axillary intervention and avoiding ALND should not be used as a justification for expanding radiotherapy measures, which have their own specific side effect profile.

Prospective studies are urgently required to close the existing knowledge gaps. The AXSANA/EUBREAST-0 3 trial (► Fig. 2), which is supported by the AGO-B, is an international project which currently includes 20 participating countries. The aim is to investigate the impact of different axillary staging measures on invasive disease-free survival, axillary rate of recurrence and quality of life [13]. The trial will also be analysing different therapeutic procedures in patients with ypN1 status and studying the importance of micro-metastasis and isolated tumour cells after NACT.

### Conflict of Interest

PD DR Banya-Paluchowski: Honoraria for lectures and advisory role from Lilly, Pfizer, Roche, Amgen, Eisai, Astra Zeneca, Daiichi Sankyo, Novartis, GSK and study support from Endomag, Merit Medical and Mammotome. Prof. Dr. V. Müller: VM received speaker honoraria from Amgen, Astra Zeneca, Daiichi Sankyo, Eisai, GSK, Pfizer, MSD, Novartis, Roche, Teva, Seagen and consultancy honoraria from Genomic Health, Hexal, Roche,

Pierre Fabre, Amgen, ClinSol, Novartis, MSD, Daiichi Sankyo, Eisai, Lilly, Seagen. Institutional research support from Novartis, Roche, Seagen, Genentech. Travel grants: Roche, Pfizer, Daiichi Sankyo.

## References

- [1] Ditsch N, Kolberg-Liedtke C, Friedrich M et al. AGO Recommendations for the Diagnosis and Treatment of Patients with Early Breast Cancer: Update 2021. *Breast Care (Basel)* 2021; 16: 214–227. doi:10.1159/000516419
- [2] Kühn T, Klauss W, Darsow M et al. Long-term morbidity following axillary dissection in breast cancer patients – clinical assessment, significance for life quality and the impact of demographic, oncologic and therapeutic factors. *Breast Cancer Res Treat* 2000; 64: 275–286
- [3] Krag DN, Anderson SJ, Julian TB et al. Sentinel-lymph-node resection compared with conventional axillary-lymph-node dissection in clinically node-negative patients with breast cancer: overall survival findings from the NSABP B-32 randomised phase 3 trial. *Lancet Oncol* 2010; 11: 927–933
- [4] Giuliano AE, Ballman KV, McCall L et al. Effect of Axillary Dissection vs. No Axillary Dissection on 10-Year Overall Survival Among Women With Invasive Breast Cancer and Sentinel Node Metastasis: The ACOSOG Z0011 (Alliance) Randomized Clinical Trial. *JAMA* 2017; 318: 918–926
- [5] Donker M, van Tienhoven G, Straver ME et al. Radiotherapy or surgery of the axilla after a positive sentinel node in breast cancer (EORTC 10981–22023 AMAROS): a randomised, multicentre, open-label, phase 3 non-inferiority trial. *Lancet Oncol* 2014; 15: 1303–1310
- [6] Ditsch N, Untch M, Kolberg-Liedtke C et al. AGO Recommendations for the Diagnosis and Treatment of Patients with Locally Advanced and Metastatic Breast Cancer: Update 2020. *Breast Care (Basel)* 2020; 15: 294–309. doi:10.1159/000508736
- [7] Leitlinienprogramm Onkologie (Deutsche Krebsgesellschaft, Deutsche Krebshilfe, AWMF). S3-Leitlinie Früherkennung, Diagnose, Therapie und Nachsorge des Mammakarzinoms, Version 4.3, 2020 AWMF Registernummer: 032–0450L. Accessed April 04, 2021 at: <http://www.leitlinienprogramm-onkologie.de/leitlinien/mammakarzinom/>
- [8] NCCN. National Comprehensive Cancer Network Clinical Practice Guidelines in Oncology (NCCN Guidelines®) Breast Cancer, Version 3.2021 – March 29, 2021. Accessed April 04, 2021 at: <https://www.nccn.org/guidelines/guidelines-detail?category=1&id=1419>
- [9] Cardoso F, Kyriakides S, Ohno S et al. Early breast cancer: ESMO Clinical Practice Guidelines for diagnosis, treatment and follow-up. *Ann Oncol* 2019; 30: 1194–1220. doi:10.1093/annonc/mdz173
- [10] Boughey J, Suman V, Mittendorf E et al. Sentinel lymph node surgery after neoadjuvant chemotherapy in patients with node-positive breast cancer: the ACOSOG Z1071 (Alliance) clinical trial. *JAMA* 2013; 310: 1455–1461
- [11] Kuehn T, Bauerfeind I, Fehm T et al. Sentinel-node biopsy in patients with breast cancer before and after neoadjuvant chemotherapy (SENTINA): a prospective, multicenter cohort study. *Lancet Oncol* 2013; 14: 609–618
- [12] Caudle AS, Wang WT, Krishnamurthy S et al. Improved Axillary Evaluation after Neoadjuvant Chemotherapy for Patients with Node-Positive Breast Cancer using Selective Evaluation of Clipped Nodes: Implementation of Targeted Axillary Dissection. *J Clin Oncol* 2016; 34: 1072–1078
- [13] Banys-Paluchowski M, Gasparri ML, Boniface J et al. Surgical Management of the Axilla in Clinically Node-Positive Breast Cancer Patients Converting to Clinical Node Negativity through Neoadjuvant Chemotherapy: Current Status, Knowledge Gaps, and Rationale for the EUBREAST-03. *Cancers* 2021; 13: 1565. doi:10.3390/cancers13071565
- [14] Banys-Paluchowski M, Gruber IV, Hartkopf A et al. Axillary ultrasound for prediction of response to neoadjuvant therapy in the context of surgical strategies to axillary dissection in primary breast cancer: a systematic review of the current literature. *Arch Gyn Obstet* 2020; 301: 341–353. doi:10.1007/s00404-019-05428-x
- [15] Kümmel S, Heil J, Rueland A et al. Prospective, Multicenter Registry Study to Evaluate the Clinical Feasibility of Targeted Axillary Dissection (TAD) in Node-Positive Breast Cancer Patients. *Ann Surg* 2020. doi:10.1097/SLA.0000000000004572
- [16] van Nijnatten TJA, Simons JM, Smidt ML et al. A Novel Less-invasive Approach for Axillary Staging After Neoadjuvant Chemotherapy in Patients With Axillary Node-positive Breast Cancer by Combining Radioactive Iodine Seed Localization in the Axilla With the Sentinel Node Procedure (RISAS): A Dutch Prospective Multicenter Validation Study. *Clin Breast Cancer* 2017; 17: 399–402. doi:10.1016/j.clbc.2017.04.006
- [17] Simons J, Nijnatten TJV, Koppert LB et al. Radioactive Iodine Seed placement in the Axilla with Sentinel lymph node biopsy after neoadjuvant chemotherapy in breast cancer: Results of the prospective multicenter RISAS trial. *Gen Sess Abstr* 2021; 81: GS1-10
- [18] Hartmann S, Kühn T, de Boniface J et al. Carbon tattooing for targeted lymph node biopsy after primary systemic therapy in breast cancer: prospective multicentre TATTOO trial. *Br J Surg* 2021. doi:10.1093/bjs/znaa083
- [19] Untch M, Jackisch C, Schneeweiss A et al. NAB – Paclitaxel Improves Disease Free Survival in Early Breast Cancer: GBG 69 – GeparSepto. *J Clin Oncol* 2019. doi:10.1200/JCO.18.01842
- [20] Boughey J, McCall L, Ballman K et al. Tumor biology correlates with rates of breast-conserving surgery and pathologic complete response after neoadjuvant chemotherapy for breast cancer: findings from ACOSOG Z1071 (Alliance) Prospective Multicenter Clinical Trial. *Ann Surg* 2014; 260: 608–614
- [21] Wong SM, Weiss A, Mittendorf EA et al. Surgical Management of the Axilla in Clinically Node-Positive Patients Receiving Neoadjuvant Chemotherapy: A National Cancer Database Analysis. *Ann Surg Oncol* 2019. doi:10.1245/s10434-019-07583
- [22] Hartmann S, Reimer T, Gerber B et al. Wire localization of clip-marked axillary lymph nodes in breast cancer patients treated with primary systemic treatment. *Eur J Surg Oncol* 2018; 34: 1072–1078
- [23] Siso C, de Torres J, Esgueva-Colmenarejo A et al. Intraoperative Ultrasound-Guided Excision of Axillary Clip in Patients with Node-Positive Breast Cancer Treated with Neoadjuvant Therapy (ILINA Trial): A New Tool to Guide the Excision of the Clipped Node After Neoadjuvant Treatment. *Ann Surg Oncol* 2018; 25: 784–791
- [24] Hanna TP, King WD, Thibodeau S et al. Mortality due to cancer treatment delay: systematic review and meta-analysis. *BMJ* 2020; 371: m4087
- [25] Cone EB, Marchese M, Paciotti M et al. Assessment of Time-to-Treatment Initiation and Survival in a Cohort of Patients With Common Cancers. *JAMA Netw Open* 2020; 3: e2030072. doi:10.1001/jamanetworkopen.2020.30072
- [26] Reimer T, Gerber B. Quality-of-life considerations in the treatment of early-stage breast cancer in the elderly. *Drugs Aging* 2010; 27: 791–800
- [27] Tuttle TM, Shamliyan T, Virnig BA et al. The impact of sentinel lymph node biopsy and magnetic resonance imaging on important outcomes among patients with ductal carcinoma in situ. *J Natl Cancer Inst Monogr* 2010; 2010: 117–120
- [28] Gerber B, Heintze K, Stubert J et al. Axillary lymph node dissection in early-stage invasive breast cancer: is it still standard today? *Breast Cancer Res Treat* 2011; 128: 613–624
- [29] D’Angelo-Donovan DD, Dickson-Witmer D, Petrelli NJ. Sentinel lymph node biopsy in breast cancer: A history and current clinical recommendations. *Surg Oncol* 2012; 21: 196–200
- [30] Galimberti V, Cole BF, Zurrada S et al. International Breast Cancer Study Group Trial 23-01 investigators. Axillary dissection versus no axillary dissection in patients with sentinel-node micrometastases (IBCSG 23-01): a phase 3 randomised controlled trial. *Lancet Oncol* 2013; 14: 297–305
- [31] Giuliano AE, Ballman KV, McCall L et al. Effect of Axillary Dissection vs. No Axillary Dissection on 10-Year Overall Survival Among Women With Invasive Breast Cancer and Sentinel Node Metastasis: The ACOSOG Z0011 (Alliance) Randomized Clinical Trial. *JAMA* 2017; 318: 918–926



- [32] Fu JF, Chen HL, Yang J et al. Feasibility and accuracy of sentinel lymph node biopsy in clinically node-positive breast cancer after neoadjuvant chemotherapy: a meta-analysis. *PLoS One* 2014; 9: e105316
- [33] Lee HD, Ahn SG, Lee SA et al. Prospective Evaluation of the Feasibility of Sentinel Lymph Node Biopsy in Breast Cancer Patients with Negative Axillary Conversion after Neoadjuvant Chemotherapy. *Cancer Res Treat* 2014. doi:10.4143/crt.2013.208
- [34] Boileau JF, Poirier B, Basik M et al. Sentinel Node Biopsy After Neoadjuvant Chemotherapy in Biopsy-Proven Node-Positive Breast Cancer: The SN FNAC Study. *J Clin Oncol* 2015; 33: 258–264
- [35] Boughey JC, Ballman KV, Le-Petross HT et al. Identification and Resection of Clipped Node Decreases the False-negative Rate of Sentinel Lymph Node Surgery in Patients Presenting With Node-positive Breast Cancer (T0–T4, N1–N2) Who Receive Neoadjuvant Chemotherapy: Results From ACOSOG Z1071 (Alliance). *Ann Surg* 2016; 263: 802–807
- [36] Ryu JM, Lee SK, Kim JY et al. Predictive Factors for Nonsentinel Lymph Node Metastasis in Patients With Positive Sentinel Lymph Nodes After Neoadjuvant Chemotherapy: Nomogram for Predicting Nonsentinel Lymph Node Metastasis. *Clin Breast Cancer* 2017; 17: 550–555
- [37] Galimberti V, Ribeiro Fontana SK, Maisonneuve P. Sentinel node biopsy after neoadjuvant treatment in breast cancer: five-year follow-up of patients with clinically node-negative or node-positive disease before treatment. *Eur J Surg Oncol* 2016; 42: 361–368
- [38] Martelli G, Miceli R, Folli S et al. Sentinel node biopsy after primary chemotherapy in cT2 N0/1 breast cancer patients: Long-term results of a retrospective study. *Eur J Surg Oncol* 2017; 43: 2012–2020
- [39] Palmer JAV, Flippo-Morton T, Walsh KK et al. Application of ACOSOG Z1071: Effect of Results on Patient Care and Surgical Decision-Making. *Clin Breast Cancer* 2018; 18: 270–275. doi:10.1016/j.clbc.2017.10.006
- [40] Fernandez-Gonzalez S, Falo C, Pla MJ et al. The Shift From Sentinel Lymph Node Biopsy Performed Either Before or After Neoadjuvant Systemic Therapy in the Clinical Negative Nodes of Breast Cancer Patients. Results, and the Advantages and Disadvantages of Both Procedures. *Clin Breast Cancer* 2018; 18: 71–77. doi:10.1016/j.clbc.2017.08.014
- [41] Kahler-Ribeiro-Fontana S, Pagan E, Magnoni F et al. Long-term standard sentinel node biopsy after neoadjuvant treatment in breast cancer: a single institution ten-year follow-up. *Eur J Surg Oncol* 2021; 47: 804–812
- [42] Tee SR, Devane LA, Evoy D et al. Meta-analysis of sentinel lymph node biopsy after neoadjuvant chemotherapy in patients with initial biopsy-proven node-positive breast cancer. *Br J Surg* 2018; 105: 1541–1552
- [43] Balic M, Thomssen C, Würstlein R et al. St. Gallen/Vienna 2019: A Brief Summary of the Consensus Discussion on the Optimal Primary Breast Cancer Treatment. *Breast Care (Basel)* 2019; 14: 103–110
- [44] Classe JM, Loaec C, Gimbergues P et al. Sentinel lymph node biopsy without axillary lymphadenectomy after neoadjuvant chemotherapy is accurate and safe for selected patients: the GANEA 2 study. *Breast Cancer Res Treat* 2019; 173: 343–352
- [45] Moo TA, Edelweiss M, Hajiyeva S et al. Is Low-Volume Disease in the Sentinel Node After Neoadjuvant Chemotherapy an Indication for Axillary Dissection? *Ann Surg Oncol* 2018; 25: 1488–1494. Erratum in: *Ann Surg Oncol* 2020; 27 (Suppl. 3): 966
- [46] Allweis TM, Menes T, Rotbart N et al. Ultrasound guided tattooing of axillary lymph nodes in breast cancer patients prior to neoadjuvant therapy, and identification of tattooed nodes at the time of surgery. *Eur J Surg Oncol* 2020; 46: 1041–1045. doi:10.1016/j.ejso.2019.11.501
- [47] Balasubramian R, Morgan C, Shaari E et al. Wire guided localisation for targeted axillary node dissection is accurate in axillary staging in node positive breast cancer following neoadjuvant chemotherapy. *Eur J Surg Oncol* 2020; 46: 1028–1033. doi:10.1016/j.ejso.2019.12.007
- [48] Coufal O, Zapletal O, Gabrielová L et al. Targeted axillary dissection and sentinel lymph node biopsy in breast cancer patients after neoadjuvant chemotherapy – a retrospective study. *Rozhl Chir Winter* 2018; 97: 551–557
- [49] Ditsch N, Rubio IT, Gasparri ML et al. Breast and axillary surgery in malignant breast disease: a review focused on literature of 2018 and 2019. *Curr Opin Obstet Gynecol* 2020; 32: 91–99
- [50] Flores-Funes D, Aguilar-Jiménez J, Martínez-Gálvez M et al. Validation of the targeted axillary dissection technique in the axillary staging of breast cancer after neoadjuvant therapy: Preliminary results. *Surg Oncol* 2019; 30: 52–57. doi:10.1016/j.suronc.2019.05.019
- [51] Gandhi A, Coles C, Makris A et al. Axillary Surgery Following Neoadjuvant Chemotherapy – Multidisciplinary Guidance From the Association of Breast Surgery, Faculty of Clinical Oncology of the Royal College of Radiologists, UK Breast Cancer Group, National Coordinating Committee for Breast Pathology and British Society of Breast Radiology. *Clin Oncol (R Coll Radiol)* 2019; 31: 664–668
- [52] García-Moreno JL, Benjumeda-Gonzalez AM, Amerigo-Góngora M et al. Targeted axillary dissection in breast cancer by marking lymph node metastasis with a magnetic seed before starting neoadjuvant treatment. *J Surg Case Rep* 2019; 2019: rjz344
- [53] Greenwood HI, Wong JM, Mukhtar RA et al. Feasibility of Magnetic Seeds for Preoperative Localization of Axillary Lymph Nodes in Breast Cancer Treatment. *AJR Am J Roentgenol* 2019; 213: 953–957
- [54] Hellingman D, Donswijk ML, Winter-Warnars GAO et al. Feasibility of radioguided occult lesion localization of clip-marked lymph nodes for tailored axillary treatment in breast cancer patients treated with neoadjuvant systemic therapy. *EJNMMI Res* 2019; 9: 94
- [55] Kanesalingam K, Sriram N, Heilat G et al. Targeted axillary dissection after neoadjuvant systemic therapy in patients with node-positive breast cancer. *ANZ J Surg* 2020; 90: 332–338. doi:10.1111/ans.15604
- [56] Natsiopoulou I, Intzes S, Liappis T et al. Axillary Lymph Node Tattooing and Targeted Axillary Dissection in Breast Cancer Patients Who Presented as cN+ Before Neoadjuvant Chemotherapy and Became cN0 After Treatment. *Clin Breast Cancer* 2019; 19: 208–215
- [57] Simons JM, van Nijnatten TJA, van der Pol CC et al. Diagnostic Accuracy of Different Surgical Procedures for Axillary Staging After Neoadjuvant Systemic Therapy in Node-positive Breast Cancer: A Systematic Review and Meta-analysis. *Ann Surg* 2019; 269: 432–442
- [58] Simons JM, van Pelt MLMA, Marinelli AWKS et al. Excision of both pre-treatment marked positive nodes and sentinel nodes improves axillary staging after neoadjuvant systemic therapy in breast cancer. *Br J Surg* 2019; 106: 1632–1639
- [59] Lee J, Jung JH, Kim WW et al. 5-year oncological outcomes of targeted axillary sampling in pT1-2N1 breast cancer. *Asian J Surg* 2019; 42: 681–687. doi:10.1016/j.asjsur.2018.10.004
- [60] National Cancer Institute. Comparison of axillary lymph node dissection with axillary radiation for patients with node-positive breast cancer related with chemotherapy. Accessed May 09, 2015 at: <http://www.cancer.gov/clinicaltrials/search/view?cdrid=751211&version=HealthProfessional>

### Correction

**AGO Recommendations for the Surgical Therapy of the Axilla After Neoadjuvant Chemotherapy: 2021 Update**  
Michael Friedrich, Thorsten Kühn, Wolfgang Janni et al.  
*Geburtsh Frauenheilk* 2021; 81(10): 1112–1120.  
doi:10.1055/a-1499-8431

In the above article, the name of the co-author was given incorrectly. Correct is: Maggie Banys-Paluchowski.