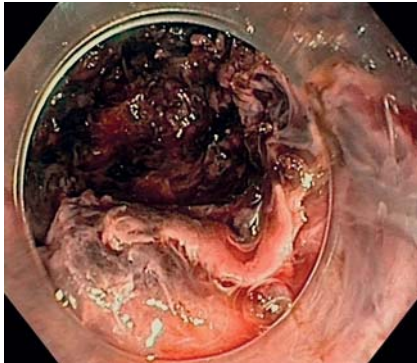
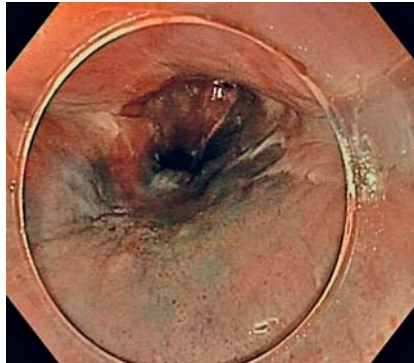


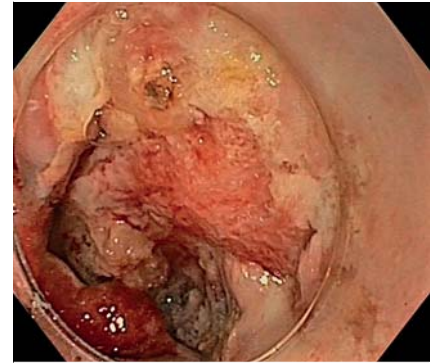Delayed bleeding and intratunnel hematoma after peroral endoscopic myotomy: salvage endoscopy management with full recovery



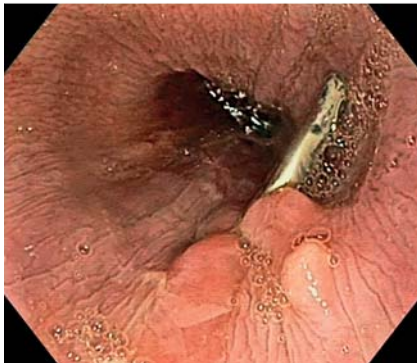► **Fig. 1** Interior of the tunnel after clot removal and coagulation of bleeding vessels.



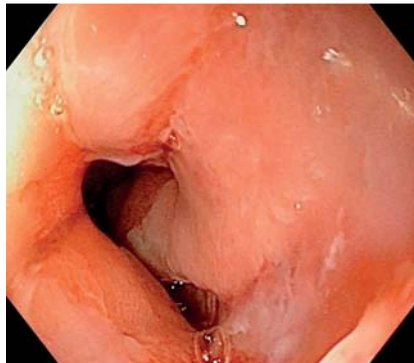► **Fig. 2** Blue color of the esophageal mucosa immediately after salvage endoscopy.



► **Fig. 3** An ulcer in the distal esophagus, secondary to ischemic phenomena.



► **Fig. 4** The middle esophagus 3 weeks after peroral endoscopic myotomy.



► **Fig. 5** Complete healing of the distal ulcer esophagus 2 weeks after its identification.

Peroral endoscopic myotomy (POEM) is a safe technique for achalasia management [1]. The rate of major complications is commonly <5% in the largest series [2–4]; delayed bleeding with intratunnel hematoma (<0.5%) is infrequently reported. Hematoma and local compression effects can induce ischemic phenomena with ulceration, as well as hemodynamic effects triggered by active bleeding. Symptoms begin within 24–48 hours, generally with hematemesis and progressive retrosternal pain after several hours of active bleeding. If suspected, urgent chest computed tomography (CT) can confirm the diagnosis [5]. This complica-

tion is not exclusively associated with anticoagulation therapy, thus, we need to be alert.

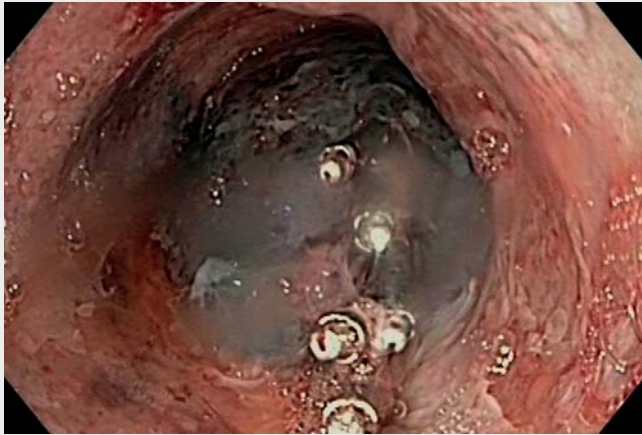Once confirmed, emergency endoscopy within 24–48 hours for mechanical removal of the intratunnel clot and local hemostasia is recommended. Typical findings include large clots covering the submucosa tunnel and blue color of the upper mucosa. Mucosotomy clips should be removed in order to enter the tunnel. Careful work is required to remove all clots (► **Fig. 1**) and expose active bleeding vessels with hemostatic forceps. Foreign-body forceps and polypectomy snare could be used to fragment and re-

move the clots. In cases of failure, a Sengstaken–Blakemore tube or covered stent could be placed; several reports have described their use regardless of the success of endoscopic removal of the intratunnel clots.

We present the case of a 76-year-old man who complained of hematemesis and retrosternal pain 16 hours after uneventful POEM for achalasia type II. CT chest showed a large hematoma 10 cm in length in the middle and lower esophagus with no signs of active bleeding. Salvage gastroscopy was performed following the steps described previously (► **Fig. 2**, ► **Video 1**).

After 1 week, the hematoma did not re-emerge, but ischemic phenomena appeared in the distal esophagus (► **Fig. 3**). Clips were placed to approximate the edges of the ulcer to aid mucosal healing. After 3 weeks on proton pump inhibitors and nil per os, endoscopy showed complete scarring of the mucosotomy and distal esophageal ulcer (► **Fig. 4**, ► **Fig. 5**), and the patient could resume a diet and was discharged. At 2 months after discharge, the patient had no symptoms with a normal diet.

Endoscopy_UCTN_Code_CPL_1AH_2AK



Video 1 Hematoma after peroral endoscopic myotomy: step-by-step resolution of a complication.

Bibliography

Endoscopy 2022; 54: 624–625
DOI 10.1055/a-1494-3233
ISSN 0013-726X
published online 18.6.2021
© 2021. Thieme. All rights reserved.
Georg Thieme Verlag KG, Rüdigerstraße 14,
70469 Stuttgart, Germany

ENDOSCOPY E-VIDEOS

<https://eref.thieme.de/e-videos>



Endoscopy E-Videos is an open access online section, reporting on interesting cases and new techniques in gastroenterological endoscopy. All papers include a high quality video and all contributions are freely accessible online. Processing charges apply (currently EUR 375), discounts and waivers acc. to HINARI are available.

This section has its own submission website at <https://mc.manuscriptcentral.com/e-videos>

Competing interests

The authors declare that they have no conflict of interest.

The authors

Ignacio Omella Usieto, José Santiago García, Diego de Frutos Rosa, Belen Agudo, Alberto Herreros-de-Tejada

Gastroenterology and Hepatology, Puerta de Hierro University Hospital of Majadahonda, Majadahonda, Spain

Corresponding author

Alberto Herreros-de-Tejada, MD, PhD
Gastroenterology, Puerta de Hierro University Hospital of Majadahonda, Manuel de Falla, Majadahonda 28222, Spain
a_herreros_tejada.phierro@yahoo.com

References

- [1] Inoue H, Minami H, Kobayashi Y et al. Peroral endoscopic myotomy (POEM) for esophageal achalasia. *Endoscopy* 2010; 42: 265–271
- [2] Li QL, Zhou PH, Yao LQ et al. Early diagnosis and management of delayed bleeding in the submucosal tunnel after peroral endoscopic myotomy for achalasia (with video). *Gastrointest Endosc* 2013; 78: 370–374
- [3] Zhang XC, Li QL, Zhou PH et al. Major perioperative adverse events of peroral endoscopic myotomy: a systematic 5-year analysis. *Endoscopy* 2016; 48: 967–978
- [4] Nabi Z, Reddy DN, Ramchandani M et al. Adverse events during and after per-oral endoscopic myotomy: prevention, diagnosis, and management. *Gastrointest Endosc* 2018; 87: 4–17
- [5] Cai MY, Zhou PH, Liang L et al. Thoracic CT after peroral endoscopic myotomy for the treatment of achalasia. *Gastrointest Endosc* 2014; 80: 1046–1055