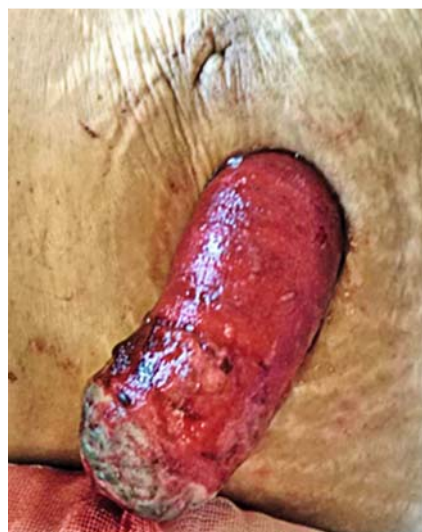

A novel balloon-attached endoscopy-assisted reduction technique for an acute strangulated stoma prolapse

Stoma prolapse is a common late complication that occurs in 2–26% of colostomies [1]. Prolapse is most frequently seen after loop colostomies [2] and often involves the distal limb [3]. Prolapsed stoma is rarely incarcerated or strangulated; however, such cases require emergency surgery [3, 4].



► Fig. 1 Stoma prolapse.

A 70-year-old woman suffering from obstructive rectal cancer with multiple liver and lung metastases underwent transverse loop colostomy and subsequent chemotherapy. On day 2 after initiation of second-line chemotherapy (infusional 5-FU, leucovorin, and irinotecan plus ramucirumab), the distal limb of loop colostomy was prolapsed and strangulated owing to edema. The prolapsed colon wall was entirely reddish and edematous with a superficial brown spot at the tip (► Fig. 1) and manual reduction using sugar as a desiccant was unsuccessful. Although emergency surgery is usually indicated in such circumstances, it is associated with perioperative complications due to administration of ramucirumab. Hence, we attempted a unique balloon-attached endoscopy-assisted reduction (► Fig. 2). An 11-mm balloon for endoscopic injection sclerotherapy (MD-47411L; Sumitomo Bakelite Co., Ltd., Tokyo, Japan) was attached to the shaft of the colonoscope (► Fig. 3), and it was inserted into the prolapsed stoma such that the balloon came in contact with the invaginated inside wall. To ensure

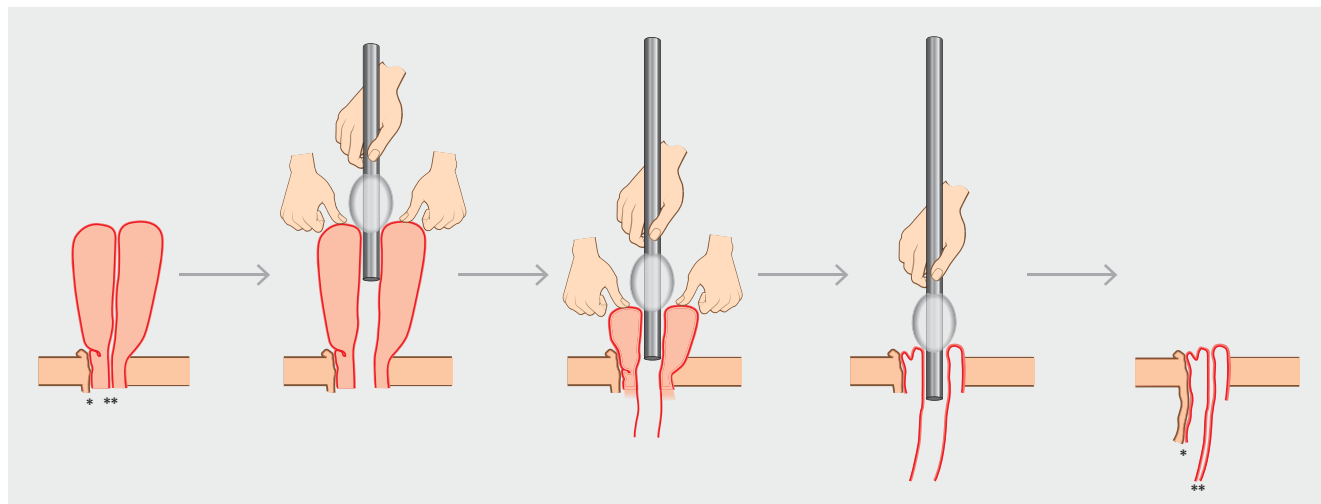
secure placement, the balloon diameter should be smaller than the outer diameter of the prolapsed tract but slightly larger than the inside diameter. The balloon was kept in contact with the prolapsed inside wall while the endoscope was gradually pushed forward, and simultaneously another operator facilitated repositioning of the inside wall with their hand. This procedure was slowly repeated until the prolapsed stoma had been successfully reduced (► Fig. 4). No recurrence was observed thereafter.

We describe a novel non-surgical “balloon-attached endoscopy-assisted reduction” approach that may be a useful conservative technique for reducing an incarcerated stoma prolapse (► Video 1).

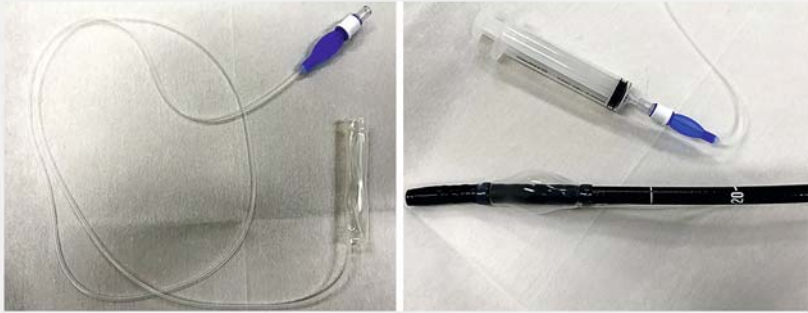
Endoscopy_UCTN_Code_TTT_1AT_2AF

Competing interests

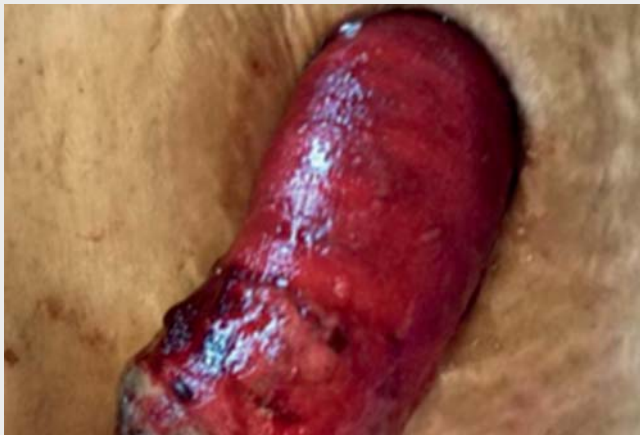The authors declare that they have no conflict of interest.



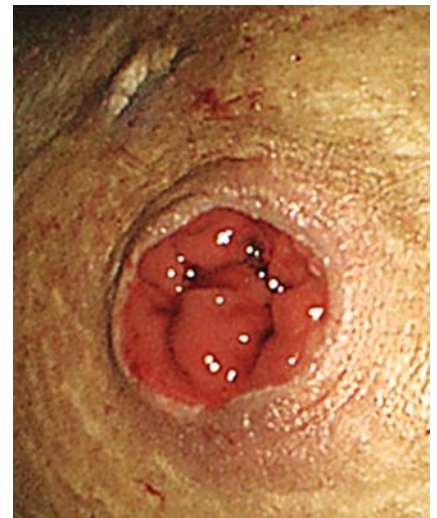► Fig. 2 Schema of balloon-attached endoscopy-assisted reduction (*proximal limb, **distal limb).



► **Fig. 3** Balloon-attached endoscopy. Balloon for endoscopic injection sclerotherapy was attached to the shaft of the colonoscope.



► **Video 1** Balloon-attached endoscopy-assisted reduction for strangulated stoma prolapse.



► **Fig. 4** Successful reduction of stoma prolapse.

Bibliography

Endoscopy 2022; 54: E36–E37
DOI 10.1055/a-1346-8427
ISSN 0013-726X
published online 19.2.2021
 © 2021. Thieme. All rights reserved.
 Georg Thieme Verlag KG, Rüdigerstraße 14,
 70469 Stuttgart, Germany

ENDOSCOPY E-VIDEOS

<https://eref.thieme.de/e-videos>



Endoscopy E-Videos is a free access online section, reporting on interesting cases and new techniques in gastroenterological endoscopy. All papers include a high quality video and all contributions are freely accessible online.

This section has its own submission website at
<https://mc.manuscriptcentral.com/e-videos>

The authors

Takaya Shimura¹, **Takanori Ozeki**¹, **Hajime Ushigome**², **Takahisa Hirokawa**², **Kazuyoshi Shiga**², **Hiroki Takahashi**², **Hiromi Kataoka**¹

- 1 Department of Gastroenterology and Metabolism, Nagoya City University Graduate School of Medical Sciences, Japan
- 2 Department of Gastroenterological Surgery, Nagoya City University Graduate School of Medical Sciences, Japan

Corresponding author

Takaya Shimura, MD, PhD
 Department of Gastroenterology and Metabolism, Nagoya City University Graduate School of Medical Sciences, 1 Kawasumi, Mizuho-cho, Mizuho-ku, Nagoya

467-8601, Japan
 Fax: +81-52-852-0952
 tshimura@med.nagoya-cu.ac.jp

References

- [1] Husain SG, Cataldo TE. Late stomal complications. *Clin Colon Rectal Surg* 2008; 21: 31–40
- [2] Jayarajah U, Samarasekera AM, Samarasekera DN. A study of long-term complications associated with enteral ostomy and their contributory factors. *BMC Res Notes* 2016; 9: 500
- [3] Krishnamurthy DM, Blatnik J, Mutch M. Stoma Complications. *Clin Colon Rectal Surg* 2017; 30: 193–200
- [4] Mittal R, Jalouta T, Luchtefeld M et al. Surgical management of stomal prolapse – Is there a superior approach to repair? *Am J Surg* 2020; 220: 1010–1014