

Water-filled technique for therapeutic pancreato-biliary EUS in patients with surgically altered anatomy




Authors

Benedetto Mangiavillano^{1,2}, Silvia Carrara³, Leonardo H. Eusebi⁴, Francesco Auriemma¹, Mario Bianchetti¹, Alessandro Repici^{2,3}

Institutions

- 1 Gastrointestinal Endoscopy Unit – Humanitas Mater Domini – Castellanza, Italy
- 2 Humanitas University, Rozzano, Italy
- 3 Digestive Endoscopy Unit, Humanitas Clinical and Research Center, Rozzano, Italy
- 4 Endoscopy Unit, Department of Medical and Surgical Sciences, Sant’Orsola University Hospital, Bologna, Italy

Castellanza (VA), Italy

Fax: +0039 0331 476210

bennymangiavillano@gmail.com

submitted 17.6.2020

accepted after revision 28.9.2020

Bibliography

Endoscopy International Open 2021; 09: E487–E489

DOI 10.1055/a-1339-0690

ISSN 2364-3722

© 2021. The Author(s).

This is an open access article published by Thieme under the terms of the Creative Commons Attribution-NonDerivative-NonCommercial License, permitting copying and reproduction so long as the original work is given appropriate credit. Contents may not be used for commercial purposes, or adapted, remixed, transformed or built upon. (<https://creativecommons.org/licenses/by-nc-nd/4.0/>)

Georg Thieme Verlag KG, Rüdigerstraße 14,
70469 Stuttgart, Germany

Corresponding author

Benedetto Mangiavillano, MD, Gastrointestinal Endoscopy Unit, Humanitas – Mater Domini, Via Gerenzano n.2, 21053 –

ABSTRACT

One of the main challenges encountered by endosonographers is performing diagnostic and interventional pancreato-biliary endoscopic ultrasound (EUS) procedures in the presence of surgically altered upper gastrointestinal anatomy. We describe the water-filled technique (WFT) for EUS examination and treatment of the pancreato-biliary region in patients with surgically altered upper gastrointestinal anatomy. Using the WFT, the scope is advanced up to the gastro-jejunal anastomosis and, after placing the tip of the scope 2 cm beyond it, enlargement of the jejunal lumen is obtained by water instillation of the jejunal loop. An enlargement of more than 1.5 cm allows advancement of the tip of the scope under EUS guidance up to the duodenum, in a retrograde way. The WFT is useful for reaching the ampullary area and performing diagnostic and therapeutic EUS in patients with surgically altered anatomy. The technique is also reproducible and can be easily used by endoscopists who regularly perform EUS.

Introduction

Pancreato-biliary malignancies represent the fourth most common cause of cancer-related deaths in Western countries, with a 6% 5-year survival for patients with pancreatic cancer [1]. To treat these patients and improve their survival and quality of life, there has been an increasing need for low-risk procedures to obtain an accurate histopathological diagnosis [2]. Endoscopic ultrasonography (EUS) is a well-established endoscopic technique, mainly performed for diagnosis and tissue acquisition (TA) for gastrointestinal and pancreato-biliary masses.

Currently, fine-needle aspiration (FNA) and fine-needle biopsy (FNB) are the standard methods for obtaining tissue

samples from pancreatic masses under EUS guidance, with a sensitivity, specificity, and diagnostic accuracy of 85% to 95%, 95% to 98%, and 78% to 95%, respectively [3]. In addition to its diagnostic use, in recent years, EUS has gained a pivotal role in the palliative management of patients with malignant biliary obstruction (MBO), especially when previous endoscopic retrograde cholangiopancreatography (ERCP) attempts have failed. The potential therapeutic role of EUS has increased with development of lumen-apposing metal stents (LAMS), allowing creation of an anastomosis between the common bile duct (CBD) or the gallbladder and the gastrointestinal lumen [4]. Moreover, several new devices have been developed in recent years for therapeutic EUS procedures, such as radiofrequency ablation

(RFA) catheters for treatment of advanced pancreatic cancers, neuroendocrine tumors (NET) or neoplastic recurrence in the lower gastrointestinal tract [5].

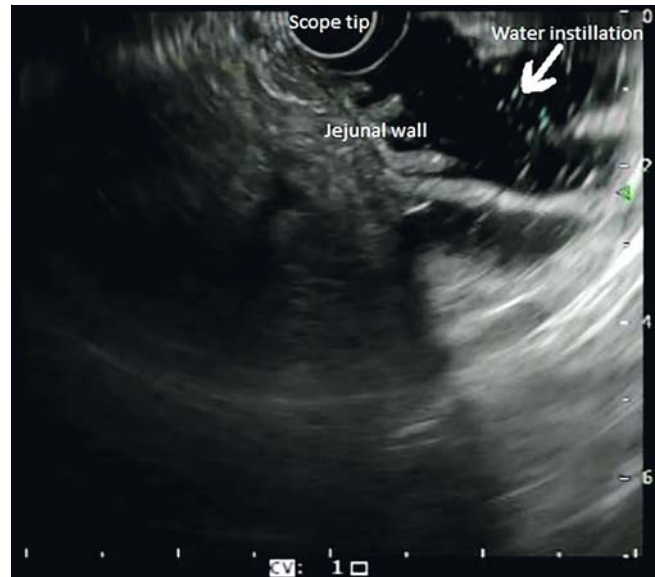
One of the main challenges encountered by endosonographers is performing diagnostic and interventional pancreatobiliary EUS, including tissue acquisition by FNA or FNB and palliative treatments, in the presence of surgically altered upper gastrointestinal anatomy. Indeed, pancreato-biliary endoscopic procedures, including EUS with or without FNA, are often difficult or even impossible in the presence of surgically modified anatomy, particularly in patients who underwent Billroth II and Roux-en-Y gastric surgery [6]. As reported by Wilson et al. [7], the main limitation for complete imaging of the head of the pancreas and of the common bile duct (CBD) is the difficulty in intubating the afferent limb with conventional radial and linear echoendoscopes. Moreover, because an increased complication rate has been reported in patients with surgically modified upper gastrointestinal anatomy during ERCP procedures (perforation rate up to 18% and a mortality of 0% to 3%), consequently, it has been assumed that EUS may also be associated with increased risk of complications in these patients.

Water-filled technique: technical description

We describe a unique and easy-to-perform technique to overcome the difficulties of EUS in patients with surgically modified upper gastrointestinal anatomy: the water-filled technique (WFT). We are currently using the WFT during EUS procedures in our centers for examination of and tissue acquisition in the pancreato-biliary region and to treat patients with MBO using EUS-BD. Although it is not mandatory before performing WFT-EUS, previous upper gastrointestinal endoscopy evaluation using a forward-viewing endoscope is useful to identify the afferent loop and to visualize the papillary area.

During the WFT, the echoendoscope is advanced up to the gastro-jejunal anastomosis, placing the tip of the scope approximately 2 cm beyond it. Room-temperature saline solution is manually flushed inside the operative channel of the echoendoscope using a 50-mL syringe to enlarge the jejunal lumen more than 1.5 cm on the EUS image. The tip of the scope is then slowly advanced under EUS guidance (► Fig. 1) until the duodenum is reached, using slow clockwise and counterclockwise rotation movements, in a retrograde way (► Video 1). The volume of saline solution required to reach 1.5 cm depends on the length of the (afferent) loop, generally ranging between 500 mL and 1000 mL. Tap water can be used as an alternative, if declared potable by the hospital.

During the procedure, the patient is placed on the left side and because the saline instillation starts beyond the gastro-jejunal anastomosis, intubation is not necessary. Once the tip of the scope reaches the ampullary area, diagnostic EUS, tissue acquisition or LAMS placement into the CBD or in the gallbladder are possible [8]. This technique is applicable in patients with Billroth II or Roux-en-Y reconstruction.

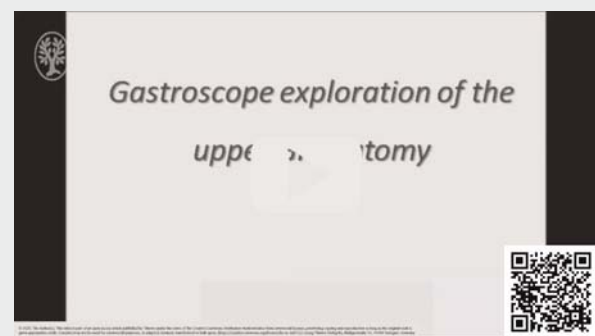


► Fig. 1 Echoendoscope advanced under EUS-guidance using the WFT.

Discussion

Examination of the pancreato-biliary region with EUS using the WFT in patients who have undergone upper gastrointestinal surgery such as Billroth II and Roux-en-Y reconstruction is a feasible technique in expert hands. Diagnostic pancreato-biliary EUS, with or without tissue acquisition, is mainly performed to confirm the presence of choledocholithiasis or to sample pancreatic lesions. Most endoscopists, in the presence of surgically altered upper gastrointestinal anatomy, terminate the procedure without reaching and examining the ampullary region, leading to a delay in diagnosis. The major advantage of the WFT, compared to the traditional technique where the scope is advanced using air or carbon dioxide (CO₂) insufflation to dilate the jejunum lumen, is that it does not require intense push-

► VIDEO



► Video 1 The technique for advancing the scope from the gastro-jejunal anastomosis to the pancreato-biliary region using the WFT.

ing of the scope to advance in the bent loops, reducing the risk of adverse events such as perforation. Indeed, using the WFT, the scope must be advanced very slowly, with the tip of the scope parallel to the jejunal or duodenal wall, inside the anechoic area represented by the water inside the lumen itself. The main technical failure of the WFT occurs in the presence of a very long afferent jejunal loop, because the length of the scope might not allow for reaching the pancreato-biliary region.

Failures of EUS imaging of the head of the pancreas and of the common bile duct have been reported in up to 50% of patients with surgically modified anatomy. In a retrospective series from 2009, 37 patients with surgically altered upper gastrointestinal anatomy underwent EUS examination with a forward-viewing echoendoscope; the authors reported technical failure to reach the papillary area in 25% of cases, and all failures occurred in Roux-en-Y patients [9]. Therefore, observational studies or randomized controlled trials are warranted to evaluate the efficacy and safety of the WFT compared to standard and other techniques.

Conclusion

In conclusion, the WFT is easy to perform and useful to reach the ampullary area in patients with surgically modified upper gastrointestinal anatomy, allowing performance of both diagnostic and therapeutic pancreato-biliary EUS procedures. The technique is also reproducible and can be easily adopted by endoscopists who regularly perform EUS.

Competing interests

The authors declare that they have no conflict of interest.

References

- [1] Pietryga JA, Morgan DE. Imaging preoperatively for pancreatic adenocarcinoma. *J Gastrointest Oncol* 2015; 6: 343–357
- [2] Del Chiaro M, Segersvard R, Lohr M et al. Early detection and prevention of pancreatic cancer: is it really possible today? *World J Gastroenterol* 2014; 20: 12118–12131
- [3] Ngamruengphong S, Li F, Zhou Y et al. EUS and survival in patients with pancreatic cancer: a population-based study. *Gastrointest Endosc* 2010; 72: 78–83
- [4] Mangiavillano B, Khashab MA, Tarantino I et al. Success and safety of endoscopic treatments for concomitant biliary and duodenal malignant stenosis: A review of the literature. *World J Gastrointest Surg* 2019; 11: 53–61
- [5] Mangiavillano B, Auriemma F, Scaltrini F et al. Endoscopic ultrasonography-guided radiofrequency ablation for a perianastomotic neoplastic colorectal recurrence. *Am J Gastroenterol* 2019; 114: 1709
- [6] Wright BE, Cass OW, Freeman ML. ERCP in patients with long-limb Roux-en-Y gastrojejunostomy and intact papilla. *Gastrointest Endosc* 2002; 56: 225–232
- [7] Wilson JA, Hoffman B, Hawes RH et al. EUS in patients with surgically altered upper GI anatomy. *Gastrointest Endosc* 2010; 72: 947–953
- [8] Mangiavillano B, Auriemma F, Mezzananza M et al. Fine needle biopsy (FNB) plus EUS-guided cholecysto-jejunostomy by LAMS with water-filled technique in a patient with roux-en-y reconstruction. *Am J Gastroenterol* 2020; 115: 1572
- [9] Fusaroli P, Serrani M, Lisotti A et al. Performance of the forward-view echoendoscope for pancreaticobiliary examination in patients with status post-upper gastrointestinal surgery. *Endosc Ultrasound* 2015; 4: 336–341