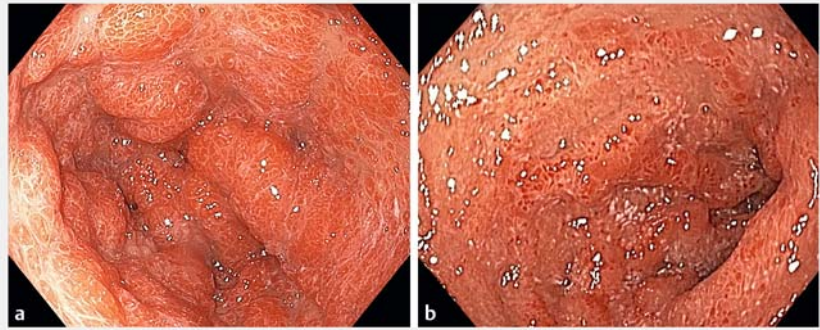


Endoscopic features of Cronkhite–Canada syndrome

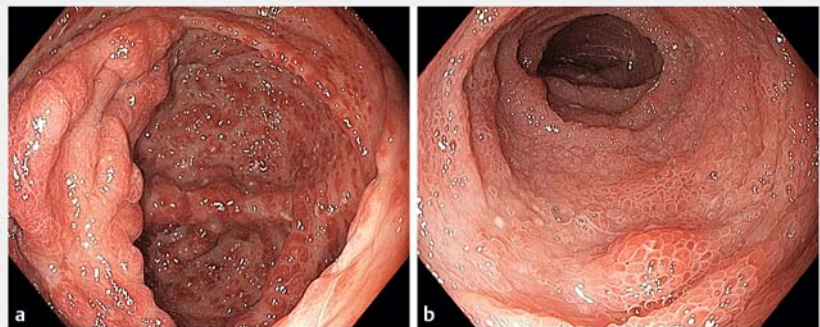
Cronkhite–Canada syndrome (CCS) is a rare protein-losing enteropathy and profound malnutrition disease with high mortality [1–3]. CCS can be challenging to differentiate from other polyposis syndromes [4]. We describe the endoscopic features of CCS before and after treatment.

A 69-year-old woman presented with chronic diarrhea, body pigmentation, weight loss, and dysgeusia. Examination showed alopecia, glossitis, onycholysis, and palmar pigmentation. Her laboratory values showed abnormally low albumin (26 g/dL), hemoglobin (11 g/dL), and zinc (658 µg/L). Computed tomogram of the abdomen showed thickened folds and polyp-like protrusions in the stomach.

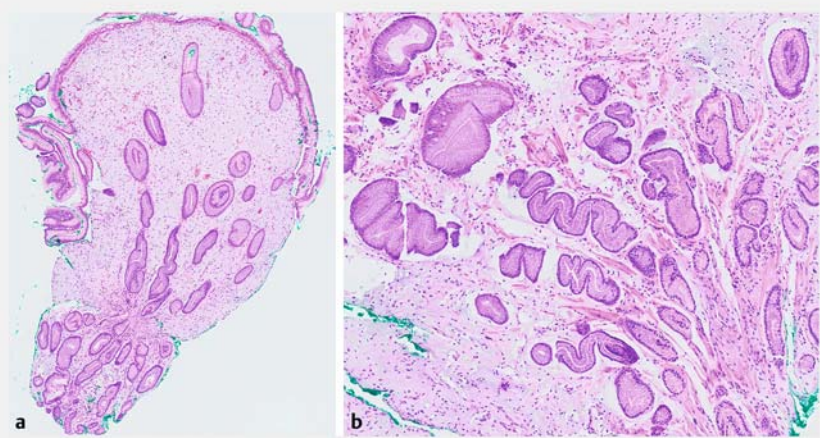
We performed an upper endoscopy, which showed normal esophagus. Upon entering the stomach, multiple large inflammatory polyps covering the antrum and body were seen (► Fig. 1). The duodenum showed mucosal edema, villous blunting, and atrophy. Similarly, colonoscopy revealed extensive large inflammatory polyps throughout the colon. The ileum appeared edematous with villous atrophy (► Fig. 2). Biopsies performed from the gastric polyps showed mild infiltration with inflammatory cells, submucosal edema, and tortuous hyperplastic foveolar glands (► Fig. 3). Based on the clinical features, characteristic endoscopic appearance, and histopathology findings, we diagnosed the patient to have CCS. We treated her using a tapering dose of prednisolone, azathioprine, and proton pump inhibitors. We provided oral nutritional supplements and corrected the micronutrient deficiency. After 3 months of treatment, her symptoms started to resolve. We repeated upper endoscopy and colonoscopy, which showed a regression of her gastric and colonic polyps (► Fig. 4, ► Fig. 5). The villous atrophy and blunting in the small bowel had reversed. We have reviewed our other similar cases, followed over an



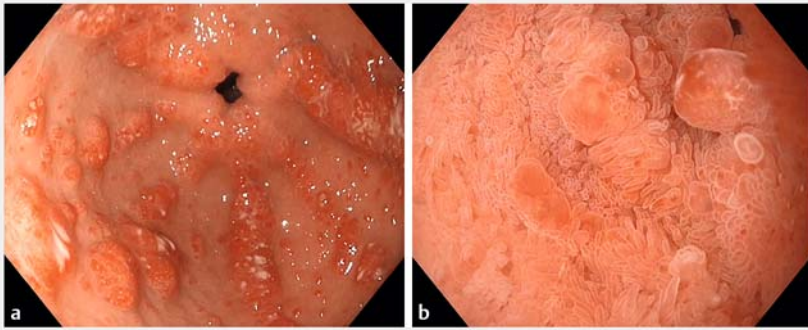
► Fig. 1 Upper endoscopy at diagnosis: a multiple large inflammatory polyps in the gastric antrum; b edematous duodenal mucosa with villous atrophy.



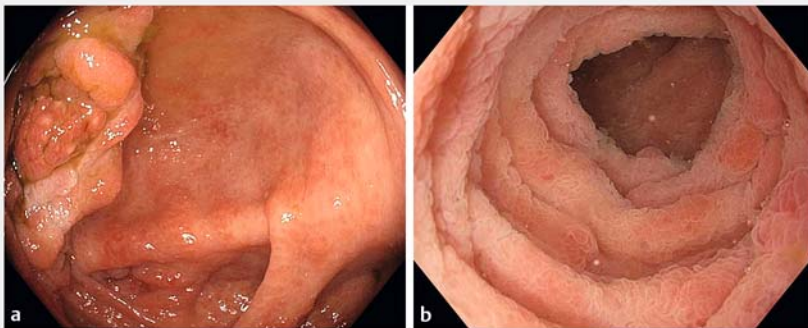
► Fig. 2 Colonoscopy at diagnosis: a large inflammatory polyps carpeting the colon; b villous atrophy in the ileum.



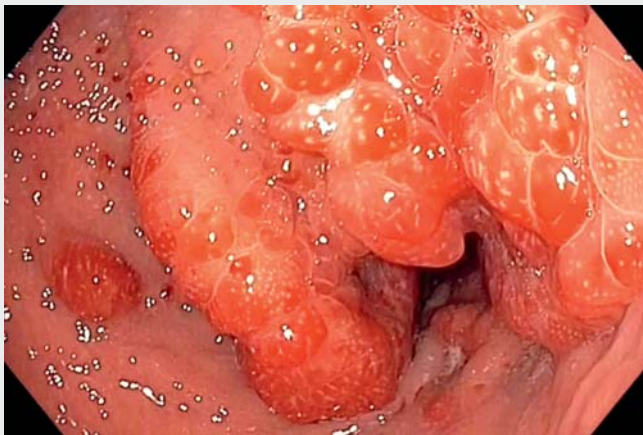► Fig. 3 Biopsy from the gastric polyp: a mild infiltration with inflammatory cells with submucosal edema; b tortuous foveolar gland hyperplasia.



► **Fig. 4** Upper endoscopy after 3 months of treatment: **a** decrease and disappearance of inflammatory gastric polyps; **b** reversal of villous blunting in the duodenum.



► **Fig. 5** Colonoscopy after 3 months of treatment: **a** disappearance of colonic inflammatory polyps; **b** improvement in villous blunting and edema.



► **Video 1** Endoscopic features of Cronkhite–Canada syndrome.

extended time (3 years), that were treated with long-term immunosuppressants (► **Video 1**). The patients have remained asymptomatic during the follow-up time. In conclusion, recognizing the distinct and specific endoscopic features of CCS

may allow it to be diagnosed and differentiated from other polyposis syndromes (► **Video 1**). Uniquely, in CCS, the multiple large inflammatory polyps may be reversed with treatment [3, 5].

Endoscopy_UCTN_Code_CCL_1AB_2AC_3AB

Competing interests

Dr. Roy Soetikno is a consultant for Olympus and Fujifilm.

The authors

Ravishankar Asokkumar^{1,2}, **Steven Mesenas**^{1,2}, **Roy Soetikno**^{1,2,3}

- 1 Department of Gastroenterology and Hepatology, Singapore General Hospital
- 2 Duke-NUS Graduate Medical School, Singapore
- 3 National Cancer Center, Singapore

Corresponding author

Ravishankar Asokkumar, MD

Singapore General Hospital, National Cancer Center Singapore and Duke-NUS Graduate Medical School, 20 College Road, Singapore 169608
ravishnkr03@gmail.com

References

- [1] Jarnum S, Jensen H. Diffuse gastrointestinal polyposis with ectodermal changes. A case with severe malabsorption and enteric loss of plasma proteins and electrolytes. *Gastroenterology* 1966; 50: 107–118
- [2] Riegert-Johnson DL, Osborn N, Smyrk T et al. Cronkhite–Canada syndrome hamartomatous polyps are infiltrated with IgG4 plasma cells. *Digestion* 2007; 75: 96–97
- [3] Daniel ES, Ludwig SL, Lewin KJ et al. The Cronkhite–Canada syndrome. An analysis of clinical and pathologic features and therapy in 55 patients. *Medicine (Baltimore)* 1982; 61: 293–309
- [4] Burke AP, Sobin LH. The pathology of Cronkhite–Canada polyps: a comparison to juvenile polyposis. *Am J Surg Pathol* 1989; 13: 940–946
- [5] Chadalavada R, Brown DK, Walker AN et al. Cronkhite–Canada syndrome: sustained remission after corticosteroid treatment. *Am J Gastroenterol* 2003; 98: 1444–1446

Bibliography

Endoscopy 2021; 53: E411–E412

DOI 10.1055/a-1333-0796

ISSN 0013-726X

published online 14.1.2021

© 2021. Thieme. All rights reserved.

Georg Thieme Verlag KG, Rüdigerstraße 14, 70469 Stuttgart, Germany