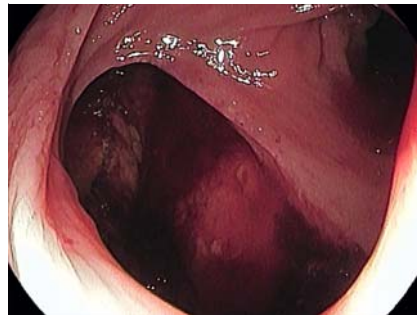


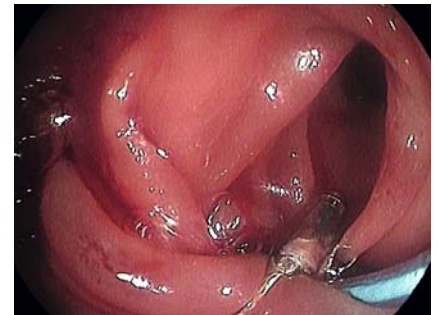Large iatrogenic sigmoid colon perforation treated with endoloop-assisted clip closure and over-the-scope clip: a case report

A 77-year-old woman was admitted to our Emergency Department for an iatrogenic sigmoid colon perforation that occurred during a diagnostic colonoscopy. The patient complained of moderate abdominal pain without signs of peritonitis. Considering the time since colonoscopy (<2 hours) and the excellent bowel preparation, an attempt was made to treat the perforation endoscopically. Therapeutic colonoscopy was performed under monitored anesthesia care using a single-channel therapeutic gastroscope (EG-3490K; Pentax Medical, Tokyo, Japan) and CO₂ insufflation. A 6-cm large full-thickness wall defect at 25 cm from the anal verge, with active oozing bleeding, was detected (► **Fig. 1**). Bleeding was controlled with 1:10000 adrenaline injection; thereafter an endoloop-assisted clip closure was performed.

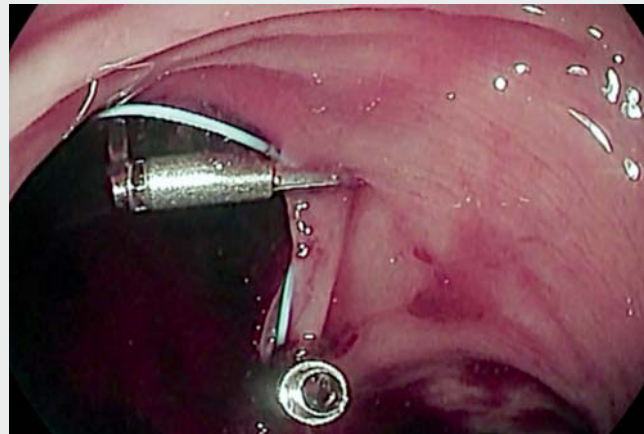
We opened a 30-mm endoloop (HX-400U-30; Olympus Medical Systems Corp., Tokyo, Japan) around the wall defect; the cable was anchored to the hole margins by launching, one by one, four 13-mm through-the-scope clips (MD-G-HR-230-13-135; Zhejiang Chuangxiang Medical Technology Co., Ltd., Hangzhou, China); then the endoloop was hooked, closed, and finally released (► **Fig. 2**). The contrastography showed a 6-mm residual wall defect that was treated deploying a 12-mm t-type over-the-scope clip (OTSC) (Ovesco, Tübingen, Germany), with no contrast agent extravasation at the end. A computed tomography (CT) scan after the procedure confirmed the absence of contrast extravasation on luminal contrastography. The patient was managed conservatively with bowel rest, intravenous fluids, and broad-spectrum antibiotic therapy. After 5 days, oral feeding was resumed and the patient was discharged. A CT scan with colonic contrast injection performed after 3 weeks showed a complete resolution (► **Video 1**).



► **Fig. 1** Full-thickness wall defect of the sigmoid colon.



► **Fig. 2** Wall defect after endoloop-assisted clip closure.



► **Video 1** Large iatrogenic sigmoid colon perforation treated with endoloop-assisted clip closure and over-the-scope clip.

The endoloop-assisted clip closure technique has been reported as a therapeutic solution for iatrogenic perforations. The timing since the perforation is crucial in order to effectively close the leak [1–5]. In conclusion, in selected cases, the combined endoscopic rescue therapy with endoloop-assisted clip closure and OTSC can be effective in conservative treatment of colonic perforations.

Endoscopy_UCTN_Code_CPL_1AJ_2AH

Competing interests

The authors declare that they have no conflict of interest.

The authors

Salvatore Russo¹ , Giuseppe Grande¹,
Raffaele Manta², Santi Mangiafico¹, Helga
Bertani¹, Flavia Pigò¹, Rita Conigliaro¹

- 1 Azienda Ospedaliero-Universitaria di Modena, Gastroenterology and Digestive Endoscopy Unit
- 2 Azienda Ospedaliera di Perugia, Gastroenterology and Digestive Endoscopy Unit

Corresponding author

Salvatore Russo, MD

Azienda Ospedaliero-Universitaria di Modena, Gastroenterology and Digestive Endoscopy Unit, Via Pietro Giardini 1355, 41126 Modena, Italy
russo.salvatore@aou.mo.it

References

- [1] Paspatis GA, Arvanitakis M, Dumonceau JM et al. Diagnosis and management of iatrogenic endoscopic perforations: European Society of Gastrointestinal Endoscopy (ESGE) Position Statement – Update 2020. *Endoscopy* 2020; 52: 792–810
- [2] Ryu JY, Park BK, Kim WS et al. Endoscopic closure of iatrogenic colon perforation using dual-channel endoscope with an endoloop and clips: methods and feasibility data (with videos). *Surg Endosc* 2019; 33: 1342–1348
- [3] Dolezel R, Ryska O, Kollar M et al. A comparison of two endoscopic closures: over-the-scope clip (OTSC) versus KING closure (endoloop + clips) in a randomized long-term experimental study. *Surg Endosc* 2016; 30: 4910–4916
- [4] Katsinelos P, Lazaraki G, Chatzimavroudis G et al. Closure of an iatrogenic rectal perforation with the endoloop/clips technique in a purse-string fashion. *Ann Gastroenterol* 2014; 27: 264
- [5] Hookey LC, Khokhotva V, Bielawska B et al. The Queen's closure: a novel technique for closure of endoscopic gastrotomy for natural-orifice transluminal endoscopic surgery. *Endoscopy* 2009; 41: 149–153

Bibliography

Endoscopy 2021; 53: E433–E434
DOI 10.1055/a-1333-0620
ISSN 0013-726X
published online 27.1.2021
© 2021. Thieme. All rights reserved.
Georg Thieme Verlag KG, Rüdigerstraße 14,
70469 Stuttgart, Germany

ENDOSCOPY E-VIDEOS

<https://eref.thieme.de/e-videos>



Endoscopy E-Videos is a free access online section, reporting on interesting cases and new

techniques in gastroenterological endoscopy. All papers include a high quality video and all contributions are freely accessible online.

This section has its own submission website at

<https://mc.manuscriptcentral.com/e-videos>