

Initial experience with per-rectal endoscopic myotomy for Hirschsprung's disease: medium and long term outcomes of the first case series of a novel third-space endoscopy procedure

Authors

Amol Bapaye¹ , Parag Dashatwar¹, Vishnu Biradar¹, Shital Biradar², Rajendra Pujari¹

Institutions

- 1 Shivanand Desai Center for Digestive Disorders, Deenanath Mangeshkar Hospital and Research Center, Pune, India
- 2 Department of Pathology, Deenanath Mangeshkar Hospital and Research Center, Pune, India

submitted 3.10.2020

accepted after revision 8.12.2020

published online 8.12.2020

Bibliography

Endoscopy 2021; 53: 1256–1260

DOI 10.1055/a-1332-6902

ISSN 0013-726X

© 2020. Thieme. All rights reserved.

Georg Thieme Verlag KG, Rüdigerstraße 14, 70469 Stuttgart, Germany

 Table s1, s2

Supplementary material is available under

<https://doi.org/10.1055/a-1332-6902>

Corresponding author

Amol Bapaye, MD, Shivanand Desai Center for Digestive Disorders, Deenanath Mangeshkar Hospital and Research Center, Erandwane, Pune 411004, Maharashtra, India
amolbapaye@gmail.com

ABSTRACT

Introduction Hirschsprung's disease (HSCR) is congenital aganglionosis affecting the hindgut and presents with constipation. Surgical pull-through is the current standard treatment but causes morbidity. Per-rectal endoscopic myotomy is a novel third-space endoscopy technique for treating short-segment (SS)-HSCR.

Methods Retrospective study of SS-HSCR patients diagnosed on history, contrast enema, rectal biopsies, and anorectal manometry, and treated by PREM. The aganglionic segment was mapped before PREM was performed using third-space endoscopy principles. Stool frequency and laxative usage before and after PREM were compared.

Results Nine patients (age 7.5 [\pm 5.2] years; 7 male) underwent PREM during a 4-year period. Mean aganglionic segment length was 6.3 cm, mean procedure time 96.1 minutes, and mean length of hospital stay 2.5 days. Median follow-up was 17 months (range 9–58 months). Stool frequency was 1/4.4 days before vs. 1/1.2 days after PREM ($P = 0.0004$). Mean laxative usage was 5.4 units of laxative (UL) before vs. 0.4 UL after PREM ($P = 0.0002$). No laxatives were used by 6/9 patients after PREM. The single adverse effect seen (anal stenosis) was treated with dilatation.

Conclusions PREM is a safe and effective minimally invasive procedure to treat SS-HSCR and results in long-term response.

Introduction

Hirschsprung's disease (HSCR) is a congenital disorder characterized by absence of intrinsic ganglion cells in submucosal and myenteric plexuses of the hindgut [1]. This aganglionosis leads to loss of propulsive motor activity and tonic contraction of the affected bowel segment due to defective inhibitory innervation and apparently spared excitatory neuronal innervation. Clinically, this results in a distal stenotic colorectal segment with dilation of the proximal colon [1]. Functionally, this is similar to other gastrointestinal neuropathies like achalasia

cardia or gastroparesis. HSCR and achalasia cardia share similar hallmark manometric findings in terms of absent sphincter relaxation (lower esophageal sphincter or internal anal sphincter respectively).

HSCR is classified by the length of the aganglionic segment. Involvement of the sigmoid colon (short segment [SS], 53.8%) or rectum (ultra-short segment [USS], 25.6%) are the commonest variants [2]. Although the traditional treatment paradigm in HSCR has been resection of the aganglionic segment and reconstruction using pull-through operations with coloanal anastomosis, these operations are invasive and carry high morbidity

[3–5]. An alternative, surgical posterior anorectal myotomy/myectomy, has been described, based on the principle of disruption of the spastic aganglionic segment. This technique was effective in patients with USS-HSCR limited to the distal 5–8 cm [6–8].

Third-space endoscopy permits performance of longer or tailor-made myotomy, as is evident from peroral endoscopic myotomy (POEM) for achalasia cardia and G-POEM for gastroparesis. Based on this philosophy, per-rectal endoscopic myotomy (PREM) was conceptualized, successfully performed, and reported by the authors' group in the form of two case reports and one conference abstract on adults followed by pediatric and infantile SS-HSCR patients [9–11]. The current case series reports a single-center experience of PREM for SS-HSCR patients with medium-term to long-term follow-up.

Patients and methods

This study was a retrospective analysis of a prospectively maintained database of all patients undergoing PREM for SS-HSCR over 4 years.

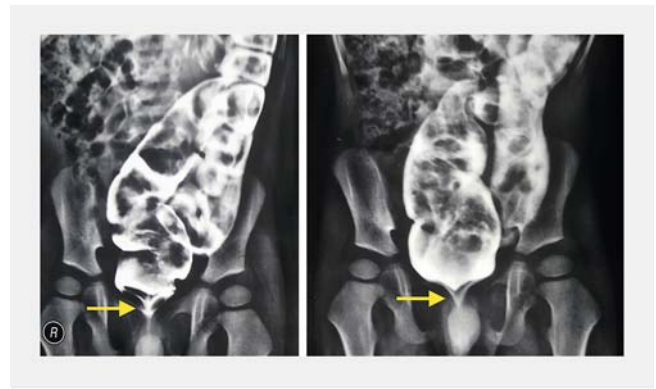HSCR was diagnosed by clinical history and contrast enema demonstrating the presence of a distal spastic segment and transition zone (► Fig. 1). Anorectal manometry (ARM) was performed, confirming absence of the rectoanal inhibitory reflex (RAIR) and high rectal basal pressures. Sigmoidoscopy-guided serial deep muco-submucosal biopsies were obtained every 4–5 cm using the cap-assisted endoscopic mucosal resection technique from the dilated segment up to 2 cm above the dentate line (► Fig. 2) [10, 12]. The presence of ganglia in proximal biopsies, transition-zone hypoganglionosis, and absent ganglia distally are classical signs of HSCR [13–16]. The aganglionic segment was thus measured and optimum myotomy length was tailored accordingly.

Stool frequency per given number of days and laxative usage was recorded. Laxative usage was recorded in units of laxative (UL) calculated as the product of “times standard dose” and “number of (types of) laxatives used.” Additional units were added for rectal enema use. The number of units of laxative required for regular bowel movement was recorded. Detailed consent was obtained from all patients (or, for children, their legal guardians) for PREM, after detailed discussion of available therapeutic options and their limitations and results.

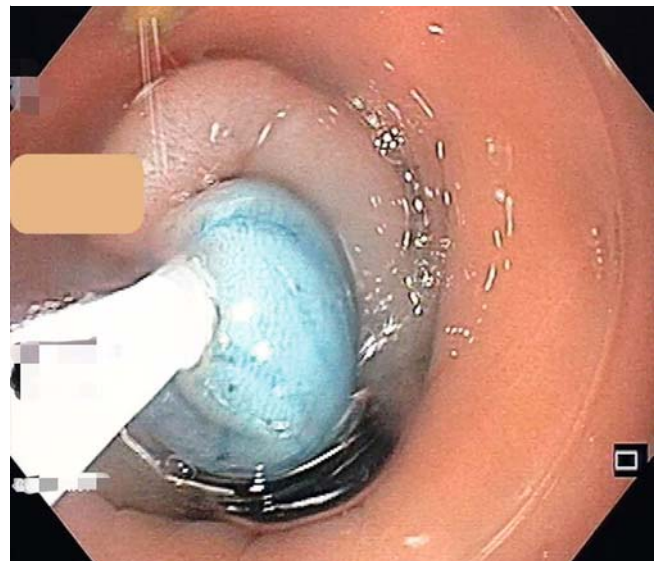
The PREM procedure

Polyethylene glycol (PEG) solution (50 mL/kg body weight) was used for bowel preparation, administered over 2 consecutive days with a clear liquid, low-residue diet. Additional colonoscopic bowel cleansing was performed when fecal loading was high. Intravenous third-generation cephalosporin and metronidazole were administered at commencement of PREM.

PREM was performed under general anesthesia with endotracheal intubation. Carbon dioxide insufflation was used throughout. Patients were operated on in a semi-jackknife position with buttocks strapped apart. Detailed steps of PREM (see ► Video 1) have been described previously [9, 10]. A high-definition gastroscope (GIF-HQ190, Olympus) with a distal

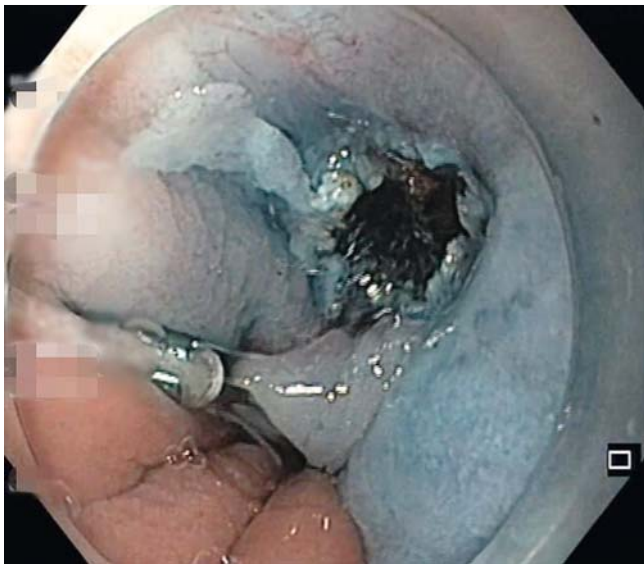

► Fig. 1 Barium enema demonstrating dilated proximal colon, spastic rectum, and conical transition zone classical of Hirschsprung's disease (conical transition zone is marked by yellow arrows).

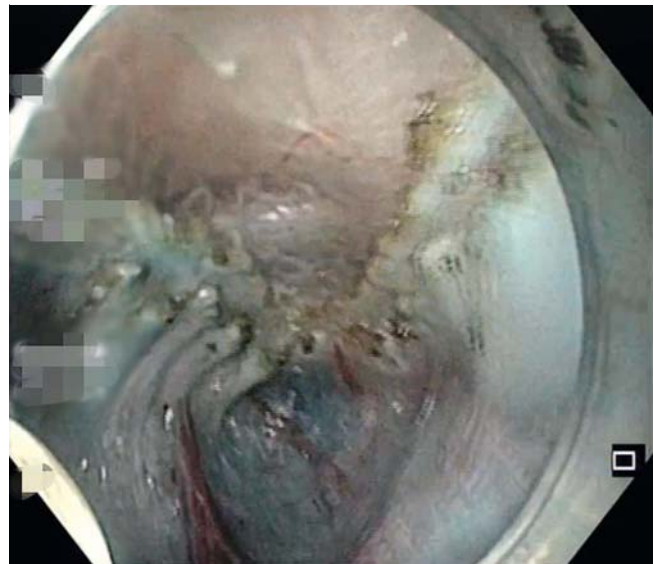

► Fig. 2 Technique of cap-assisted endoscopic mucosal resection biopsy.

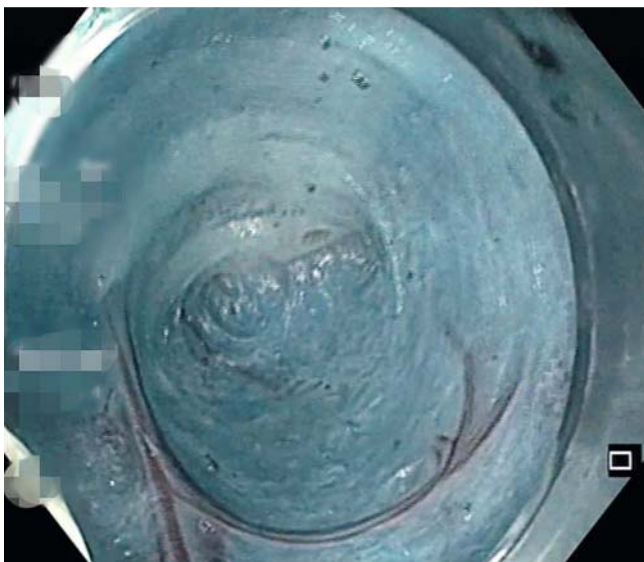
transparent attachment (Olympus) was used. Submucosal elevation was achieved using normal saline mixed with 0.25% methylene blue just inside the anorectal junction on the posterior rectal wall. The mucosal incision (15 mm) was made using a triangular tip TT-J knife (Olympus) and Endocut-Q current (Vio 200D, Erbe). After adequate submucosal space had been created, the endoscope was introduced into the tunnel. The clip-and-line technique was employed to facilitate entry whenever entry was difficult (► Fig. 3). Dissection in the submucosal tunnel continued close to the muscle layer and perpendicular to circular fibers (forced coagulation effect 2, 50W). The tunnel was extended beyond the spastic segment for the predefined distance (► Fig. 4). Full-thickness myotomy was performed using an IT2 knife (Olympus), starting at the apex of the submucosal tunnel in the caudad direction. Distally, internal anal sphincter fibers were divided in the cephalad direction (► Fig. 5). The external anal sphincter was carefully preserved.



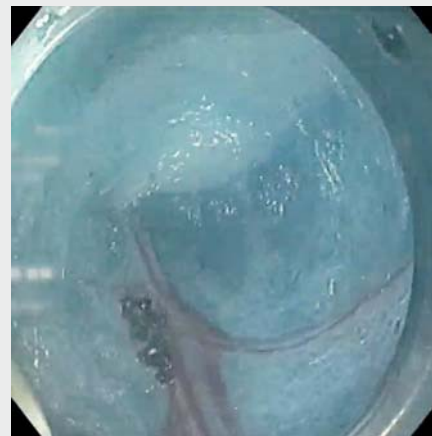
► **Fig. 3** Clip-and-line technique to gain access to the submucosal tunnel.



► **Fig. 5** Completed full-thickness myotomy.



► **Fig. 4** Completed tunnel.



► **Video 1** Steps of per-rectal endoscopic myotomy (PREM). After submucosal elevation, the mucosa is incised inside the anorectal junction. Submucosal tunneling followed by full-thickness myotomy is performed. The mucosa is closed using clips. Online content viewable at: <https://doi.org/10.1055/a-1332-6902>

Hemostasis was achieved using Coagrasper forceps (Olympus) (soft coagulation effect 4, 80W). The mucosal incision was closed using endoclips.

Patients were hospitalized for observation. Oral diet was started after 12 hours and patients were discharged after their first bowel movement (defined as the first occurrence of natural stool passage after PREM). Time to first bowel movement was recorded. Low-dose lactulose was prescribed for 2 weeks.

Follow-up was at 4–6 weeks. Patients were assessed for stool frequency, involuntary bowel movements and soiling if any, constipation, and laxative usage. Digital rectal examination was performed to assess sphincter tone. Follow-up sigmoidoscopy was recommended in all cases and ARM and/or contrast

enema in cases where there were residual symptoms. Subsequent telephonic follow-up was at 6-month intervals.

Objectives and definitions

The primary objective was to evaluate clinical improvement in constipation after PREM. Secondary objectives were: procedure-related immediate and delayed adverse events as defined using the ASGE lexicon [17]; time to first post-PREM bowel movement; and length of hospital stay (LOS).

Technical success was defined as successful completion of myotomy of the predefined length. Clinical success was defined

as relief of constipation, improvement in stool frequency, and reduction in laxative usage.

Statistical analysis

Continuous variables were recorded as mean (\pm SD) and median (range, interquartile range [IQR]) and categorical variables as median (range, IQR). The paired *t* test was used to calculate *P* values within subgroups. *P* < 0.05 was considered significant.

Results

Nine patients underwent PREM during a 4-year period (December 2015 to November 2019). Baseline demographics and clinical characteristics are summarized in **Table 1s** (see online-only supplementary material). Mean age was 7.5 (\pm 5.2) years, median 4 (range 1–24) years; there were seven males. Symptom onset was at birth or during late infancy. SS-HSCR was confirmed on contrast enema and serial biopsies in all patients. Mean aganglionic segment length was 6.3 (\pm 4.4) cm. All patients were treatment-naïve except for one, who had undergone stapled transanal rectal resection for assumed obstructed defecation syndrome 2 years earlier without symptom improvement.

PREM was technically successful in all nine patients. Mean procedure time was 96.1 (\pm 37.9) minutes. No peri-PREM adverse events were encountered. Mean LOS was 2.5 (\pm 0.7) days.

A median of 17 months (IQR 11–35, range 9–58) follow-up was available in all patients (**Table 2s**). Significant improvement in constipation was noted in all. Stool frequency improved from pre-PREM 1 in 4.4 (\pm 1.5) days to post-PREM 1 in 1.2 (\pm 0.4) days (*P* = 0.0004). Laxative usage reduced from pre-PREM mean 5.4 UL (\pm 4.9, range 2–18) to post-PREM mean 0.4 UL (\pm 0.7, range 0–2) (*P* = 0.0002). No laxative was required in 6/9 patients after PREM, while a less than 50% dose was required in the remaining 3. No new-onset incontinence was noted.

Post-PREM high-resolution ARM was obtained in 3/9 patients and revealed normalized basal and squeeze pressures. The first patient developed mild anal stenosis 8 months after the procedure, requiring a single session of digital anal dilatation.

Discussion

Traditionally, SS-HSCR has been treated by single or multistage transanal pull-through procedures, although high morbidity up to 40% is reported [3–5]. Minimally invasive transanal or endorectal approaches have also been reported as associated with a high incidence of internal anal sphincter damage [8]. In contrast to this, PREM brings new hope to these patients with SS-HSCR.

Posterior anorectal myotomy/myectomy without bowel resection has been effective for USS-HSCR, but can only be applied for the distal 5–8 cm of the rectum [6–8]. PREM, being performed using third-space endoscopy principles, overcomes these surgical limitations and permits myotomy extension to the desired length. In the present case series, the longest aganglionic segment was 15 cm and the longest myotomy was 20 cm. PREM was successful over a wide range of ages (1–24

years). PREM can thus be considered a safe and widely applicable procedure for treatment of SS-HSCR.

Technical success was 100% and there were no peri-PREM adverse events. All patients had significant resolution of constipation, and incontinence was not encountered. ARM in 3/9 patients demonstrated normalized basal and squeeze pressures. Laxative usage reduced significantly from pre-PREM values. These results were sustained at a median of 17 months after PREM, with the longest follow-up being 58 months. No recurrences were noted. PREM, therefore, demonstrates excellent efficacy as a novel minimally invasive treatment for SS-HSCR.

A similar experimental procedure in porcine models – peranal endoscopic myotomy (PAEM) – was described for treatment of internal anal sphincter achalasia [18], but no further reference to human application is available. In our opinion, the term “per-rectal” is more suited in this regard since the myotomy extends inside the rectum and is not limited to the anal canal.

Recently, Bandres et al. reported successful PREM for post-surgical recurrent HSCR with impressive results at 8 months follow-up [19]. This is an interesting indication that requires further investigation.

The main limitations of this study are its retrospective design and small sample size, and the absence of established objective parameters for response evaluation after therapy. We have attempted to somewhat address this limitation by defining clinical parameters – stool frequency and laxative usage as measured in defined units of laxative (UL) – to assess post-PREM response. Post-PREM ARM was not systematically available for all due to the retrospective nature of the study.

In conclusion, PREM presents a novel minimally invasive treatment option for SS-HSCR with minimal morbidity and impressive medium-term and long-term efficacy. Further studies with a larger sample size are required to confirm these results.

Competing interests

The authors declare that they have no conflict of interest.

References

- [1] Wyllie R. Motility disorders and Hirschsprung disease. In: Kliegman R, Behrman R, Jenson H, Stanton B, eds. Nelson textbook of pediatrics. 18th edn. Philadelphia, PA: Saunders Elsevier 2008: 1565–1567
- [2] Ikeda K, Goto S. Diagnosis and treatment of Hirschsprung's disease in Japan. An analysis of 1628 patients. *Ann Surg* 1984; 199: 400–405
- [3] Bai Y, Chen H, Hao J et al. Long term outcome and quality of life after Swenson procedure for Hirschsprung's disease. *J Pediatr Surg* 2002; 37: 639–642
- [4] Pini Prato A, Gentilino V, Giunta C et al. Hirschsprung's disease: 13 years' experience in 112 patients from a single institution. *Pediatr Surg Int* 2008; 24: 175–182
- [5] Rentea RM, Snyder CL. Early and late complications following pull-through operation for Hirschsprung's disease. In: Puri P, ed. Hirschsprung's disease and allied disorders. 4th edn. Springer International 2019: 383–401

- [6] Lynn HB, van Heerden JA. Rectal myectomy in Hirschsprung disease: a decade of experience. *Arch Surg* 1975; 110: 991–994
- [7] Sawin R, Hatch E, Schaller R et al. Limited surgery for lower-segment Hirschsprung's disease. *Arch Surg* 1994; 129: 920–924
- [8] Thomas CG Jr., Bream CA, DeConnick P. Posterior sphincterotomy and rectal myotomy in the management of Hirschsprung's disease. *Ann Surg* 1970; 171: 796–810
- [9] Bapaye A, Waghlikar G, Jog S et al. Per rectal endoscopic myotomy for the treatment of adult Hirschsprung's disease: first human case (with video). *Dig Endosc* 2016; 28: 680–684
- [10] Bapaye A, Bharadwaj T, Mahadik M et al. Per-rectal endoscopic myotomy (PREM) for pediatric Hirschsprung's disease. *Endoscopy* 2018; 50: E644–E645
- [11] Bapaye A, Mahadik M, Kumar Korrapati S et al. Per rectal endoscopic myotomy (PREM) for infantile Hirschsprung's disease. *Endoscopy* 2018; 50: OP209V
- [12] Nabi Z, Chavan R, Shava U et al. A novel endoscopic technique to obtain rectal biopsy specimens in children with suspected Hirschsprung's disease. *VideoGIE* 2018; 3: 157–158
- [13] Knowles CH, De Giorgio R, Kapur RP et al. The London classification of gastrointestinal neuromuscular pathology: report on behalf of the Gastro 2009 International Working Group. *Gut* 2010; 59: 882–887
- [14] Subramanian H, Badhe BA, Toi PC et al. Morphometric profile of large intestinal neuronal plexuses in normal perinatal autopsies and Hirschsprung disease. *Neurogastroenterol Motil* 2017; 29: e12939
- [15] Kapur RP. Intestinal motor disorders. In: Russo P, Ruchelli E, Piccoli D. *Pathology of pediatric gastrointestinal and liver disease*. 2nd edn. Berlin, Heidelberg: Springer; 2014: 255–270
- [16] Qualman SJ, Jaffe R, Bove KE et al. Diagnosis of Hirschsprung disease using the rectal biopsy: multi-institutional survey. *Pediatr Dev Pathol* 1999; 2: 588–596
- [17] Cotton PB, Eisen GM, Aabakken L et al. A lexicon for endoscopic adverse events: report of an ASGE workshop. *Gastrointest Endosc* 2010; 71: 446–454
- [18] Wang L, Cai Q, Fan C et al. Mo1628 A new potential method per anus endoscopic myotomy for treatment of internal anal sphincter achalasia. *Gastrointest Endosc* 2013; 77: AB451 doi:10.1016/j.gie.2013.03.376
- [19] Bandres DJ, Prada CE, Soto JR et al. Tu1690 Per rectal endoscopic myotomy for Hirschsprung's disease in rescue of unsuccessful previous surgical myomectomy. *Gastroenterology* 2019; 156: S1501 doi:10.1016/S0016-5085(19)40832-9