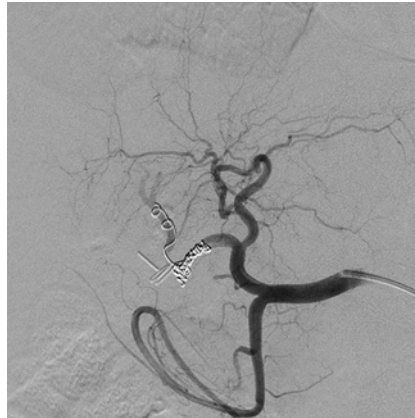

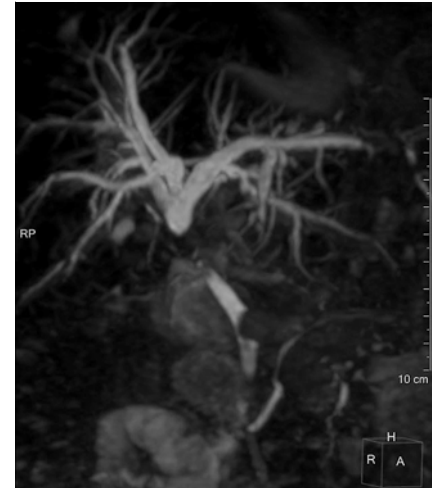## Percutaneous cholangioscopy to remove endovascular coils that had migrated into the bile duct after right hepatic artery pseudoaneurysm embolization

Right hepatic arterial injury is a common vascular injury during laparoscopic cholecystectomy, occurring in approximately 25% of patients with biliary injuries [1]. We report the case of a 78-year-old man who, 1 month after undergoing a laparoscopic cholecystectomy, was referred for hemobilia and collapse caused by the rupture of a cystic artery pseudoaneurysm into the common bile duct (CBD). Angiography showed active bleeding that was treated by conventional coil embolization [2] (► **Fig. 1**).

The patient was re-referred with obstructive cholangitis 1 month later (► **Fig. 2**), but endoscopic retrograde cholangiopancreatography (ERCP) failed owing to a bile duct stricture that could not be passed. We then performed percutaneous transhepatic biliary drainage to gauge the stricture over the course of a year (► **Fig. 3 a**). We removed the drain after 1 year with correct sizing of the stricture, but cholangitis subsequently recurred, requiring further percutaneous drainage prior to performing percutaneous cholangioscopy (CHF type V choledochoscope; Olympus, Tokyo, Japan). During cholangioscopy, we identified coils that had migrated into the CBD and easily removed these by pushing them



► **Fig. 1** Angiographic image in a 78-year-old man with rupture of a cystic artery pseudoaneurysm into the common bile duct, 1 month after undergoing a laparoscopic cholecystectomy, that was treated with coil embolization.



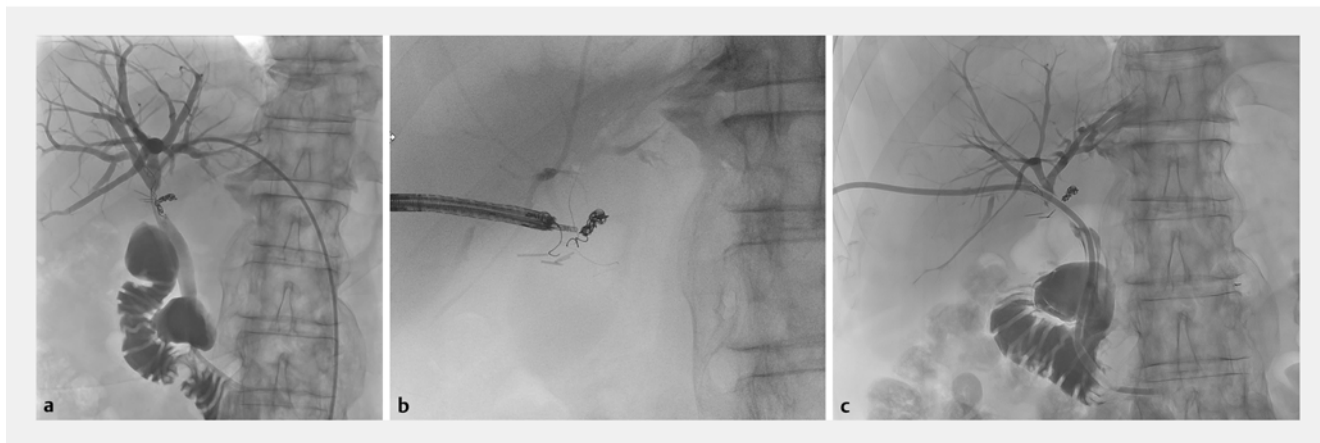
► **Fig. 2** Biliary magnetic resonance imaging performed after the patient developed obstructive cholangitis.

with a biopsy forceps into the duodenum (► **Fig. 3 b**; ► **Video 1**). The patient was discharged with transhepatic drainage for an additional 3 months (► **Fig. 3 c**). We hope that the removal of the coils will improve CBD healing, although we fear the development of an ischemic biliary stenosis.

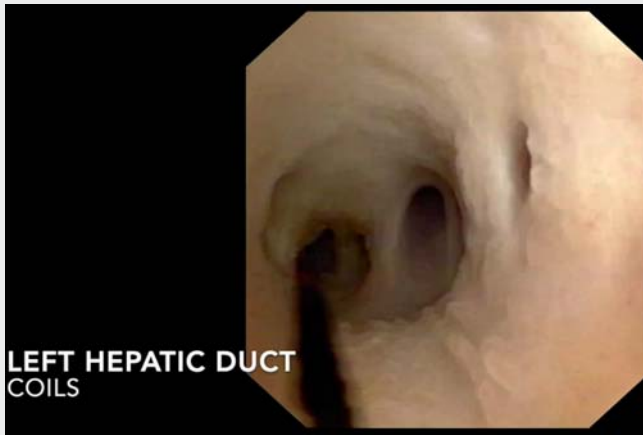
Few cases of coil migration into the CBD have been reported [3] and ERCP treat-

ment has been suggested [4], but the percutaneous approach is another option. In this video, we demonstrate the removal of migrated coils with a percutaneous endoscopic approach, thereby avoiding complex surgery.

Endoscopy\_UCTN\_Code\_TTT\_1AR\_2AK



► **Fig. 3** Fluoroscopic images showing: **a** the initial cholangiographic appearance after percutaneous transhepatic biliary drainage; **b** coil removal during percutaneous cholangioscopy; **c** follow-up cholangiographic image.



**Video 1** Percutaneous cholangioscopy to remove endovascular coils that had migrated into the bile duct after right hepatic artery pseudoaneurysm embolization.

- [3] Raashed S, Chandrasegaram MD, Alsaleh K et al. Vascular coil erosion into hepaticojunostomy following hepatic arterial embolisation. *BMC Surg* 2015; 15: 51
- [4] Kao WY, Chiou YY, Chen TS. Coil migration into the common bile duct after embolization of a hepatic artery pseudoaneurysm. *Endoscopy* 2011; 43: E364–E365

## Bibliography

*Endoscopy* 2021; 53: E448–E449

DOI 10.1055/a-1322-1942

ISSN 0013-726X

published online 4.2.2021

© 2021. Thieme. All rights reserved.

Georg Thieme Verlag KG, Rüdigerstraße 14, 70469 Stuttgart, Germany

## Competing interests

The authors declare that they have no conflict of interest.

## The authors

Jérôme Rivory<sup>1</sup>, Badis Menassel<sup>2</sup>, Thomas Lambin<sup>1</sup>, Florian Rostain<sup>1</sup>, Laurent Milot<sup>2</sup>, Thierry Ponchon<sup>1</sup>, Mathieu Pioche<sup>1,3</sup>

- 1 Department of Endoscopy and Gastroenterology, Pavillon L, Edouard Herriot Hospital, Lyon, France
- 2 Department of Radiology, Pavillon B, Edouard Herriot Hospital, Lyon, France
- 3 Inserm U1032 LabTau, Lyon, France

## Corresponding author

**Jérôme Rivory, MD**

Endoscopy unit – Digestive Disease department, Pavillon L – Edouard Herriot Hospital, 69437 Lyon, France  
jerome.rivory@chu-lyon.fr

## References

- [1] Strasberg SM, Helton WS. An analytical review of vasculobiliary injury in laparoscopic and open cholecystectomy. *HPB* 2011; 13: 1–14
- [2] Tulsyan N, Kashyap VS, Greenberg RK et al. The endovascular management of visceral artery aneurysms and pseudoaneurysms. *J Vasc Surg* 2007; 45: 276–283

## ENDOSCOPY E-VIDEOS

<https://eref.thieme.de/e-videos>



*Endoscopy E-Videos* is a free access online section, reporting on interesting cases and new

techniques in gastroenterological endoscopy. All papers include a high quality video and all contributions are freely accessible online.

This section has its own submission website at

<https://mc.manuscriptcentral.com/e-videos>