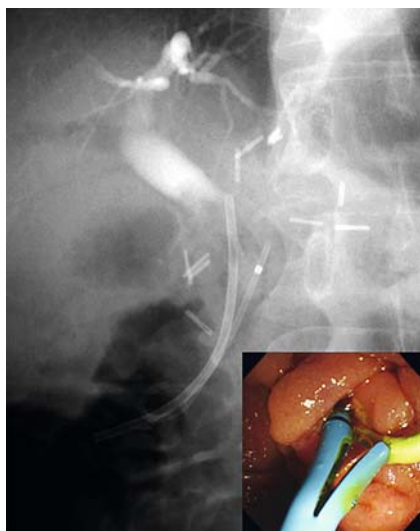
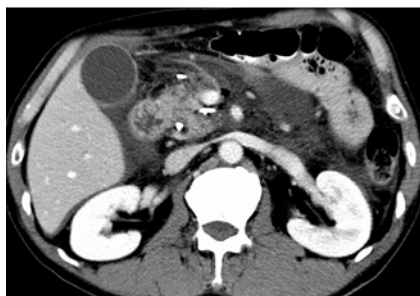

## Pancreatic perforation and fistula caused by pancreatic spontaneous dislodgement stent: an endoscopic rescue technique

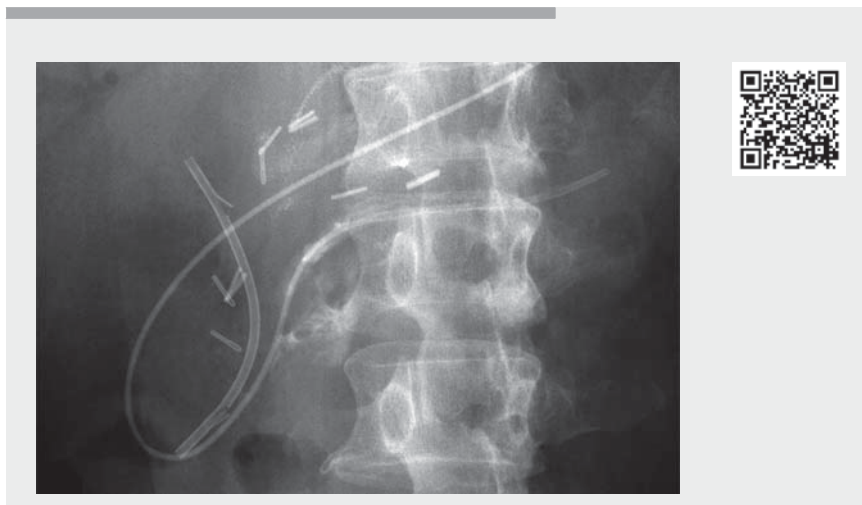


► **Fig. 1** Endoscopic image showing biliary stent and pancreatic spontaneous dislodgement stent.

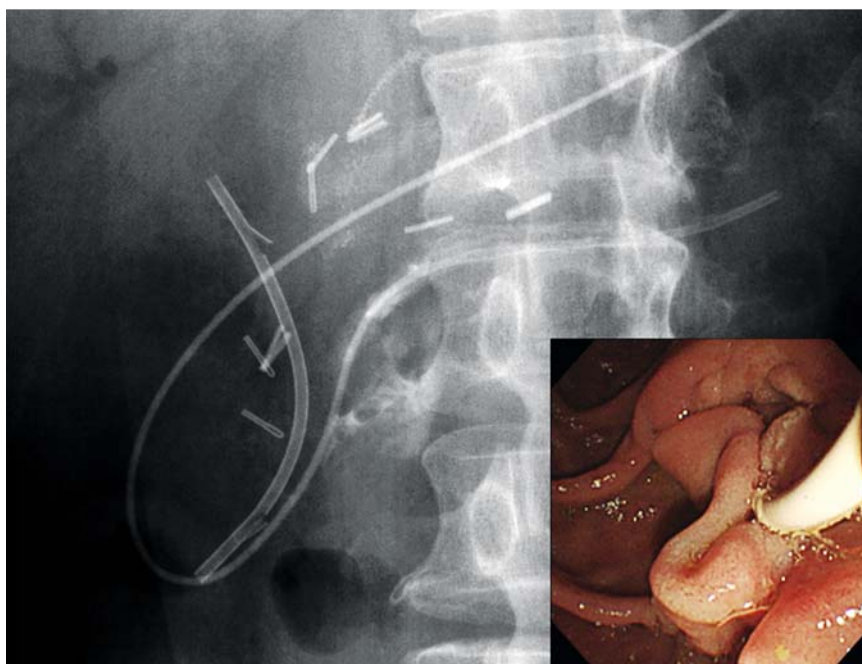


► **Fig. 2** Contrast-enhanced computed tomography 2 days later showed a pancreatic perforation and pancreatic fistula.

Pancreatic stenting is widely used to prevent pancreatitis occurring after endoscopic retrograde cholangiopancreatography (ERCP) [1]. In general, a pancreatic spontaneous dislodgement stent (PSDS) with a duodenal pigtail prevents intraductal migration. Serious adverse events after PSDS placement, such as migration into the portal vein, have been reported [2]. Here, we present a case of pancreatic perforation and fistula caused by a dislocated and migrated PSDS and the technique by which rescue was achieved.



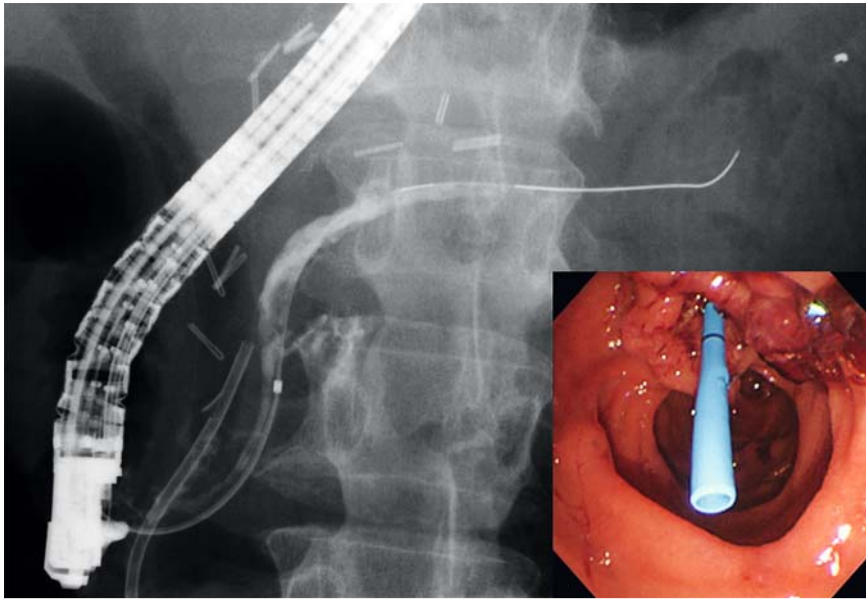
► **Video 1** Endoscopic rescue technique for management of pancreatic perforation and fistula caused by placement of a pancreatic spontaneous dislodgement stent.



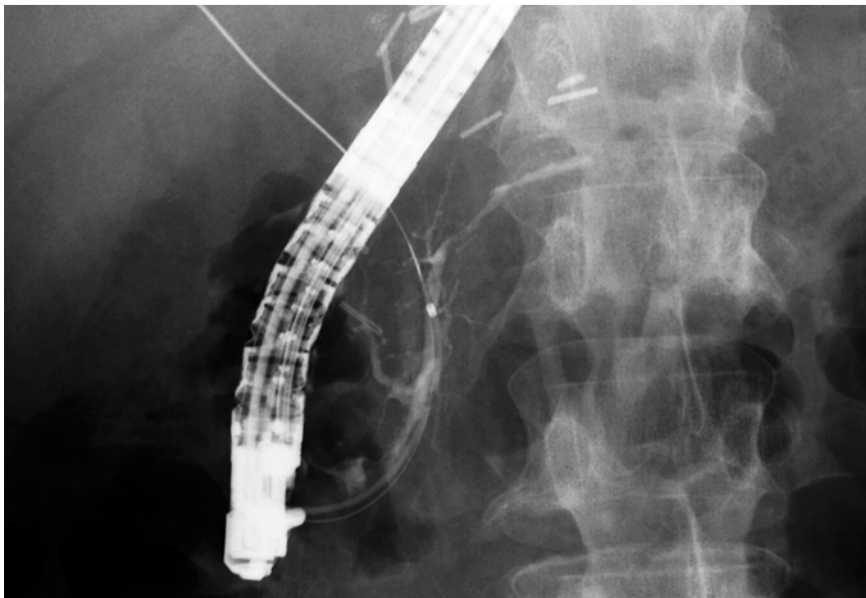
► **Fig. 3** Radiographic view of the pancreatic fistula in the pancreatic head and the 5-Fr naso-pancreatic stent placed across the pancreatic fistula (inset: endoscopic view of the nasopancreatic stent and biliary stent through the ampulla of Vater).

A 58-year-old man with biliary stones after Billroth-I reconstruction for gastric cancer was referred. We performed en-

doscopic stone extraction; however, selective biliary cannulation was difficult. A 7-Fr biliary stent and 5-Fr PSDS (Advanix



► **Fig. 4** Five days later, radiographs still showed the pancreatic fistula (inset: a 5-Fr pancreatic stent was placed across the perforated site).



► **Fig. 5** Three months later, radiographs showed the pancreatic fistula as healed.

pancreatic stent, single pigtail on the duodenal side, unflanged, 5 cm; Boston Scientific Japan, Tokyo, Japan) were placed following transpancreatic sphincterotomy in the first session (► **Fig. 1**; ► **Video 1**). Two days later, the patient suddenly complained of severe exacerbation of abdominal pain and fever. Computed tomography showed pancreatic perforation and fistula caused by PSDS (► **Fig. 2**). A second ERCP was performed, and the PSDS was removed using alligator

forceps. Endoscopic retrograde pancreatography (ERP) confirmed the perforation and fistula, and endoscopic nasopancreatic drainage was placed across the perforated site (► **Fig. 3**; ► **Video 1**). The symptoms immediately improved. Three days later, a third ERCP was performed with successful biliary stone extraction. However, ERP still showed perforation and fistula, and a 7-Fr pancreatic stent (Flexima, straight, double-flanged, 7-cm; Boston Scientific) was placed

(► **Fig. 4**; ► **Video 1**). Two days later, abdominal ultrasound revealed a portal vein thrombus (PVT), and direct oral anticoagulants were administered. One month later the PVT had resolved completely, and after 3 months the perforation and fistula were completely healed (► **Fig. 5**; ► **Video 1**).

When a prophylactic PSDS is placed, the possibility of adverse effects caused by dislocation and inward migration should be taken into account. Although challenging, if perforation and fistula are diagnosed, endoscopists should consider not only stent removal [2] but also immediate pancreatic drainage across the perforated site as a rescue treatment.

Endoscopy\_UCTN\_Code\_CPL\_1AK\_2AC

### Competing interests

The authors declare that they have no conflict of interest.

### The authors

**Hiroshi Kawakami**<sup>1,2</sup>, **Hiroshi Hatada**<sup>1,2</sup>, **Yoshimasa Kubota**<sup>1,2</sup>, **Souichiro Ogawa**<sup>1,2</sup>, **Hotaka Tamura**<sup>1,2</sup>, **Naoki Yoshida**<sup>1,2</sup>, **Naomi Uchiyama**<sup>1,2</sup>

- 1 Division of Gastroenterology and Hepatology, Department of Internal Medicine, Faculty of Medicine, University of Miyazaki, Miyazaki, Japan
- 2 Department of Gastroenterology and Hepatology, Center for Digestive Disease, University of Miyazaki Hospital, Miyazaki, Japan

### Corresponding author

**Hiroshi Kawakami, MD, PhD**

Division of Gastroenterology and Hepatology, Department of Internal Medicine, Faculty of Medicine, University of Miyazaki, 5200, Kihara, Kiyotake, 889-1692 Miyazaki, Japan  
 Fax: +81-985-85-9802  
 hiropon@med.miyazaki-u.ac.jp

## References

- [1] Dumonceau JM, Kapral C, Aabakken L et al. ERCP-related adverse events: European Society of Gastrointestinal Endoscopy (ESGE) Guideline. *Endoscopy* 2020; 52: 127–149
- [2] Leung WD, Parashette KR, Molleston JP et al. Pancreatic stent migration into the portal vein causing portal vein thrombosis: a rare complication of a prophylactic pancreatic stent. *Pancreatology* 2012; 12: 463–465

## Bibliography

*Endoscopy* 2021; 53: E398–E400  
**DOI** 10.1055/a-1314-9818  
**ISSN** 0013-726X  
**published online** 17.12.2020  
© 2020. Thieme. All rights reserved.  
Georg Thieme Verlag KG, Rüdigerstraße 14,  
70469 Stuttgart, Germany

### ENDOSCOPY E-VIDEOS

<https://eref.thieme.de/e-videos>



*Endoscopy E-Videos* is a free access online section, reporting on interesting cases and new techniques in gastroenterological endoscopy. All papers include a high quality video and all contributions are freely accessible online.

This section has its own submission website at  
<https://mc.manuscriptcentral.com/e-videos>