

Diagnostic yield of endoscopic ultrasound-guided tissue acquisition in autoimmune pancreatitis: a systematic review and meta-analysis



Authors

Antonio Facciorusso¹, Luca Barresi², Renato Cannizzaro³, Filippo Antonini⁴, Konstantinos Triantafyllou⁵, Georgios Tziatzios⁵, Nicola Muscatiello¹, Phil A. Hart⁶, Sachin Wani⁷

Institutions

- 1 Endoscopy Unit, University of Foggia, Foggia, Italy
- 2 Endoscopy Service, Department of Diagnostic and Therapeutic Services, Mediterranean Institute for Transplantation and Advanced Specialized Therapies (IRCCS – ISMETT), Palermo, Italy
- 3 Oncological Gastroenterology, Centro di Riferimento Oncologico di Aviano (CRO) IRCCS, Aviano, Italy
- 4 Gastroenterology and Endoscopy Unit, Marche Polytechnic University, A. Murri Hospital, Fermo, Italy
- 5 Hepatogastroenterology Unit, Second Department of Internal Medicine – Propaedeutic, Research Institute and Diabetes Center, Medical School, National and Kapodistrian University of Athens, Athens, Greece
- 6 Division of Gastroenterology, Hepatology, and Nutrition, The Ohio State University Wexner Medical Center, Columbus, Ohio, United States
- 7 University of Colorado Anschutz Medical Campus, Aurora, Colorado, United States

submitted 13.7.2020

accepted after revision 28.9.2020

Bibliography

Endoscopy International Open 2021; 09: E66–E75

DOI 10.1055/a-1293-7279

ISSN 2364-3722

© 2021. The Author(s).

This is an open access article published by Thieme under the terms of the Creative Commons Attribution-NonDerivative-NonCommercial License, permitting copying and reproduction so long as the original work is given appropriate credit. Contents may not be used for commercial purposes, or adapted, remixed, transformed or built upon. (<https://creativecommons.org/licenses/by-nc-nd/4.0/>)

Corresponding author

Antonio Facciorusso, Gastroenterology Unit, Department of Medical Sciences, University of Foggia, AOU Ospedali Riuniti, Viale Pinto, 1, 71100 Foggia, Italy
 Fax: +0039 0881733545
antonio.facciorusso@virgilio.it

Supplementary material is available under <https://doi.org/10.1055/a-1293-7279>

ABSTRACT

Background and study aims There is limited evidence on the diagnostic performance of endoscopic ultrasound (EUS)-guided tissue acquisition in autoimmune pancreatitis (AIP). The aim of this meta-analysis was to provide a pooled estimate of the diagnostic performance of EUS-guided fine-needle aspiration (FNA) and fine-needle biopsy (FNB) in patients with AIP.

Patients and methods Computerized bibliographic search was performed through January 2020. Pooled effects were calculated using a random-effects model by means of DerSimonian and Laird test. Primary endpoint was diagnostic accuracy compared to clinical diagnostic criteria. Additional outcomes were definitive histopathology, pooled rates of adequate material for histological diagnosis, sample adequacy, mean number of needle passes. Diagnostic sensitivity and safety data were also analyzed.

Results Fifteen studies with 631 patients were included, of which four were prospective series and one randomized trial. Overall diagnostic accuracy of EUS tissue acquisition was 54.7% (95% confidence interval, 40.9%–68.4%), with a clear superiority of FNB over FNA (63%, 52.7% to 73.4% versus 45.7%, 26.5%–65%; $p < 0.001$). FNB provided level 1 of histological diagnosis in 44.2% of cases (30.8%–57.5%) as compared to 21.9% (10%–33.7%) with FNA ($P < 0.001$). The rate of definitive histopathology of EUS tissue sampling was 20.7% (12.9%–28.5%) and it was significantly higher with FNB (24.3%, 11.8%–36.8%) as compared to FNA (14.7%, 5.4%–23.9%; $P < 0.001$). Less than 1% of subjects experienced post-procedural acute pancreatitis.

Conclusion The results of this meta-analysis demonstrate that the diagnostic performance of EUS-guided tissue acquisition is modest in patients with AIP, with an improved performance of FNB compared to FNA.

Introduction

Autoimmune pancreatitis (AIP) is increasingly recognized due to improvements in diagnostic modalities and well-established criteria for its diagnosis. Current international consensus diagnostic criteria (ICDC) for the diagnosis of AIP include 5 domains: characteristic imaging of the pancreatic parenchyma and duct, serology, other organ involvement, pancreatic histopathology, and response to steroid trial [1]. There are currently two primary subtypes recognized, which are commonly referred to as type 1 AIP and type 2 AIP. Type 1 AIP represents the pancreas manifestation of a systemic disease referred to as IgG4-related disease, whereas type 2 AIP is a pancreas-specific disorder that is much less commonly encountered [2].

Among these criteria, histology plays an important role in the ICDC as it represents the gold standard for diagnosis. Another key role is to rule out malignant disease in patients with indeterminate imaging features [2].

Since most of the histological features of type 1 AIP (previously described as lymphoplasmacytic sclerosing pancreatitis [LPSP]) [3,4], can be assessed only on core biopsy tissue samples, the role of endoscopic ultrasound (EUS)-guided fine-needle aspiration (FNA) has been questioned in this field and is not included in ICDC as a method for histopathologic diagnosis of AIP, because of the difficulty in obtaining adequate specimens for histopathologic analysis [1,2].

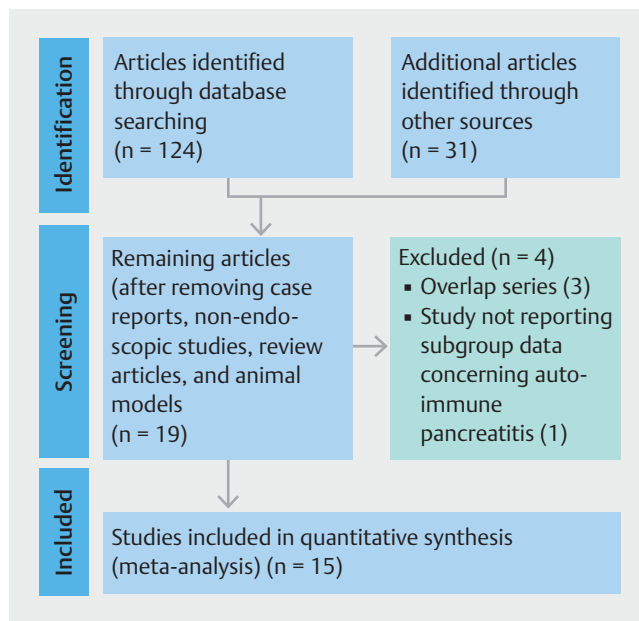
The development of EUS fine-needle biopsy (EUS-FNB) needles has generated a great deal of interest in the field of EUS-tissue acquisition (TA) primarily based on proposed advantages over EUS-FNA needles of improving diagnostic accuracy, improving procurement of samples with preserved tissue architecture and allowing for immunohistochemistry or special stains required for certain diagnoses, including pancreatic cancer and AIP [5].

FNB needles, in particular newer devices with fork-tip design (SharkCore, Medtronic, Minneapolis, Minnesota, United States) or with three symmetric cutting edges (Acquire, Boston Scientific Corp, Natick, Massachusetts, United States), were found to significantly improve the diagnostic yield in patients with pancreatic masses [6, 7] and they showed encouraging results in a preliminary series of AIP patients [8].

Although FNB needles are thought to improve tissue capture, thus increasing the histological accuracy, there is limited evidence on the diagnostic performance of EUS-TA in AIP; hence there is a need to systematically assess the increasing body of evidence in the field in order to better define its role in the diagnostic algorithm of patients with AIP.

The aim of this meta-analysis is to provide a pooled estimate of the diagnostic performance and safety profile of all the available needles for EUS-TA in patients with AIP.

The primary endpoint was diagnostic accuracy compared to diagnostic criteria, which commonly include response to steroid therapy. Additional outcomes were definitive histopathology, pooled rates of adequate material for histological diagnosis according to ICDC histological criteria (level 1 and 2), sample adequacy, mean number of needle passes. Diagnostic sensitivity of FNB needles and safety data were also analyzed.



► Fig. 1 Flowchart of included studies.

Materials and methods

Inclusion and exclusion criteria

Only studies meeting the following criteria were included: 1) articles recruiting >10 patients with AIP undergoing EUS-TA; 2) studies published in English; 3) articles reporting diagnostic accuracy. Case reports, non-endoscopic studies, review articles, and animal models were excluded.

Search strategy

► Fig. 1 shows the search strategy followed in the meta-analysis.

Bibliographic research was conducted on PubMed, EMBASE, Cochrane Library and Google Scholar including all studies fulfilling inclusion criteria published until January 2020. Details of the search strategy adopted are reported in **Supplementary Table 1**.

Relevant reviews and meta-analyses on the use of EUS-TA in patients with AIP were examined for additional eligible studies. Authors of included studies were contacted to obtain full text or further information when needed. Data extraction was conducted by two reviewers (AF and FA) and the quality of included studies was assessed by two authors independently (AF, GT) according to the Cochrane Collaboration's tool for assessing the risk of bias [9] for randomized-controlled trials (RCTs) and the Newcastle-Ottawa scale [10] for non-randomized studies. Disagreements were solved by discussion and following a third opinion (SW).

Outcomes

The primary outcome was diagnostic accuracy, defined as true positive + true negative/total number of patients, where true positive was considered the presence in the tissue sample of

▶ Table 1 Characteristics of included studies.

Study	Needle	Sample size	Study period/Design/Diagnostic criteria	Country	Age	Gender male	IgG4 level (mg/dL)/HPFs required to define sample adequacy	Location of puncture (head/uncinated)	Autoimmune Pancreatitis type	Other organ involvement	Range of pancreatic enlargement (diffuse)/use of ROSE
22G fine-needle aspiration											
Cao 2018 [13]	EchoTip Ultra	27	2013–2017/Prospective/ICDC criteria	China	57 ± 12.3	25 (92.6%)	> 2 × ULN: 17 (63%) 1–2 × ULN: 8 (29.6%)/NR	24 (88.8%)	Type 1: 26 (96.3%)	Cholangitis 13 (48.1%) Sialadenitis 3 (11.1%) Nephritis 1 (3.7%)	13 (48.1%) No
Imai 2011 [14]	EchoTip	21	2003–2009/Retrospective/Japanese criteria	Japan	63 (51–76)	18 (85.7%)	356.2/NR	11 (52.3%)	NR	NR	NR/ No
Ishikawa 2012 [15]	EZ Shot	47	2003–2011/Retrospective/ICDC criteria	Japan	62.1 ± 13.6	42 (89.3%)	626.1 ± 1004.6/NR	21 (44.6%)	Type 1: 39 (82.9%) Type 2: 3 (6.3%)	NR	NR/ No
Kanno 2012 [16]	EchoTip	25	2008–2011/Retrospective/ICDC criteria	Japan	Range: 18–87	22 (88%)	NR/> 10 HPFs	NR	NR	NR	NR/ No
Kanno 2016 [17]	Expect	78	2013–2014/Prospective/ICDC criteria	Japan	65.8 ± 11.1	60 (76.9%)	421 ± 351.2/NR	28 (35.9%)	Type 1: 78 (100%)	Cholangitis 20 (25.6%) Sialoadenitis 28 (35.9%) Nephritis 3 (3.8%)	31 (40.3%) No
Morishima 2016 [18]	NR	50	2011–2014/Prospective/ICDC criteria	Japan	64.4 (22–80)	39 (78%)	> 135: 36 (72%)/NR	NR	Type 1: 41 (82%) Type 2: 4 (8%)	Cholangitis 11 (22%) Sialadenitis 3 (6%) Nephritis 4 (8%)	NR/ No
Other fine-needle aspiration needles											
Khalid 2011 [20]	NR	14	NR/Retrospective/Asian diagnostic criteria	USA	57 ± 17	7 (50%)	2 × ULN: 2 (14.2%)/NR	7 (50%)	NR	NR	NR/ NR
Sugimoto 2020 [21]	19G or 22G FNA Wet Suction vs Dry Suction	11 23	2016–2018/Prospective/ICDC criteria	Japan	62.9 ± 12.4 61 ± 9.6	6 (54.5%) 21 (91.3%)	568 (177–2100) 447 (149–1480)/NR	NR	NR	NR	NR/ No
Fine-needle biopsy											
Iwashita 2012 [19]	19 G EchoTip	44	2004–2010/Retrospective/ICDC criteria	Japan	64 (36–79)	37 (84%)	322 (20–1270)/≥ 5 HPFs	NR	Type 1: 19 (43.1%)	NR	19 (43.1%) No

▶ **Table 1** (Continuation)

Study	Needle	Sample size	Study period/Diagnostic criteria	Country	Age	Gender male	IgG4 level (mg/dL)/HPFs required to define sample adequacy	Location of puncture (head/uncinuated)	Autoimmune Pancreatitis type	Other organ involvement	Range of pancreatic enlargement (diffuse)/use of ROSE
Kurita 2019 [8]	22G Acquire	50	2017–2018/ RCT/ ICDC criteria	Japan	70	40 (73%)	406 (21.5–3440)	18 (36%)	Type 1: 100%	Cholangitis 4 (8%) Sialadenitis 15 (30%) Nephritis 4 (8%) Cholangitis 2 (3.9%) Sialadenitis 19 (37.2%)	32 (58%)
	20G ProCore	51			(21–86) 68 (21–86)	39 (71%)	≥ 1 HPF	9 (18%)	Type 1: 100%		28 (51%) No
Lee 2017 [22] ¹	19G FNB	15	2012–2015/ Retrospective/ NR	Korea	NR	NR	NR/NR	NR	Type 1: 45 (78.9%) Type 2: 6 (10.5%)	NR	NR/ No
	22G ProCore	42			NR	NR	NR	NR	NR	NR	
Tsutsu-mi 2019 [23] ¹	21G SonopsyCY	14	2015–2018/ Retrospective/ ICDC criteria	Japan	71 (50–79)	11 (78.5%)	NR/NR	NR	Type 1: 100%	NR	10 (71%) No
Zator 2018 [24] ¹	19G, 22G or 25G Acquire SharkCore ProCore	29	2012–2017/ Retrospective/ ICDC criteria	USA	54	21 (72%)	>96: 7 (24.1%)/NR	NR	NR	NR	NR/ NR
Fine-needle aspiration or fine-needle biopsy											
Jung 2015 [25]	19G QuickCore in 28 pts	62	2007–2013/ Retrospective/ ICDC criteria	Korea	54.7 ± 15.3	49 (79%)	> 135: 22 (35.5%)/NR	NR	NR	NR	NR/ No
	19G FNA in 3 pts										
Mizuno 2009 [26]	22G FNA in 10 pts	14	1997–2008/ Retrospective cross over/ ICDC criteria	Japan	67 (41–76)	12 (85.7%)	> 135: 10 (71.4%)/NR	NR	NR	NR	NR/ Yes
	25G FNA in 1 pt										
	22G ProCore in 20 pts										

Data are reported as absolute numbers (percentages) or mean (± standard deviation or with interquartile range).

In the case of studies reporting different etiologies of pancreatic disease, only patients with autoimmune pancreatitis were considered.

FNA, fine needle aspiration; HPF, high-power field; ICDC, International Consensus Diagnostic Criteria; NR, not reported; RCT, randomized controlled trial; ROSE, rapid on-site evaluation; ULN: upper limit of normal.

¹ Study published only as a conference abstract.

characteristic pathological features of AIP according to ICDC criteria. Two additional outcomes related to the primary endpoint were the presence of adequate material and characteristic features of type 1 AIP (lymphoplasmacytic infiltration, storiform fibrosis, obliterative phlebitis, and abundant immunoglobulin (IG) G4-positive staining cells [defined as >10 positive cells per high-power field]) as outlined in the histological criteria for ICDC [11], and definitive histopathology (defined as the contribution of histologic findings obtained with EUS-TA to the definitive diagnosis of AIP according to the ICDC when the diagnosis was not possible clinically based on imaging, serology, or other organs involvement).

According to ICDC criteria, level 1 of histological diagnosis for type 1 AIP was defined by the presence of at least three of the aforementioned features of LPSP, level 2 by the presence of two of the above reported features [11].

Other secondary outcomes were sample adequacy (defined as the ability to procure histological samples adequate for interpretation), number of needle passes, and safety. Pooled sensitivity (true positive/true positive + false negative) with FNB needles was also analyzed.

Statistical analysis

Diagnostic outcomes were computed overall and then separately pooled for each TA modality (FNB versus FNA) through a random-effects model based on DerSimonian and Laird test, and summary estimates were expressed in terms of rates and 95% Confidence Interval (CI). The pooled diagnostic outcomes of the two TA modalities (FNB versus FNA) were compared using the bivariate approach [12].

Chi-square and I^2 tests were used for across studies comparison of the percentage of variability attributable to heterogeneity beyond chance. $P < 0.10$ for chi-square test and $I^2 < 20\%$ were interpreted as low-level heterogeneity. Probability of publication bias was assessed using funnel plots and with Begg and Mazumdar's test. Safety data were inconsistently reported, hence they were analyzed descriptively.

Sensitivity analysis was conducted according to the quality of included studies (high versus low), location of the studies (East versus West), study design (prospective versus retrospective), type of publication (full-text versus conference abstract), and restricted to studies enrolling exclusively patients with type-1 AIP.

A subgroup analysis based on several FNA and FNB devices was performed.

All statistical analyses were conducted using OpenMeta [Analyst] software. For all calculations a two-tailed p value of less than 0.05 was considered statistically significant.

Results

Characteristics of included studies

As shown in ► **Fig. 1**, out of 155 studies initially identified, after preliminary exclusion of manuscripts not fulfilling inclusion criteria, 19 potentially relevant articles were examined. Among these studies, four were further excluded because there was

overlap in enrollment or did not report subgroup data concerning autoimmune pancreatitis.

Finally, 15 studies [8, 13–26] with 631 patients were included in the meta-analysis.

The main characteristics of the included studies are reported in ► **Table 1**.

The recruitment period ranged from 1997 to 2018. Five studies [8, 13, 17, 18, 21] were prospective, of which one was a randomized-controlled trial (RCT) [8], and ten were retrospective series [14–16, 19, 20, 22–26]. Six studies tested 22G FNA needles [13–18], one study the 19G FNA needle [19], one study compared wet suction with either 19G and 22G FNA versus dry suction [21], and another series did not specify the FNA device used [20]. FNB was used in six studies [8, 22–26], of which one RCT [8] compared 22G Franseen FNB (Acquire) to 20G FNB needle (ProCore), one study compared 19G FNB to 22G reverse-bevel FNB needle (ProCore) [22], one study tested the 21G FNB (Sonopsy CY) [23], one study compared 19G TruCut (TCB) FNB to 22G FNA [26], and two series merged data obtained with several devices [24, 25]. Three studies were published only as conference abstracts [22–24].

All the included studies were conducted in Asia except two retrospective American series [20, 24] and all comparative studies presented two well-balanced arms in terms of baseline clinical-demographical characteristics (► **Table 1**). Rapid on-site cytological evaluation (ROSE) was not available (or not reported) in the included studies except for a single Japanese series [26].

In 12 studies [8, 13, 15–19, 21, 23–26] the diagnosis achieved with EUS-TA was based on ICDC histologic criteria.

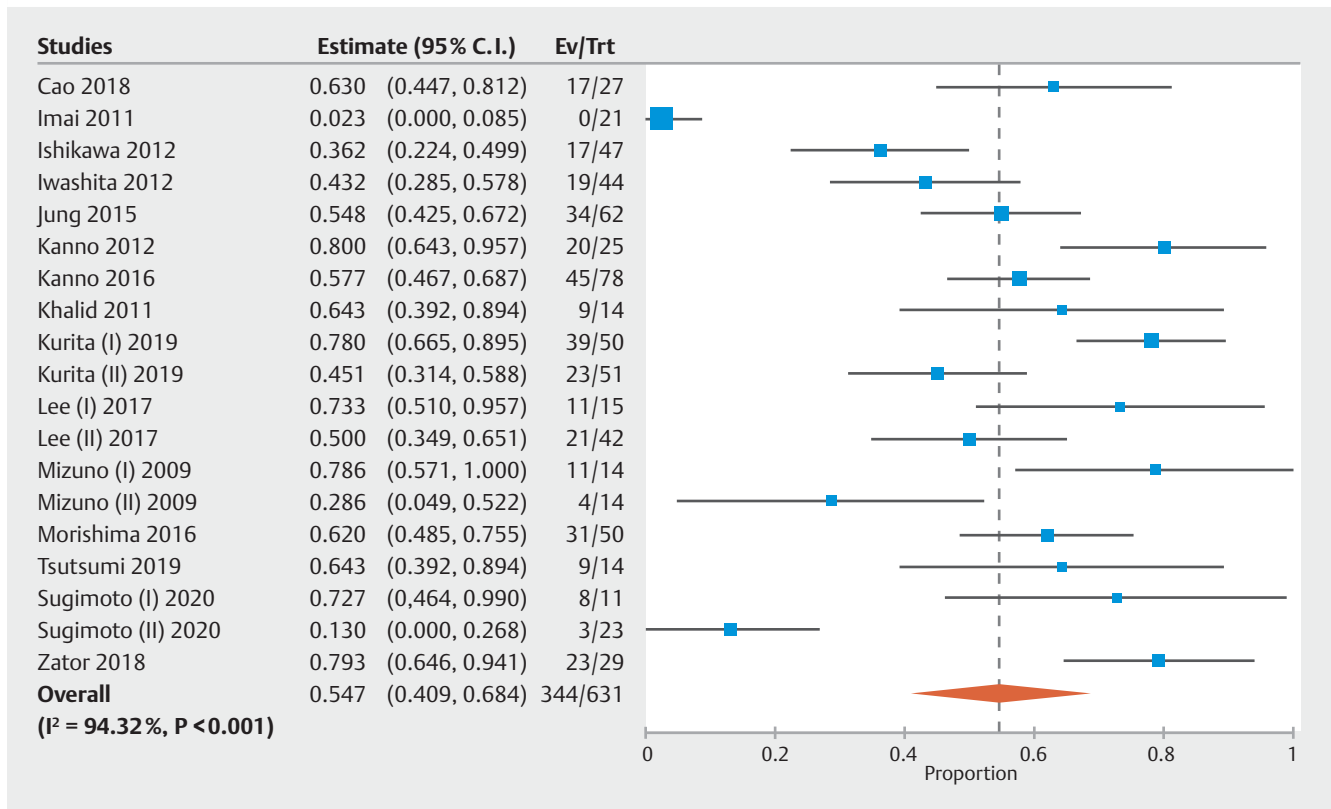
Quality was deemed mainly high with six retrospective studies assessed as low-quality articles [14, 20, 22–25]. Details on methodological characteristics and quality of included articles are shown in **Supplementary Table 2**.

Diagnostic accuracy

As reported in ► **Fig. 1**, ► **Fig. 2** and ► **Table 2**, overall diagnostic accuracy of EUS-TA was 54.7% (95% CI, 40.9%–68.4%; $I^2 = 94.3\%$). Subgroup analysis performed according to the needle used showed a superiority of FNB over FNA (63%, 52.7%–73.4% versus 45.7%, 26.5%–65%; $P < 0.001$). Of note, as reported in ► **Fig. 3** and ► **Table 2**, the high heterogeneity observed in the overall analysis was confirmed within the EUS-FNA group ($I^2 = 94.9\%$) while only moderate heterogeneity was registered in the FNB analysis ($I^2 = 49\%$). Further sub-analysis performed according to the needle design showed higher accuracy with 19G TCB as compared to 22G reverse-bevel needle (68.5%, 55.2%–81.8% versus 58.9%, 39.4%–78.3%), whereas the poorer performance was observed with 19G FNA needle (42.5%, 28.4%–56.6%; ► **Table 2**). There was no evidence of publication bias (data not shown).

A further subanalysis was restricted to studies considering ICDC histological criteria for the diagnosis of AIP, confirming the results of the main analysis (accuracy: 56.8%, 46.4%–67.2%; **Supplementary Figure 1**).

The findings of main analysis were confirmed in sensitivity analysis performed according to study quality (high versus low),



► **Fig. 2** Pooled analysis assessing the diagnostic accuracy of endoscopic ultrasound-guided tissue acquisition in patients with autoimmune pancreatitis. Overall diagnostic accuracy was 54.7% (40.9%–68.4%; $I^2 = 94.3\%$).

design (prospective versus retrospective), location (East versus West), type of publication (full-text versus conference abstract), and restricted to studies enrolling exclusively patients with type-1 AIP (**Supplementary Table 3**). Heterogeneity in the sensitivity analysis was low to moderate (ranging from 2.3% to 55%).

FNB provided level 1 of histological diagnosis according to ICDC criteria in 44.2% of cases (30.8%–57.5%) as compared to 21.9% (10%–33.7%) with FNA ($P < 0.001$; **Supplementary Fig. 2** and **► Table 2**). Additional 16.1% (7.6%–24.6%) and 27.1% (15.5%–38.7%) of patients obtained level 2 of ICDC histological diagnosis with FNB and FNA, respectively (**Supplementary Fig. 2** and **► Table 2**).

As a consequence, FNB provided a rate of definitive histopathology (proportion of patients who could be diagnosed as definitive AIP solely based on the histologic findings obtained with EUS-TA) as high as 24.3% (11.8%–36.8%) as compared to only 14.7% (5.4%–23.9%) with FNA ($P < 0.001$; **► Table 2** and **Supplementary Fig. 3**). Combined, the rate of definitive histopathology of EUS-TA in patients with AIP was 20.7% (12.9%–28.5%) (**► Fig. 4**). Moderate evidence of heterogeneity was observed ($I^2 = 28.6\%$) and no evidence of publication bias was observed, as confirmed with Begg and Mazumdar's test ($P = 0.64$).

Secondary outcomes

Diagnostic sensitivity of FNB needles was 82.7% (63.9%–100%), with high evidence of heterogeneity ($I^2 = 91.6\%$; **Supplementary Fig. 4**).

Sample adequacy was 85.4% (79.3%–91.5%), with evidence of superiority of FNB over FNA (86.3%, 78.2%–94.3% and 77.1%, 64.8%–89.5%, respectively; **► Table 2** and **Supplementary Fig. 5**). However, this finding should be interpreted with caution due to the high heterogeneity observed ($I^2 = 78.4\%$).

Analysis of number of needle passes needed to obtain adequate sample showed favorable results with FNB in comparison to standard FNA (2.79, 1.95–3.62 versus 3.27, 2.68–3.86; $P < 0.001$). Again, as reported in **► Table 2** and **Supplementary Fig. 6**, these findings were weakened by the high heterogeneity ($I^2 = 96.7\%$ in the overall analysis).

Details on safety profile of FNB and FNA needles are reported in **Supplementary Table 4**. Of note, only a small number of patients experienced adverse events and all of these complications (mainly acute pancreatitis) were mild ($n = 6$ with mild acute pancreatitis) and did not impact on patient outcomes.

► Table 2 Overall and subgroup analysis of main diagnostic outcomes. Subgroup analysis was performed based on the needle used. Numbers in parentheses indicate 95% confidence intervals.

Subgroup		No. of Cohorts	No. of patients	Summary Estimate (95% CI)	Within-group heterogeneity (I ²)
Diagnostic accuracy					
Overall		19	631	54.7% (40.9%–68.4%)	94.3%
Fine-needle aspiration		11	321	45.7% (26.5%–65%)	94.9%
Fine-needle biopsy		9	310	63% (52.7%–73.4%)	49%
Needle	19G FNA	2	47	42.5% (28.4%–56.6%)	0%
	22G FNA	8	272	45.1% (21.4%–68.7%)	13.4%
	TruCut	3	57	68.5% (55.2%–81.8%)	19.8%
	22G ProCore®	2	62	58.9% (39.4%–78.3%)	38.7%
Histological Level of Diagnosis					
Level 1	Overall	14	477	31.4% (20.5%–42.3%)	89.6%
	FNA	8	275	21.9% (10%–33.7%)	87%
	FNB	6	202	44.2% (30.8%–57.5%)	28.6%
Level 2	Overall	14	477	22.5% (14.9%–30.2%)	79.7%
	FNA	8	275	27.1% (15.5%–38.7%)	81.2%
	FNB	6	202	16.1% (7.6%–24.6%)	8.1%
Definitive histopathology					
Overall		15	485	20.7% (12.9%–28.5%)	28.6%
Fine-needle aspiration		6	237	14.7% (5.4%–23.9%)	80%
Fine-needle biopsy		6	186	24.3% (11.8%–36.8%)	17.4%
Sample adequacy					
Overall		13	442	85.4% (79.3%–91.5%)	78.4%
Fine-needle aspiration		7	223	77.1% (64.8%–89.5%)	88.5%
Fine-needle biopsy		7	230	86.3% (78.2%–94.3%)	75.6%
Number of needle passes					
Overall		14	477	3.13 (2.68–3.57)	96.7%
Fine-needle aspiration		9	319	3.27 (2.68–3.86)	47.6%
Fine-needle biopsy		4	158	2.79 (1.95–3.62)	48.8%

CI, confidence interval; FNA, fine-needle aspiration; FNB, fine-needle biopsy.

Discussion

The histological diagnosis of AIP represents a challenge for the endoscopist due to the difficulty to obtain adequate core tissue samples. In order to overcome at least partially these limitations and given the pressing need of adequate histological samples for pathology analysis, biopsy needles have been developed and introduced in clinical practice [27].

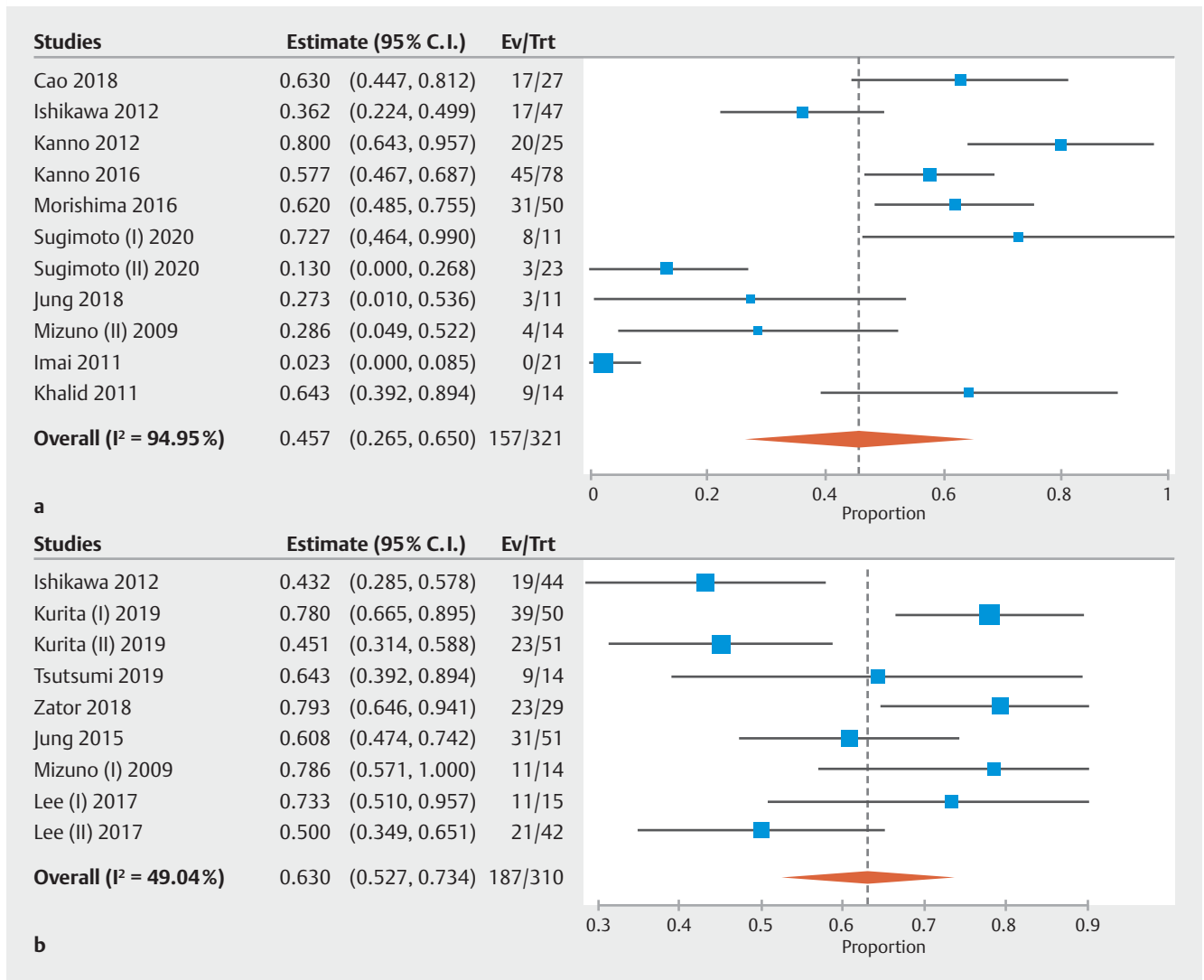
A 19G EUS TCB biopsy needle (Quick-Core, Wilson-Cook, Winston-Salem, North Carolina, United States) appeared to be safe and to be able to provide sufficient histologic specimens to aid in the diagnosis of AIP, thereby guiding treatment and avoiding surgical intervention [26]. However, since the devel-

opment of newer needles (such as reverse-bevel, Franseen, or Fork-Tip device) the use of TCB has been abandoned due to its lack of flexibility and failure of the spring-loading charging mechanism.

As a consequence, the current ICDC guidelines recommend a pancreatic core biopsy in patients presenting with a focal mass and/or obstructive jaundice once cancer has been excluded and the diagnosis remains elusive [11].

Based on these premises, there is a clear need to systematically evaluate the impact of EUS-TA, in particular EUS-FNB, on the diagnosis of AIP.

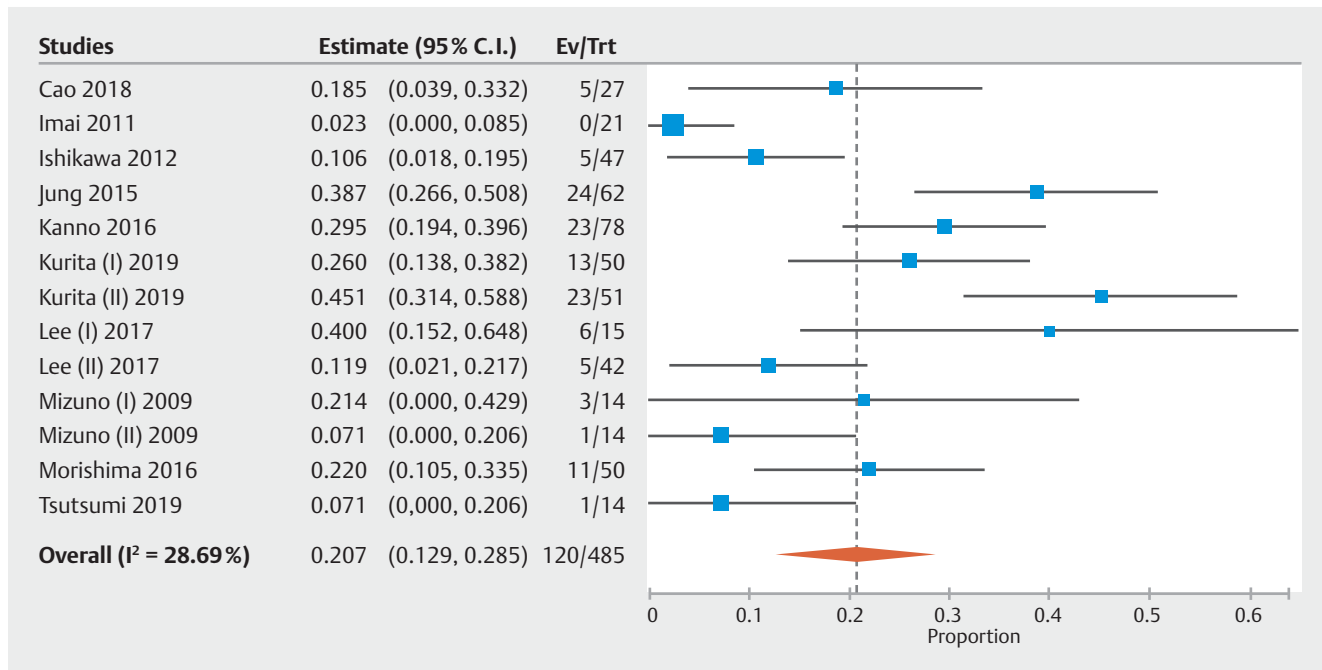
With a meta-analysis of 15 studies we made several key observations.



► **Fig. 3** Pooled analysis assessing rates of diagnostic accuracy achieved with a) fine-needle aspiration and b) fine-needle biopsy. Subgroup analysis performed according to the needle showed a superiority of fine-needle biopsy (FNB) over fine-needle aspiration (FNA) (63%, 95% CI, 52.7% to 73.4% versus 45.7%, 26.5% to 65%; $P < 0.001$). Of note, the high heterogeneity observed in the overall analysis was primarily observed in studies using FNA ($I^2 = 94.95\%$) while only moderate heterogeneity was registered in the FNB analysis ($I^2 = 49\%$).

First, overall diagnostic accuracy of EUS-TA was 54.7%, with a superiority of FNB over FNA. Therefore, as expected, FNB was found to outperform standard FNA in a condition, such as AIP, where achieving a core sample with preserved tissue architecture is of paramount importance. The high heterogeneity observed in the main analysis could be interpreted as due to the different needles used across the included studies. In fact, restricting the analysis only to FNB or to single needles (TCB or reverse-bevel) led to a dramatic decrease in the amount of heterogeneity. Among the several FNB devices, the higher accuracy was observed with 19G TCB although this finding could be due to the higher number of studies supporting its use, hence it should be interpreted with caution. Second, FNB provided higher rates of level 1 (at least 3 histological items satisfied) of histological diagnosis according to ICDC criteria (44.2% as compared to 21.9% with FNA, $P < 0.001$). On the other hand, level 2 of ICDC histological diagnosis was obtained in additional 16.1%

and 27.1% of patients with FNB and FNA, respectively. As a consequence, the contribution of FNB to the definitive diagnosis of AIP in patients who could not be diagnosed based on pancreatic imaging, serum IgG4, or other organ involvement was as high as 24.3% while standard FNA supported the diagnosis of AIP only in 14.7% of patients ($P < 0.001$). Combined, the incremental diagnostic yield of EUS-TA in patients with AIP was 20.7%. Third, sample adequacy was significantly superior with FNB as compared to FNA; however, this finding should be interpreted with caution due to the high heterogeneity observed, likely determined by the different definition of “adequate samples” considered in the included studies. Fourth, as already observed with solid pancreatic masses [6, 7], the number of needle passes needed to obtain adequate sample was significantly lower with FNB in comparison to standard FNA. Finally, EUS-TA is a safe technique with only a very limited number of patients ex-



► **Fig. 4** Pooled analysis assessing the rate of definitive histopathology of endoscopic ultrasound-guided tissue acquisition in patients with autoimmune pancreatitis. Overall, the rate of definitive histopathology of endoscopic ultrasound-guided tissue acquisition was 20.7% (12.9%–28.5%). Moderate evidence of heterogeneity was observed ($I^2 = 28.6\%$).

perceiving mild adverse events when used for the evaluation of AIP.

Our findings should be considered applicable only to type 1 AIP since there were only a few subjects with type 2 AIP in the included studies (a number that was too small to permit subgroup analyses). In many patients with type 1 AIP there is other supportive information (e.g., elevated serum IgG4 levels or other organ involvement), so histologic confirmation is not universally required, but may be particularly helpful when these features are not present. Importantly, histologic diagnosis of type 2 AIP requires visualization of intact pancreatic ducts, which is not always possible. Therefore, the co-occurrence of inflammatory bowel disease and response to steroid therapy are often required to secure the clinical diagnosis of type 2 AIP [28].

Our study demonstrates that the diagnostic performance of endoscopic ultrasound-guided tissue acquisition is modest in patients with type 1 AIP, particularly as compared to solid pancreatic masses [6, 7], although EUS-TA (in particular EUS-FNB) might represent a useful tool in cases where serological or imaging characteristics are non-diagnostic. In fact, EUS-TA was able to provide an unequivocal histological confirmation of diagnosis only in 31.4% of cases (44.2% with FNB and 21.9% with FNA) classified as level 1 (high level of confirmation) according to ICDC criteria.

Obtaining adequate samples to meet the histologic ICDC criteria represents a real challenge for the endoscopist as these criteria are mainly based on findings described on surgical specimens that cannot be easily obtained in even a high-quality biopsy sample. Therefore, in light of the outstanding histologi-

cal performance of the newer generation FNB needles, our results should push the pathologists to reconsider the histologic diagnostic criteria for AIP in order to define more feasible criteria based on FNB samples [29].

There are some limitations to our study. First of all, the limited number of case-control or randomized studies does not allow a strong comparison between FNB, in particular newer needles, and standard FNA. This aspect requires particular caution in interpreting our comparative findings. Second, as mentioned above, the role of EUS-TA specifically related to AIP-2 could not be addressed due to the lack of available studies. Therefore, our results should be considered applicable only to AIP-1 patients. Third, being a benign condition, AIP patients enrolled in the included studies rarely underwent surgery, thus meaning that the gold standard for accuracy analysis (the primary outcome in our study) consisted mainly in the confirmation of diagnosis based on the clinical course during the follow-up or the response to steroid trial. However, when restricted to studies using ICDC (the most widely accepted and rigorous) the results were unchanged, supporting the robustness of these analyses.

Another limitation of the available literature, rather than our analysis, is the lack of studies on the interobserver agreement among the pathologists, an aspect that could have at least in part influenced the final outcomes.

Conclusions

In conclusion, our meta-analysis demonstrates the diagnostic performance of EUS-TA is modest in patients with AIP, with an improved performance of FNB over FNA. Based on the higher

rates of optimal histological core procurement, EUS-FNB may represent a valuable option to provide a definitive diagnosis in those patients who could not be diagnosed solely based on serology or imaging.

Competing interests

Sachin Wani – Consultant for Boston Scientific, Medtronic, Interpace, Cernostics
Sachin Wani – supported by the Department of Medicine Outstanding Early Scholars Program.
The other authors do not have financial ties to disclose.

References

- [1] Fujii-Lau LL, Levy MJ. The role of endoscopic ultrasound in the diagnosis of autoimmune pancreatitis. *Gastrointest Endosc Clin N Am* 2017; 27: 643–655
- [2] Hart PA, Krishna SG, Okazaki K. Diagnosis and management of autoimmune pancreatitis. *Curr Treat Options Gastroenterol* 2017; 15: 538–547
- [3] Kawaguchi K, Koike M, Tsuruta K et al. Lymphoplasmacytic sclerosing pancreatitis with cholangitis: a variant of primary sclerosing cholangitis extensively involving pancreas. *Hum Pathol* 1991; 22: 387–395
- [4] Notohara K, Burgart LJ, Yadav D et al. Idiopathic chronic pancreatitis with periductal lymphoplasmacytic infiltration: clinicopathologic features of 35 cases. *Am J Surg Pathol* 2003; 27: 1119–1127
- [5] Wani S, Muthusamy VR, McGrath CM et al. AGA White Paper: Optimizing Endoscopic Ultrasound-Guided Tissue Acquisition and Future Directions. *Clin Gastroenterol Hepatol* 2018; 16: 318–327
- [6] Facciorusso A, Wani S, Triantafyllou K et al. Comparative accuracy of needle sizes and designs for EUS tissue sampling of solid pancreatic masses: a network meta-analysis. *Gastrointest Endosc* 2019; 90: 893–903
- [7] Facciorusso A, Del Prete V, Buccino VR et al. Diagnostic yield of Franseen and Fork-Tip biopsy needles for endoscopic ultrasound-guided tissue acquisition: a meta-analysis. *Endosc Int Open* 2019; 7: E1221–E1230
- [8] Kurita A, Yasukawa S, Zen Y et al. Comparison of a 22-gauge Franseen-tip needle with a 20-gauge forward-bevel needle for the diagnosis of type 1 autoimmune pancreatitis: a prospective, randomized, controlled, multicenter study (COMPAS study). *Gastrointest Endosc* 2020; 91: 373–381
- [9] Higgins JP, Altman DG, Gøtzsche PC et al. Cochrane Bias Methods Group; Cochrane Statistical Methods Group. The Cochrane Collaboration's tool for assessing risk of bias in randomised trials. *BMJ* 2011; 343: d5928
- [10] Wells GA, Shea B, O'Connell D et al. The Newcastle-Ottawa Scale (NOS) for assessing the quality of nonrandomised studies in meta-analyses. Available from (Accessed on January 2020): http://www.ohri.ca/programs/clinical_epidemiology/oxford.htm
- [11] Shimosegawa T, Chari ST, Frulloni L et al. International consensus diagnostic criteria for autoimmune pancreatitis: guidelines of the International Association of Pancreatology. *Pancreas* 2011; 40: 352–358
- [12] Reitsma JB, Glas AS, Rutjes AW et al. Bivariate analysis of sensitivity and specificity produces informative summary measures in diagnostic reviews. *J Clin Epidemiol* 2005; 58: 982–990
- [13] Cao L, Wang Y, Wang J et al. The role of EUS-guided fine needle aspiration in autoimmune pancreatitis: a single center prospective study. *Scand J Gastroenterol* 2018; 53: 1604–1610
- [14] Imai K, Matsubayashi H, Fukutomi A et al. Endoscopic ultrasonography-guided fine needle aspiration biopsy using 22-gauge needle in diagnosis of autoimmune pancreatitis. *Dig Liver Dis* 2011; 43: 869–874
- [15] Ishikawa T, Itoh A, Kawashima H et al. Endoscopic ultrasound-guided fine needle aspiration in the differentiation of type 1 and type 2 autoimmune pancreatitis. *World J Gastroenterol* 2012; 18: 3883–3888
- [16] Kanno A, Ishida K, Hamada S et al. Diagnosis of autoimmune pancreatitis by EUS-FNA by using a 22-gauge needle based on the International Consensus Diagnostic Criteria. *Gastrointest Endosc* 2012; 76: 594–602
- [17] Kanno A, Masamune A, Fujishima F et al. Diagnosis of autoimmune pancreatitis by EUS-guided FNA using a 22-gauge needle: a prospective multicenter study. *Gastrointest Endosc* 2016; 84: 797–804
- [18] Morishima T, Kawashima H, Ohno E et al. Prospective multicenter study on the usefulness of EUS-guided FNA biopsy for the diagnosis of autoimmune pancreatitis. *Gastrointest Endosc* 2016; 84: 241–248
- [19] Iwashita T, Yasuda I, Doi S et al. Use of samples from endoscopic ultrasound-guided 19-gauge fine-needle aspiration in diagnosis of autoimmune pancreatitis. *Clin Gastroenterol Hepatol* 2012; 10: 316–322
- [20] Khalid A, Dewitt J, Ohori NP et al. EUS-FNA mutational analysis in differentiating autoimmune pancreatitis and pancreatic cancer. *Pancreatology* 2011; 11: 482–486
- [21] Sugimoto M, Takagi T, Suzuki R et al. Can the wet suction technique change the efficacy of endoscopic ultrasound-guided fine-needle aspiration for diagnosing autoimmune pancreatitis type 1? A prospective single-arm study. *World J Clin Cases* 2020; 8: 88–96
- [22] Lee SS, Oh D, Cho DH et al. Comparison of 19G versus 22G reverse side-bevel needles for endoscopic ultrasound-guided pancreatic core biopsy of autoimmune pancreatitis. *Gastrointest Endosc* 2017; 85: AB357–AB358
- [23] Tsutsumi K, Ueki T, Kawahara S et al. Utility of a 21-gauge Menghini type biopsy needle for an endoscopic ultrasound-guided fine needle biopsy for the histopathological diagnosis of autoimmune pancreatitis. *United European Gastroenterol J* 2019; 8S: 510
- [24] Zator ZA, Zhu H, Cui M et al. Small-caliber eus-guided core biopsy needles are a safe and effective means to diagnose autoimmune pancreatitis. *Gastrointest Endosc* 2018; 87: AB454–AB455
- [25] Jung JG, Lee JK, Lee KH et al. Comparison of endoscopic retrograde cholangiopancreatography with papillary biopsy and endoscopic ultrasound-guided pancreatic biopsy in the diagnosis of autoimmune pancreatitis. *Pancreatology* 2015; 15: 259–264
- [26] Mizuno N, Bhatia V, Hosoda W et al. Histological diagnosis of autoimmune pancreatitis using EUS-guided trucut biopsy: a comparison study with EUS-FNA. *J Gastroenterol* 2009; 44: 742–750
- [27] James TW, Baron TH. A comprehensive review of endoscopic ultrasound core biopsy needles. *Expert Rev Med Devices* 2018; 15: 127–135
- [28] Hart PA, Levy MJ, Smyrk TC et al. Clinical profiles and outcomes in idiopathic duct-centric chronic pancreatitis (type 2 autoimmune pancreatitis): the Mayo Clinic experience. *Gut* 2016; 65: 1702–1709
- [29] Barresi L, Tacelli M, Crinò SF et al. Multicentric Italian survey on daily practice for autoimmune pancreatitis: clinical data, diagnosis, treatment, and evolution toward pancreatic insufficiency. *United European Gastroenterol J* 2020; 8: 705–715