

# Lung Sonography in Obstetrics during COVID-19

## Lungensonografie in der Geburtshilfe bei COVID-19



### Authors

Florian Recker<sup>1\*</sup>, Eva Weber<sup>2\*</sup>, Brigitte Strizek<sup>2</sup>, Ulrich Gembruch<sup>2</sup>, Armin Seibel<sup>3</sup>

### Affiliations

- 1 Zentrum für Frauenheilkunde und Geburtshilfe, Universitätsklinikum Bonn, Bonn
- 2 Abteilung für Geburtshilfe und Pränatale Medizin, Universitätsklinikum Bonn, Bonn, Germany
- 3 Abteilung für Anästhesiologie, Intensiv- und Notfallmedizin, Diakonie Klinikum Jung-Stilling, Siegen, Germany

### Key words

obstetrics, lung ultrasound scan, training

### Schlüsselwörter

Geburtshilfe, Lungenultraschall, Ausbildung

received 19. 6. 2020

accepted after revision 26. 7. 2020

### Bibliography

Geburtsh Frauenheilk 2020; 80: 1026–1032


DOI 10.1055/a-1228-4242

ISSN 0016-5751

© 2020. The Author(s). This is an open access article published by Thieme under the terms of the Creative Commons Attribution-NonDerivative-NonCommercial-License, permitting copying and reproduction so long as the original work is given appropriate credit. Contents may not be used for commercial purposes, or adapted, remixed, transformed or built upon. (<https://creativecommons.org/licenses/by-nc-nd/4.0/>)

### Correspondence

Dr. Florian Recker  
Universitätsklinikum Bonn, Zentrum für Geburtshilfe und Frauenheilkunde  
Venusberg Campus 1, 53127 Bonn, Germany  
[florian.recker@ukbonn.de](mailto:florian.recker@ukbonn.de)

 Deutsche Version unter:  
<https://doi.org/10.1055/a-1228-4242>

### ABSTRACT

In the current coronavirus SARS-CoV-2 pandemic, certain patients are becoming seriously ill. Lung pathologies are common, and some patients even go on to develop acute respiratory distress syndrome (ARDS), which requires intubation and artificial respiration of the critically ill patient. Imaging of the lung is absolutely necessary to obtain a diagnosis, assess the course of disease and for treatment. Particularly in gynecology and obstetrics (OBGYN), ultrasound scans of the lung can be a useful additional tool when caring for pregnant patients in the delivery room. As obstetricians use ultrasound imaging a lot in routine clinical practice, in the current pandemic setting, routine prenatal imaging screening could be expanded by the addition of ultrasound scans of the lung. Lung sonography can offer important additional information, particularly in obstetrics where the indications for radiation-emitting imaging are particularly restrictive. If there is a sonographic suspicion of lung involvement, then, depending on the symptoms and the morphological extent of the ultrasound findings, it may be necessary to consider admitting the patient to hospital for close fetal and maternal monitoring.

### ZUSAMMENFASSUNG

In der gegenwärtigen Pandemiesituation des Coronavirus SARS-CoV-2 stellen sich einige Patienten als kritisch krank dar. Häufig treten Lungenpathologien auf, einige Patienten entwickeln sogar ein akutes Atemnotsyndrom (ARDS), das zu einer Intubation und künstlichen Beatmung des kritisch kranken Patienten führt. Die Bildgebung der Lunge ist für die Diagnose, die Beurteilung des Krankheitsverlaufs und die Therapie absolut notwendig. Insbesondere im Bereich der Gynäkologie und Geburtshilfe (OBGYN) kann der Lungenultraschall ein ergänzendes Hilfsmittel für schwangere Patientinnen im Kreißsaal sein. Da Geburtshelfer die Ultraschallbildgebung in ihrer täglichen Routine in hohem Maße nutzen, kann der Lungenultraschall in einer Pandemiesituation die routinemäßige pränatale Bildgebung erweitern. Er kann einen wichtigen zusätzlichen Aspekt bieten, insbesondere im Bereich der Geburtshilfe, wo die Indikationen für eine strahlenemittierende Bildgebung besonders restriktiv sein sollten. Bei sonografischem Verdacht auf eine Beteiligung der Lunge sollte je nach Symptomatik und sonomorphologischem Ausmaß der Befunde

\* contributed equally

eine stationäre Aufnahme mit enger fetaler und mütterlicher Überwachung erwogen werden.

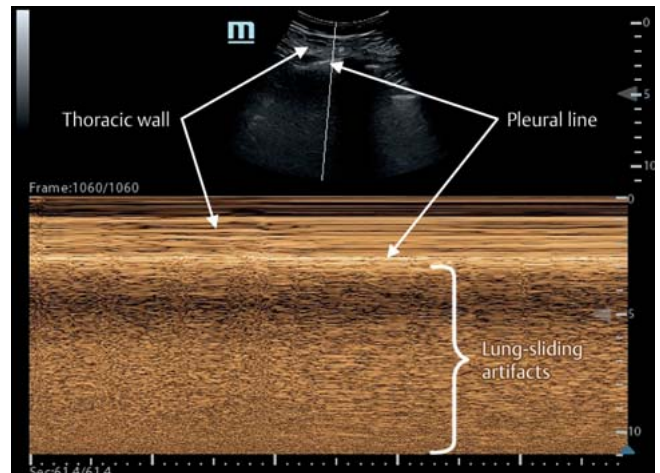
## Background

The new coronavirus (SARS-CoV-2) is a new strain of coronavirus which causes coronavirus disease (COVID-19). It was first diagnosed in 2019 and first identified in Wuhan City, China. Other types of coronavirus infections include colds (HCoV 229E, NL63, OC43 and HKU1), Middle East respiratory syndrome (MERS-CoV) and severe acute respiratory syndrome (SARS-CoV).

Most cases with COVID-19 worldwide indicate transmission through human-to-human contacts. The virus can easily be isolated from respiratory secretions and in feces.

As regards vertical transmission, a number of case reports from China have come to the conclusion that there are currently no indications for such a form of transmission [1–5]. However, based on current information, it is not possible to exclude the possibility that the fetus will be exposed to COVID-19 infection during pregnancy [6]. In a case series published by Chen et al. [5], amniotic fluid, umbilical cord blood, neonatal throat swabs, and breast milk samples from mothers infected with COVID-19 were tested, and all samples tested negative for the virus. Based on the currently available data, it can be assumed that pregnancy will make the clinical course of COVID-19 infection even more complicated and is likely to be associated with higher mortality rates. Similarly, it is currently assumed that in utero transmission from mother to fetus is unlikely. Breastfeeding is permissible if maternal infection has been excluded or as soon as the patient has been verifiably cured [7].

However, pregnant women can develop symptomatic respiratory tract infections, meaning that examination of the lungs should form part of the clinical examination. A large case series from China with 1014 patients has indicated that in cases with a suspicion of infection, CT scan of the chest should be carried out as the imaging modality of choice in preference to PCR because of the higher sensitivity of CT for COVID-19 infection [8]. However, CT in particular is associated with radiation exposure, which should be avoided for pregnant patients whenever possible [9]. In a comparative study of COVID-19 patients, Huang et al. were able to show that radiological CT findings could be reproduced very well with lung sonography [10]. The radiation exposure occurring in the context of low-dose CT corresponds roughly to that generated during conventional thoracic imaging [11]. Ultrasonography of the lung may therefore offer an especial diagnostic benefit when evaluating the lungs of pregnant women. It should also be noted that lung sonography provided in the context of point-of-care ultrasound (POCUS) without any special additional technical features can be a useful clinical tool. Obstetricians/gynecologists (OB/GYN) use sonography in their daily clinical practice; an ultrasound scan of the lung performed just after an obstetric ultrasound scan could thus be easily carried out by obstetricians or gynecologists, even if it only serves to ascertain the presence or absence of normal findings or highlight the need for further specialist medical care [12].



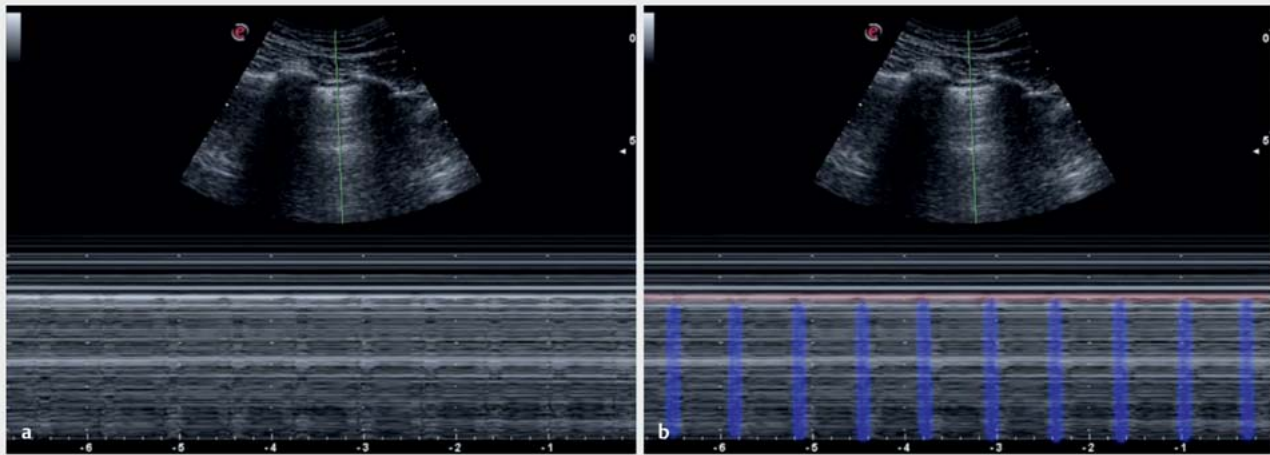
► Fig. 1 Imaging of normal lung sliding in M-mode: seashore sign.

The main presentation of COVID-19 is interstitial lung pathologies, which may culminate in acute respiratory distress syndrome (ARDS). Imaging, which usually takes the form of a CT scan of the chest, is necessary to obtain the diagnosis, evaluate the course of disease and guide the treatment [8]. The most recently published recommendations on the intensive medical care of patients with COVID-19 issued by German professional societies for intensive medical care state that bedside examinations (ultrasound) are preferable [13]. The German Society for Ultrasound in Medicine (DEGUM) has developed a structured lung ultrasound protocol which covers this type of examination [14].

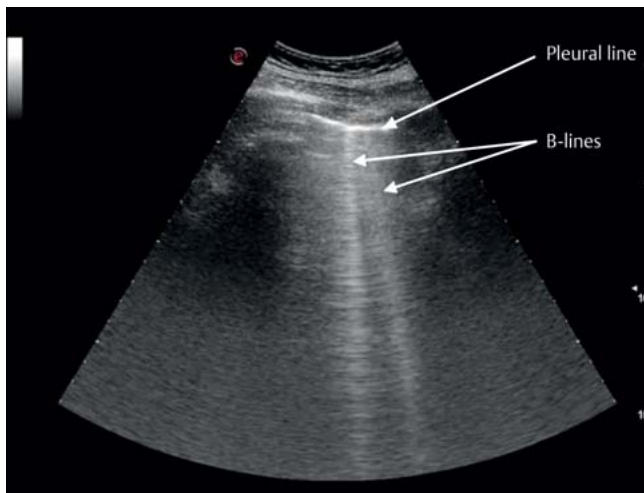
## Basic Principles of Lung Sonography

Conventional sonography uses cross-sectional B-mode imaging to create a 2-dimensional image of tissue structures. In contrast, lung sonography is primarily useful because it generates typical artifacts. These artifacts are created by the impact of ultrasound waves on lungs filled more or less with air. They can be used in addition to characteristic morphological findings on ultrasound to obtain a sonographic differential diagnosis. These artifacts include:

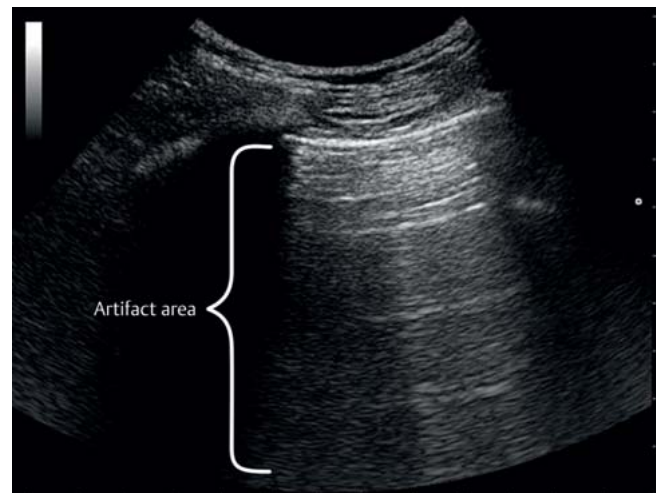
- lung sliding (normal finding created by the to-and-fro movement of pleural layers in synchrony with respiration. Visible in M-mode as a seashore sign ► Fig. 1.)
- lung pulse (normal finding created by mechanical transfer of the heartbeat and arterial pulse waves to the pulmonary arteries. Visible in M-Mode ► Fig. 2.)
- lung point (pathological finding specific to a diagnosis of pneumothorax)
- B-lines (hyperechoic narrow vertical artifact lines created by minute pleural edemas; they are normal if they only occur oc-



► **Fig. 2** Imaging of lung pulse in M-mode. The vertical movement artifacts of the heartbeat (b, blue) only start at the pleural line (b, red). Artifact lines which start above the pleural line must not be falsely interpreted as a lung pulse.



► **Fig. 3** B-lines are defined as laser-like hyperechoic vertical artifact lines extending from the pleural line to the end of the sonogram which move in synchrony with lung sliding. They appear at selected pleural interfaces between liquid-filled and adjacent air-filled alveoli or between edematous interlobular septa and alveolar air.



► **Fig. 4** Reverberations are multiple repeat echoes of the structures of the thoracic wall which are visible in the area below the pleural line. At this depth, these horizontal reverberation lines below the pleural line do not represent reflections of real structures but are merely artifacts, as the ultrasound waves have already been completely reflected by the pleural air.

asionally, but repeated occurrence is an indication of pathological pleural fluid accumulation ► **Fig. 3**)

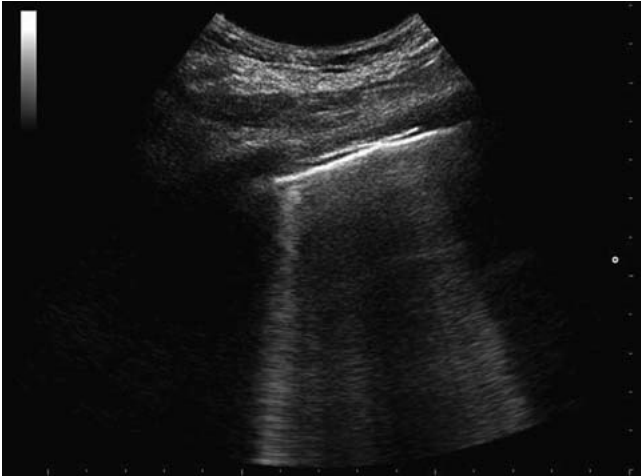- reverberation artifacts (normal finding created by the total reflection of the ultrasound waves on impact with air ► **Fig. 4**)
- pleural effusions
- pleural lung consolidations (infiltrates, atelectasis)

## Lung Sonography Findings in COVID-19

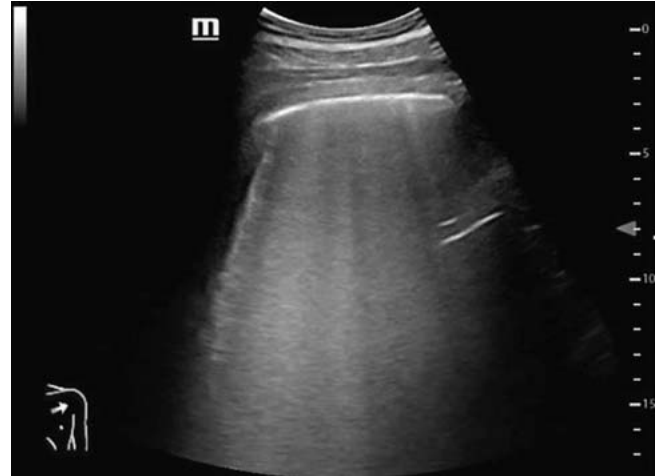CT examinations only rarely show central pulmonary infiltrates in the pulmonary manifestations of COVID-19. It is assumed that the reason why the majority of pathologies present on the periphery

of the lungs is because of the tiny size of the SARS-CoV-2 virus. The structural changes which occur over the course of disease lead to progressive displacement of pleural alveolar air in affected areas of the lung. Lung sonography can be used to identify artifact-based morphological correlates of the various stages of decreased pleural aeration. Such lung ultrasound findings include [15]:

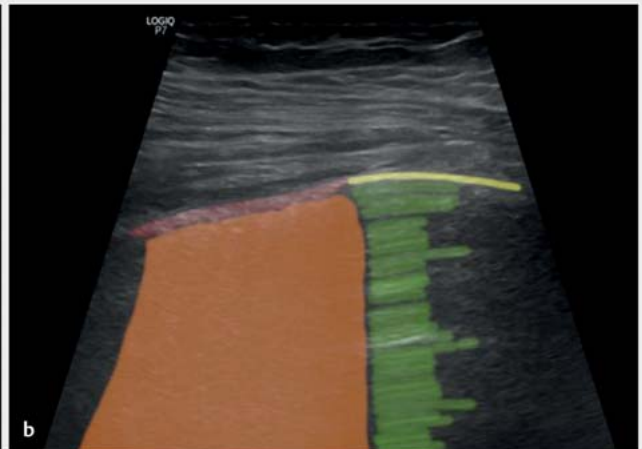
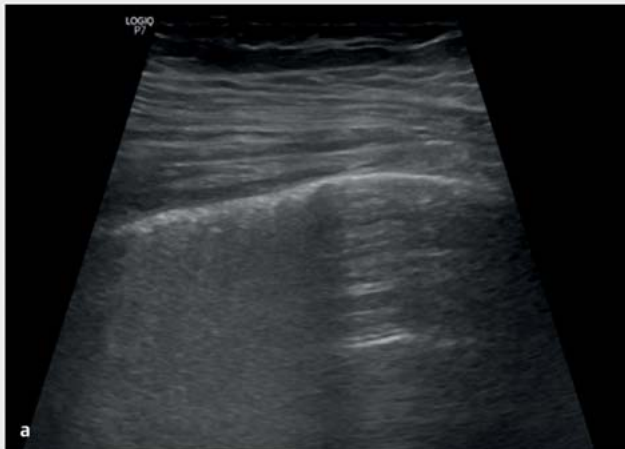- multiple focal or confluent B-lines (► **Figs. 5 and 6**)
- focal thickening, irregularities and fragmentation of the pleural line (► **Figs. 7 and 8**)
- pleural thickening of varying thicknesses (consolidations) (► **Fig. 9**)



► **Fig. 5** Multiple B-lines. The occurrence of more than two B-lines within a single intercostal space is referred to as multiple B-lines. Multiple B-lines develop when there is increased fluid accumulation in the pleural space. This may be due to external causes (cardiac, neurogenic or toxic) or to focal issues within the lung.



► **Fig. 6** Confluent B-lines. As the amount of pleural fluid increases, the individual B-lines increasingly begin to merge until the individual artifact lines can no longer be differentiated from one another. The resulting ultrasound image is that of a white lung.



► **Fig. 7** Thickened pleura. Inflammatory reactions located directly in the pleural space reduce the amount of alveolar air, resulting in a loss of contrast on the ultrasound imaging of the pleural line. The pleural line presents as a thickened, low-contrast line. This image shows typical findings for local limited pleural inflammation, with a thicker fuzzy pleural line (red) directly next to a normal area with a narrow, clearly contoured pleural line (yellow). Reverberations (green) are only visible below the pleural line in the normal area. This constellation is also found in COVID-19 patients in the early stages of disease.

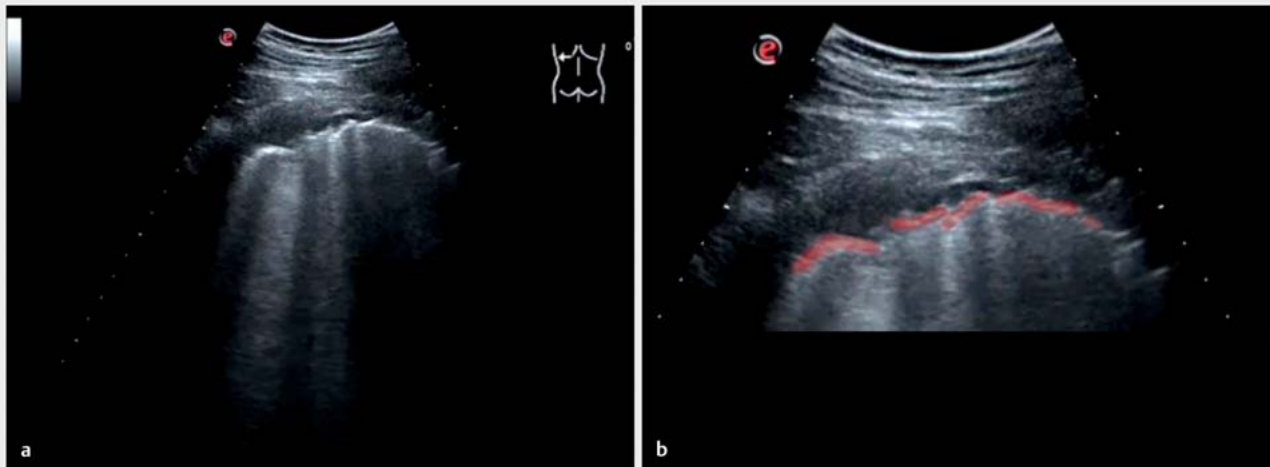
- irregular involvement of various adjacent pleural sections, alongside (still) normal areas
- large pleural effusions are rare; most likely are small effusions in the contact angle (in the absence of other pathologies).

indicate improved responsiveness to prone positioning; changes in the succession of B-lines can be used to adapt the patient's ventilation.

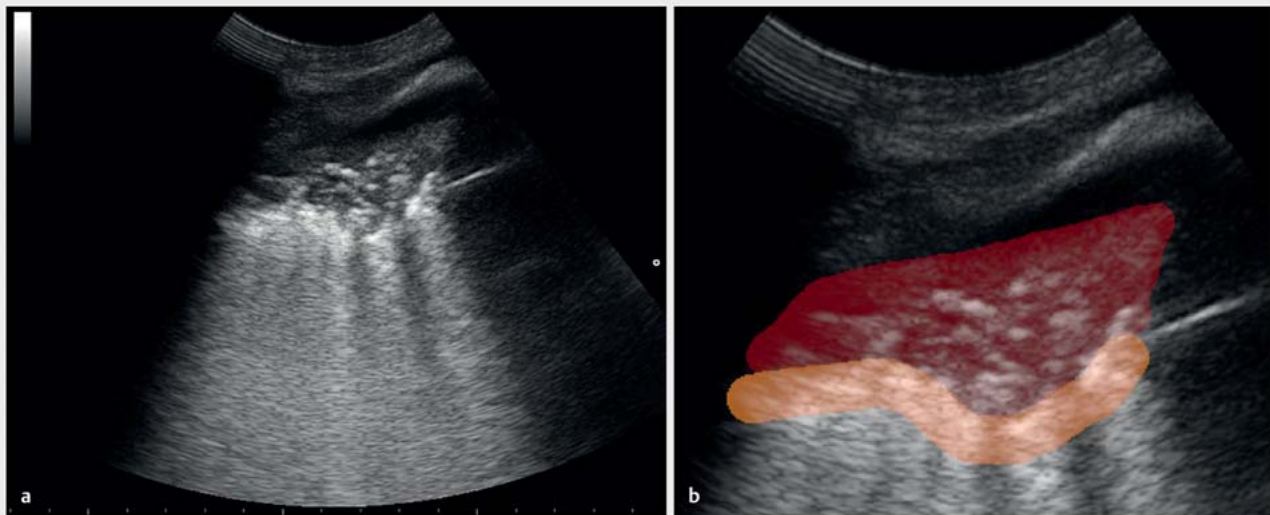
Imaging can be used to track the course of disease. The severity and course of the ventilatory disorder can be closely monitored, with imaging showing both deterioration (increases in the number and density of B-lines, confluence; consolidation) and improvement. Posterior basal changes in ventilated patients can in-

### Lung Consolidations in COVID-19

The pathological mechanism triggered by the intracellular replication of SARS-CoV-2 results in the destruction of affected cells. In the lung, this leads to a loss of structural alveolar integrity. The affected alveoli either become filled with interstitial fluid or col-



► **Fig. 8** Irregular fragmented pleura. As the inflammation in peripheral lung tissue increases, the resulting decrease in alveolar air is spread unevenly. The visceral pleura in these areas can no longer be visualized on ultrasound without optical amplification of the air normally found in the pleural space. The image (b) clearly shows the interruptions to the pleural line (red).



► **Fig. 9** Consolidations and air bronchogram. The image shows a large area of impaired pulmonary gas exchange (b, red). The hyperechoic punctiform artifacts in the consolidation area are referred to as air bronchograms and are created by minute remaining pockets of alveolar and bronchiolar air. No pleural line above the consolidation is visible on imaging. The orange line marks the border between the consolidation and (still) ventilated lung parenchyma.

lapse. As in COVID-19 these pulmonary areas are often found in the subpleural space, even small amounts of fluid accumulation in the alveoli can result in the above-mentioned characteristic changes to the pleura and the increased visibility of B-lines on imaging (► **Figs. 5 to 8**). As the disease progresses, the problem of adequate gas exchange increases (► **Table 1**). The loss of alveolar air increases the density of the lung parenchyma more and more until, in the end-stage, the consistency of the lung tissue in the affected areas becomes that of a firm organ which can be as-

essed by ultrasound imaging just like any other organ (e.g. the liver).

The developmental stages of such consolidations can be evaluated very well on ultrasound scans, based on the amount of residual air in the alveoli, the so-called air bronchogram (► **Fig. 9**). In the early consolidation stages, the extent of the consolidation and the intensity of the air bronchograms still vary considerably, depending on the respiratory movement of the lungs [16]. As the disease progresses, the dynamic respiratory response continually decreases, which is an indication of an unfavorable prognosis.

► **Table 1** Time line and pathophysiological development of typical lung sonography findings in COVID-19.

|  | Stage of inflammatory response | Symptoms   | Typical with COVID-19 | Typical for COVID-19 |
|--|--------------------------------|--|-----------------------|----------------------|
| Focal B-lines  | early                          | none, poss. unspecific feeling of malaise with a dry cough and fever | yes                   | no                   |
| Regional thickening of the pleural line                      | early                          | in addition, first signs of hypoxia without dyspnea                  | yes                   | no                   |
| Fragmented pleural line                                      | advanced                       | additional dyspnea   | yes                   | no                   |
| Regional pleural consolidations                              | advanced                       | in addition, first signs of respiratory insufficiency                | yes                   | no                   |
| Limited air bronchogram                                      | advanced                       |  | yes                   | no                   |
| Widespread, large consolidation areas with reduced perfusion | acute                          | additional somnolence, acute respiratory insufficiency               | yes                   | yes                  |

## Pleural Effusions in COVID-19

The traditional aim of lung ultrasound scans is to evaluate the extent of pleural effusions. Some obstetricians/gynecologists are experienced in recognizing effusions in clinical practice, as certain complications of pregnancy and gynecological cancers may result in the development of effusions. In general, pleural effusions are either simply and uniformly anechoic or complicated by the presence of blood, pus, fibrin and/or septa [17].

The description of the developmental stages of disease refers to individual inflammatory foci and not to the overall development of disease. The described symptoms must therefore be evaluated based on the number of areas in the lungs which are affected. Only pronounced and widespread consolidations with reduced perfusion have not been previously reported for other lung diseases and must therefore, based on current knowledge, be interpreted as typical *for* COVID-19. Although all the other findings are completely typical *with* COVID-19, in principle they can also occur with other pulmonary diseases. While that limits the sensitivity of lung sonography for the diagnosis of COVID-19 on the one hand, on the other hand if the specificity is high, it can be used to exclude COVID-19 [18].

## Lung Sonography in Clinical Practice

### Choice of transducer

Ultrasound examination of the lungs can be carried out using a convex, linear or sector transducer, depending on the problem requiring clinical evaluation. In practice, a convex transducer with a penetration depth of 7–14 cm has been found to be generally suitable for carrying out ultrasound scans of the lungs, as convex transducers can visualize both structures which are close to the surface and underlying deeper structures with sufficient resolution. A linear transducer with high frequencies and a limited penetration depth (4–7 cm) is useful when carrying out more targeted examinations to obtain a more precise assessment of the pleura and of pleural lung consolidations.

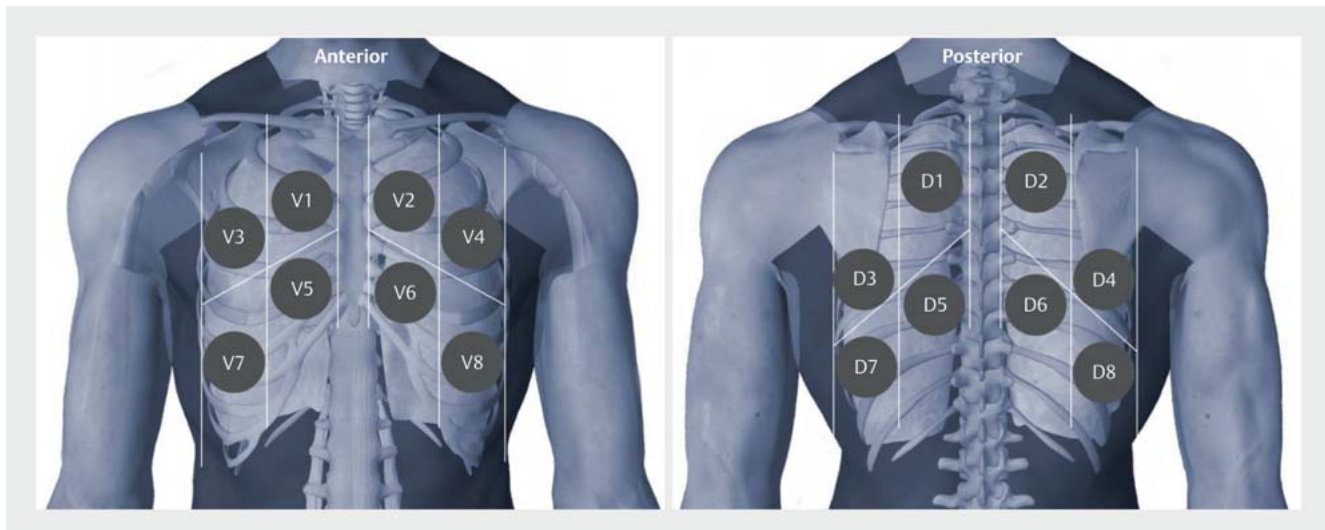
### Examination setting in the delivery room and during the preliminary examination

Lung sonography is an expansion of the obstetric ultrasound scans carried out in the delivery room. Ultrasound scans of the lung performed in this setting should be carried out by obstetricians with ultrasound experience [12]. Lung sonography can also be carried out by trained midwives when the patient is admitted. The examination should be done either when the patient is admitted to the delivery room or when the patient presents to an outpatient pregnancy clinic. Lung sonography can be carried out during the preliminary clinical examination or when carrying out fetal biometry and should be specifically carried out if patients are symptomatic. The examiner can simply move the transducer from the abdomen to the chest area and scan the anterior, lateral and posterior basal lung segments. The examination must cover all parts of the lungs, from the basal to the apical zone of the thorax. To do this, the anterior and posterior thorax should be systematically divided into eight different areas for examination (► **Fig. 10**). Examining only one area does not serve any useful purpose.

## Conclusion

Respiratory failure caused by COVID-19 is a potentially life-threatening situation for every patient, and patients must be examined as quickly as possible to obtain a differential diagnosis. Lung sonography can play an important role in providing additional information during prenatal screening, as the guidelines on radiation exposure during pregnancy are particularly restrictive. Depending on the symptoms and the morphological extent of the ultrasound findings, if the ultrasound examination shows lung involvement, the patient should be admitted to hospital for close fetal and maternal monitoring as accurate information about the course of COVID-19 infection in pregnant women is still lacking [19].

We have proposed a systematic approach with documentation to allow obstetricians/gynecologists to carry out lung ultrasound scans in pregnant women and have given a description of potential applications and symptoms and the practical aspects which need to be considered. Pathological ultrasound patterns should be compared with the ultrasound patterns expected in a normal



► **Fig. 10** Anterior and posterior thoracic areas for examination. The posterior areas D3 – D8 are the most important points to screen if the patient is suspected of having COVID-19.

lung, with a particular focus on findings which may indicate infection with COVID-19.

### Conflict of Interest

The authors declare that they have no conflict of interest.

### References

- [1] Chen H, Guo J, Wang C et al. Clinical characteristics and intrauterine vertical transmission potential of COVID-19 infection in nine pregnant women: a retrospective review of medical records. *Lancet* 2020; 395: 809–815
- [2] Fan C, Lei D, Fang C et al. Perinatal Transmission of COVID-19 Associated SARS-CoV-2: Should We Worry? *Clin Infect Dis* 2020. doi:10.1093/cid/ciaa226
- [3] Li N, Han L, Peng M et al. Maternal and neonatal outcomes of pregnant women with COVID-19 pneumonia: a case-control study. *Infectious Diseases (except HIV/AIDS)*. 03/2020. Online: <http://medrxiv.org/lookup/doi/doi:10.1101/2020.03.10.20033605>; last access: 25.03.2020
- [4] Chen Y, Peng H, Wang L et al. Infants Born to Mothers With a New Coronavirus (COVID-19). *Front Pediatr* 2020; 8: 104
- [5] Zhu H, Wang L, Fang C et al. Clinical analysis of 10 neonates born to mothers with 2019-nCoV pneumonia. *Transl Pediatr* 2020; 9: 51–60
- [6] Dong L, Tian J, He S et al. Possible Vertical Transmission of SARS-CoV-2 From an Infected Mother to Her Newborn. *JAMA* 2020; 323: 1846–1848
- [7] Stumpfe FM, Titzmann A, Schneider MO et al. SARS-CoV-2 Infection in Pregnancy – a Review of the Current Literature and Possible Impact on Maternal and Neonatal Outcome. *Geburtshilfe Frauenheilkd* 2020; 80: 380–390
- [8] Bernheim A, Mei X, Huang M et al. Chest CT Findings in Coronavirus Disease-19 (COVID-19): Relationship to Duration of Infection. *Radiology* 2020; 295: 200463. doi:10.1148/radiol.2020200463
- [9] Gargani L, Picano E. The risk of cumulative radiation exposure in chest imaging and the advantage of bedside ultrasound. *Crit Ultrasound J* 2015; 7: 4
- [10] Huang Y, Wang S, Liu Y et al. A Preliminary Study on the Ultrasonic Manifestations of Peripulmonary Lesions of Non-Critical Novel Coronavirus Pneumonia (COVID-19). *SSRN Electron J*. 2020. Online: <https://www.ssrn.com/abstract=3544750>; last access: 31.03.2020
- [11] Agostini A, Floridi C, Borgheresi A et al. Proposal of a low-dose, long-pitch, dual-source chest CT protocol on third-generation dual-source CT using a tin filter for spectral shaping at 100 kVp for Coronavirus Disease 2019 (COVID-19) patients: a feasibility study. *Radiol Med* 2020; 125: 365–373
- [12] Inchingolo R, Smargiassi A, Mormile F et al. Look at the lung: can chest ultrasonography be useful in pregnancy? *Multidiscip Respir Med* 2014; 9: 32
- [13] Kluge S, Janssens U, Welte T et al. Empfehlungen zur intensivmedizinischen Therapie von Patienten mit COVID-19. *Med Klin – Intensivmed Notfallmedizin*. 12.03.2020. Online: <http://link.springer.com/10.1007/s00063-020-00674-3>; last access: 28.03.2020
- [14] Stock K, Horn R, Mathis G. DEGUM/ÖGUM/SGUM: Lungultraschall-Protokoll. 2020. Online: [https://www.degum.de/fileadmin/dokumente/service/Downloads/Poster\\_A4-Lungultraschall-Protokoll\\_DEGUM\\_SGUM\\_OEGM\\_V3\\_06042020\\_Print\\_digital\\_NEU.pdf](https://www.degum.de/fileadmin/dokumente/service/Downloads/Poster_A4-Lungultraschall-Protokoll_DEGUM_SGUM_OEGM_V3_06042020_Print_digital_NEU.pdf); last access: 19.06.2020
- [15] Peng QY, Wang XT, Zhang LN; Chinese Critical Care Ultrasound Study Group (CCUSG). Findings of lung ultrasonography of novel corona virus pneumonia during the 2019–2020 epidemic. *Intensive Care Med* 2020; 46: 849–850
- [16] Lichtenstein D, Mezière G, Seitz J. The Dynamic Air Bronchogram. *Chest* 2009; 135: 1421–1425
- [17] Brogi E, Gargani L, Bignami E et al. Thoracic ultrasound for pleural effusion in the intensive care unit: a narrative review from diagnosis to treatment. *Crit Care* 2017; 21: 325
- [18] Bar S, Lecourtois A, Diouf M et al. The association of lung ultrasound images with COVID-19 infection in an emergency room cohort. *Anaesthesia* 2020. doi:10.1111/anae.15175
- [19] Dashraath P, Wong JL, Lim MXK et al. Coronavirus disease 2019 (COVID-19) pandemic and pregnancy. *Am J Obstet Gynecol* 2020; 222: 521–531