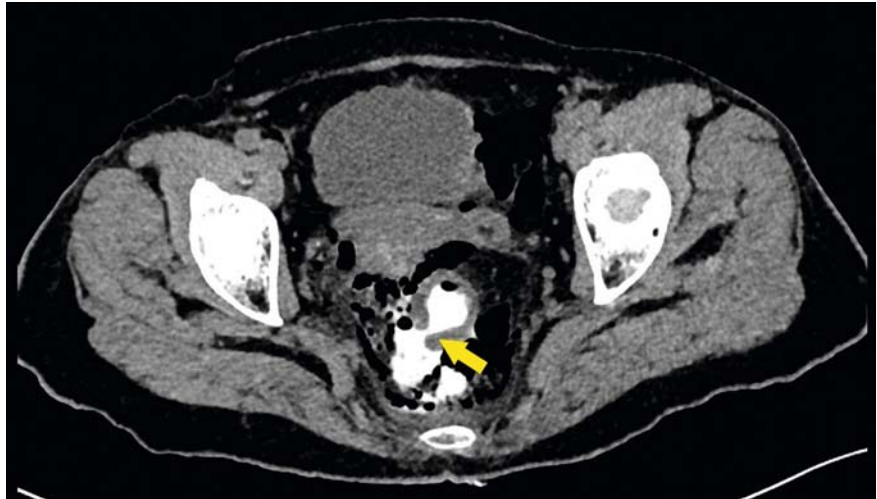

Endoscopic closure of a perforated rectum with an over-the-scope clip following diagnostic colonoscopy

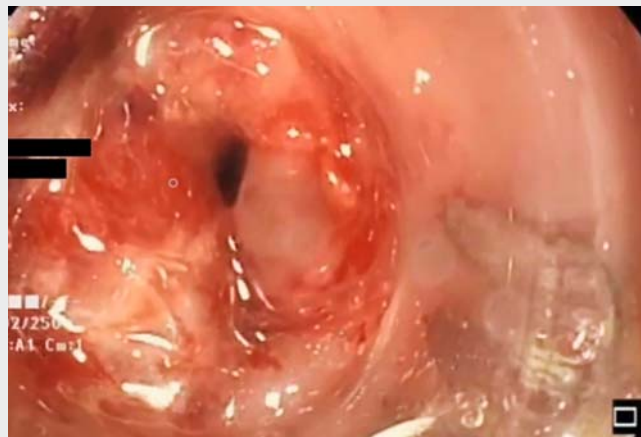Our patient is a 77-year-old-woman who underwent colonoscopy for rectal bleeding which revealed hemorrhoids. A day after the colonoscopy, the patient attended our hospital's emergency room with severe lower abdominal pain. Computed tomography (CT) with rectal contrast revealed free air and extravasation of the contrast material into the abdominal cavity (► **Fig. 1**). As there was no abscess nor ascites, after discussion with general surgeons endoscopic closure of the perforation was decided upon.

During colonoscopy, the perforation of the rectum was confirmed but no edematous swellings or ulcerations were seen. Two endoclips were used but failed to close the perforation. A decision was therefore made to proceed with an over-the-scope clip (OTSC, 12/6 t; Ovesco, Tübingen, Germany) in order to achieve secure closure of the defect. Following suctioning of the perforated area into the cap of the endoscope, the clip was released and the perforation repaired successfully (► **Video 1**). Closure was confirmed by postcolonoscopy CT (► **Fig. 2**). The patient was hospitalized and received intravenous antibiotics for 2 days. She had no complications and was discharged with a prescription for oral antibiotics.

Delayed perforation after colonoscopy requires emergency surgery. In this case, the early detection of the perforation by CT made endoscopic treatment possible. A literature review of endoclips for the closure of acute iatrogenic perforations reported that endoclips are efficient in the management of iatrogenic perforations, especially when recognized early, although their efficiency may be limited in the case of large perforations [1]. In a randomized controlled porcine study, it was shown that an OTSC allows full-thickness closure of perforations [2]. The opposition forces of the OTSC provide strong securing which could be regarded



► **Fig. 1** CT of the pelvis with rectal contrast, showing free air and extravasation of the contrast (arrow).



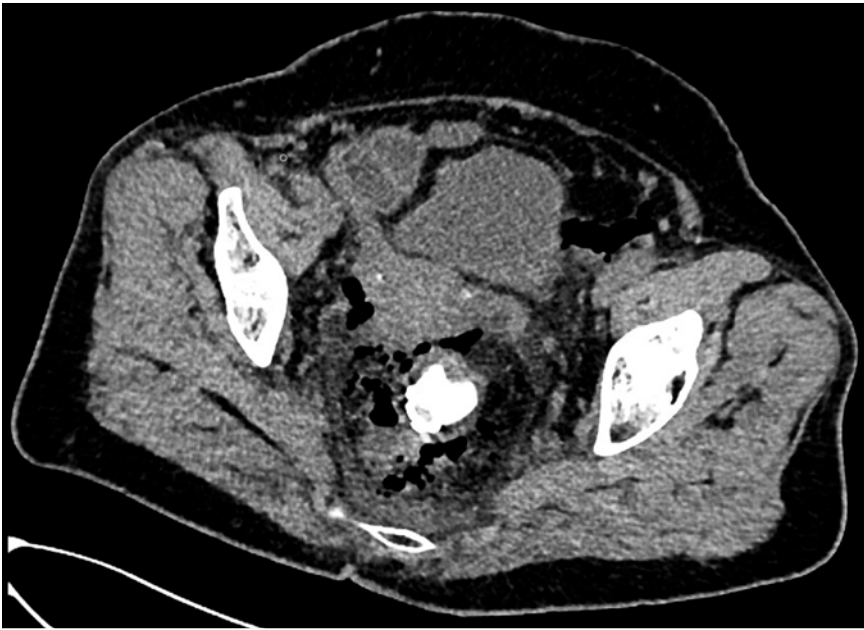
► **Video 1** Early endoscopic closure of a perforated rectum using an OTSC after diagnostic colonoscopy.

as appropriate treatment of acute iatrogenic perforations as it reduces costs, avoids surgery in the management, and shortens the length of hospitalization [3].

Endoscopy_UCTN_Code_CPL_1AJ_2AB

Competing interests

The authors declare that they have no conflict of interest.



► **Fig. 2** Postcolonoscopy CT of the pelvis, showing an intact rectal lumen.

The authors

Erol Barbur¹, **Gurhan Sisman²**

- 1 Acibadem Mehmet Ali Aydınlar University, School of Medicine, Istanbul, Turkey
- 2 Department of Gastroenterology, Acibadem Mehmet Ali Aydınlar University, School of Medicine, Istanbul, Turkey

Corresponding author

Gurhan Sisman, MD

Halkalı Merkez Mahallesi, Turgut Özal Bulvarı, No: 16, Acibadem Mehmet Ali Aydınlar Üniversitesi Atakent Hastanesi, Küçükçekmece, 34303 Istanbul, Turkey
gurhan.sisman@acibadem.edu.tr

References

- [1] Yilmaz B, Unlu O, Roach EC et al. Endoscopic clips for the closure of acute iatrogenic perforations: Where do we stand? *Dig Endosc* 2015; 27: 641–648
- [2] von Renteln D, Schmidt A, Vassiliou MC et al. Endoscopic closure of large colonic perforations using an over-the-scope clip: a randomized controlled porcine study. *Endoscopy* 2009; 41: 481–486
- [3] Mangiavillano B, Arena M, Masci E. Treatment of a sigmoid perforation with an over-the-scope clip during diagnostic colonoscopy. *Clin Gastroenterol Hepatol* 2014; 12: xxi–xxii

Bibliography

Endoscopy 2021; 53: E90–E91

DOI 10.1055/a-1198-4288

ISSN 0013-726X

published online 13.7.2020

© 2020. Thieme. All rights reserved.

Georg Thieme Verlag KG, Rüdigerstraße 14, 70469 Stuttgart, Germany

ENDOSCOPY E-VIDEOS

<https://eref.thieme.de/e-videos>



Endoscopy E-Videos is a free access online section, reporting on interesting cases and new techniques in gastroenterological endoscopy. All papers include a high quality video and all contributions are freely accessible online.

This section has its own submission website at

<https://mc.manuscriptcentral.com/e-videos>