

Endoscopic “cutting” of a trapped Dormia basket




► **Fig. 1** Cholangiogram showed two large bile duct stones.

Mechanical lithotripsy is effective for removal of large bile duct stones during endoscopic retrograde cholangiopancreatography (ERCP) but is a complex procedure with a risk of complications [1]. The availability of alternative techniques to extract difficult stones (i.e. endoscopic papillary large balloon dilation [EPLBD] and cholangioscopy-assisted lithotripsy) [2] has resulted in a decline in the use of mechanical lithotripsy. Nevertheless, cholangioscopy-assisted lithotripsy is an advanced technique, not widely available, and is still expensive. Complications of mechanical lithotripsy can be challenging to manage. We describe a method of removing a trapped Dormia basket.



► **Fig. 2** Attempted mechanical lithotripsy to remove the larger stone.


A 78-year-old woman with a history of recurrent cholangitis underwent ERCP for common bile duct stones. Two stones (10×15 mm and 15×20 mm) (► **Fig. 1**) were seen on cholangiogram. After sphincterotomy and 15-mm EPLBD, the smaller stone was extracted using a Fogarty balloon. The larger stone could not be removed, and intra-endoscopic mechanical lithotripsy was attempted (► **Fig. 2**); however, the Dormia wires broke near the handle of the lithotripter despite being specially designed for mechanical lithotripsy.



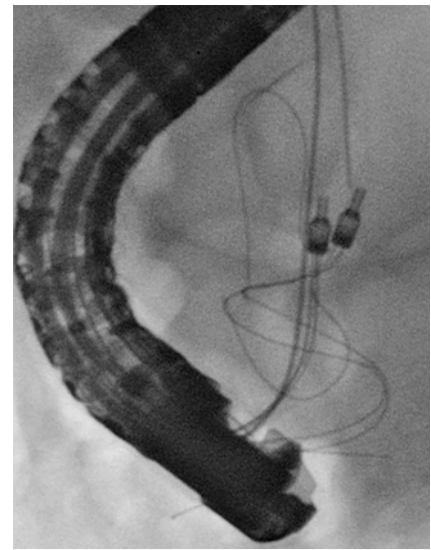
► **Fig. 3** The Nitinol Dormia basket. **a** The basket has a crimp (arrow) that joins the four wires of the basket. **b** The wires were cut (arrow) between the crimp (arrow-head) and the tip of the basket.

The Dormia basket was made of Nitinol with a “crimp” that joins the four wires (► **Fig. 3 a**). The trapped basket was pulled closer to the papilla, making it possible to visualize the “crimp.” Argon plasma coagulation (APC2; ERBE, Tübingen, Germany; Forced setting, 80W) was then used to trim the two wires between the “crimp” and the tip of the basket (► **Fig. 3 b**, ► **Video 1**); the trapped Dormia was finally retrieved using another small (10 mm) over-the-wire basket (► **Fig. 4**). Plastic stents were inserted near the stone and the patient was referred for cholangioscopy-assisted lithotripsy, which was successful. The use of APC to trim the meshes of self-expandable metal stents has been reported previously [3] and can be considered for “cutting” other endoscopic devices when necessary for their retrieval.

Endoscopy_UCTN_Code_CPL_1AK_2AF



▶ **Video 1** Application of argon plasma coagulation to trim the wires of a trapped Nitinol Dormia basket for retrieval.



▶ **Fig. 4** Removal of the trapped Dormia with another small basket.

Competing interests

Dr. Costamagna is an advisory board member for Cook Medical, Olympus, and Ethicon, and has received research funding from Boston Scientific Corp. and Apollo Endosurgery. Dr. Tringali has been a consultant for Boston Scientific Corp. All other authors declare that they have no conflict of interest.

Corresponding author

Andrea Tringali, MD, PhD
 Digestive Endoscopy Unit, Fondazione Policlinico Gemelli IRCCS – Catholic University, Largo Gemelli 8, Rome 00168, Italy
 Fax: +39-06-30157220
 andrea.tringali@unicatt.it

Bibliography

Endoscopy 2021; 53: E79–E80
DOI 10.1055/a-1196-1095
ISSN 0013-726X
published online 26.6.2020
 © 2020. Thieme. All rights reserved.
 Georg Thieme Verlag KG, Rüdigerstraße 14, 70469 Stuttgart, Germany

The authors

Andrea Tringali^{1,2}, Giovanna Margagnoni³, Stefano Brighi³, Guido Costamagna^{1,2}

- 1 Digestive Endoscopy Unit, Fondazione Policlinico Universitario Agostino Gemelli IRCCS, Roma, Italia
- 2 Centre for Endoscopic Research Therapeutics and Training (CERTT), Università Cattolica del Sacro Cuore di Roma, Roma, Italia
- 3 Digestive Endoscopy Unit, Ospedale “F. Spaziani”, Frosinone, Italia

References

- [1] Thomas M, Howell DA, Carr-Locke D et al. Mechanical lithotripsy of pancreatic and biliary stones: complications and available treatment options collected from expert centers. *Am J Gastroenterol* 2007; 102: 1896–1902
- [2] Manes G, Paspatis G, Aabakken L et al. Endoscopic management of common bile duct stones: European Society of Gastrointestinal Endoscopy (ESGE) guideline. *Endoscopy* 2019; 51: 472–491
- [3] Demarquay JF, Dumas R, Peten EP et al. Argon plasma endoscopic section of biliary metallic prostheses. *Endoscopy* 2001; 33: 289–290

ENDOSCOPY E-VIDEOS

<https://eref.thieme.de/e-videos>



Endoscopy E-Videos is a free access online section, reporting on interesting cases and new

techniques in gastroenterological endoscopy. All papers include a high quality video and all contributions are freely accessible online.

This section has its own submission website at

<https://mc.manuscriptcentral.com/e-videos>