

EFSUMB Publications

Case of the Month

Don't miss the latest case on Ultrasound findings in COVID-19 pneumonia

Authors Dr. Soccorso Sofia, Dr. Michele Spampinato from the Emergency Department, Local Health Unit, Bologna, Italy

A case with images which highlights the LUS signs in COVID-19 patients

For more information visit <http://www.efsumb.org/blog/archives/26658>

There are issues related to using lung ultrasound in potential COVID-19 patients, for example, being technically able to do a scan does not compensate for the background knowledge, experience and responsibility a radiologist or a respiratory physician has. Whilst the bedside use may reduce the risks of spreading the virus around the hospital

without the right PPE puts the US operator at a greater risk potentially than MR/CT.

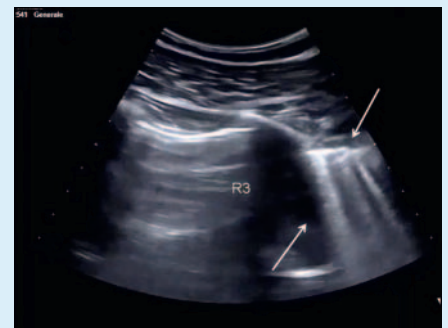
Do you have any views, questions or comments you would like to raise on the EFSUMB website?

<http://www.efsumb.org/blog/covid-19>

New guidelines to be ePublished

Guidelines and Good Clinical Practice Recommendations for Contrast Enhanced Ultrasound (CEUS) in the Liver – Update 2020

WFUMB in Cooperation with EFSUMB, AFSUMB, AIUM, and FLAUS



Region R3, day 1, non-confluent vertical artefacts indicating non-ventilated lung (arrows).

Part 6: EFSUMB Guidelines GIUS Intestinal Emergencies Position Paper is now an ePublication

<https://www.thieme-connect.de/products/ejournals/pdf/10.1055/a-1147-1295.pdf>