

# Vestibular Nerve Atrophy After Vestibular Neuritis – Results from a Prospective High-Resolution MRI Study

## Atrophie des Nervus vestibularis nach einem akuten Vestibularisausfall (Neuronitis vestibularis) – Ergebnisse einer prospektiven hochauflösten MRT-Untersuchung

### Authors

Wolfgang Freund<sup>1</sup>, Frank Weber<sup>2</sup>, Daniel Schneider<sup>1</sup>, Ulrich Mayer<sup>3</sup>, Marc Scheithauer<sup>4</sup>, Meinrad Beer<sup>1</sup>

### Affiliations

- 1 Diagnostic and Interventional Radiology, University Hospital Ulm, Germany
- 2 Research, German Air Force Center of Aerospace Medicine, Fürstenfeldbruck, Germany
- 3 Cardiology, Private Practice, Ulm, Germany
- 4 Otolaryngology, University Hospital Ulm, Germany

### Key words

head/neck, vestibular neuritis, vertigo, atrophy, MR imaging, vestibular nerve disease

received 29.06.2019

accepted 22.01.2020

### Bibliography

DOI <https://doi.org/10.1055/a-1110-7441>

Published online: 20.2.2020

Fortschr Röntgenstr 2020; 192: 854–861

© Georg Thieme Verlag KG, Stuttgart · New York

ISSN 1438-9029

### Correspondence

Dr. Wolfgang Freund

Diagnostic and Interventional Radiology,  
University Hospital Ulm, Steinhövelstraße 9, 89075 Ulm,  
Germany

Tel.: ++49/731/50061004

Fax: ++49/731/50061002

freund-ulm@t-online.de

### ZUSAMMENFASSUNG

**Ziel** Ein plötzlicher Funktionsverlust der Vestibularnerven wird meist als Neuronitis vestibularis (NV) bezeichnet, auch wenn die entzündliche Genese, aber auch der exakte Ort der Schädigung unklar sind. Die Therapie ist daher meist ungezielt symptomatisch. Daher sollte überprüft werden, ob nach einer NV mit persistierendem vestibulärem Ausfall eine Atrophie des Nervus vestibularis nachweisbar ist.

**Material und Methoden** Nach positivem Votum der Ethikkommission und in Übereinstimmung mit der Erklärung von Helsinki und Aufklärung und Einverständnis wurden je 10 Patienten mit gesichertem vestibulärem Defizit und 10 Alters-

gematchte gesunde Kontrollpersonen eingeschlossen. Hochauflösende (0,2 mm in plane) Darstellung des inneren Gehörgangs erfolgte mit einer 3D-CISS-Sequenz in einem 3T-MRT. Der Verlauf der Nerven wurde im 3D-Datensatz rekonstruiert und als Messpunkt die Lage 60 % lateral im Meatus acusticus internus bestimmt. Die Querschnittsflächen wurden separat von 2 bezüglich der Klinik geblindeten Auswertern im Nervus vestibularis superior (SVN) und inferior (IVN) gemessen.

**Ergebnisse** Die Standardabweichung der beiden Auswerter betrug 22 %. Der erkrankte SVN war signifikant ( $p = 0,026$ ) atrophisiert im Vergleich zu Kontrollpersonen mit einer 24 % kleineren Querschnittsfläche. Auch im Vergleich zum IVN zeigte sich die Atrophie als kleinerer Quotient SVN/IVN auf der symptomatischen Seite ( $p = 0,017$ ). Auf Einzelpersonenebene war jedoch nur bei 5 Erkrankten eine massive Atrophie festzustellen, während 5 symptomatische SVN nicht atroph waren (dabei kein Einfluss der Symptombdauer).

**Diskussion** Die hochauflösende MRT des SVN konnte auf Gruppenebene eine signifikante Atrophie bei symptomatischen Patienten zeigen. Die Einschlusskriterien waren stringent (über 6 Monate Symptombdauer, messtechnisch bestätigtes bleibendes vestibuläres Defizit). Nachdem aber die Differenz durch massive Abweichung lediglich von der Hälfte der Patienten getragen wird, kann vermutet werden, dass unterschiedliche Ätiologien hinter dem homogenen klinischen Bild stecken.

### Kernaussagen:

- Hochauflösendes MRT kann die Atrophie des Nervus vestibularis superior nachweisen.
- Nur die Hälfte der 10 untersuchten Patienten nach Neuritis vestibularis zeigte jedoch eine starke Atrophie.
- Daher sollte weiter nach unterschiedlicher Ätiologie der klinisch homogen erscheinenden Erkrankung gesucht werden.

### ABSTRACT

**Purpose** Sudden unilateral peripheral vestibular deficit is mostly termed vestibular neuritis (VN), even if its cause or the exact location of the lesion remains unclear. Thus, therapy

is mostly symptomatic. We aimed to prove if there is peripheral atrophy after VN with persistent canal paresis.

**Methods** After approval by the ethics committee and according to the declaration of Helsinki and with informed consent, ten patients with persistent canal paresis after VN and ten age-matched healthy controls were included. High-resolution measurement (in-plane resolution 0.2 mm) of the internal auditory canal (IAC) using a 3D CISS sequence at 3 Tesla was performed. The course of the pertaining nerves was reconstructed in the 3D dataset and the measurement was performed at 60% of the length of the IAC. The cross-sectional areas of the superior (SVN) and inferior vestibular nerve (IVN) were taken independently by two blinded readers.

**Results** The interrater difference regarding the area was 22%. We found significant atrophy of the SVN with a 24% smaller area ( $p = 0.026$ ) and found a smaller ratio of SVN/IVN on the symptomatic side ( $p = 0.017$ ). Concerning single subject data, only 5 patients showed extensive atrophy of the NVS, while 5 patients did not. The time since symptom onset did not significantly influence the atrophy.

**Conclusion** MRI measuring of the area of the NVS after VN could detect atrophy after VN. However, only 5 patients exhibited marked atrophy, while the other 5 patients did not. With the background of stringent inclusion criteria (more than 6 months of symptom duration and proven persistent canal paresis), one has to wonder if there might be different etiologies behind the apparently identical symptoms.

#### Key Points:

- MRI measuring of the area of the NVS after VN could detect atrophy after VN
- Only half of the 10 researched patients showed atrophy, while the other patients did not
- There are different etiologies to be suspected for VN

#### Citation Format

- Freund W, Weber F, Schneider D et al. Vestibular Nerve Atrophy After Vestibular Neuritis – Results from a Prospective High-Resolution MRI Study. *Fortschr Röntgenstr* 2020; 192: 854–861

## Introduction

Sudden unilateral peripheral vestibular deficit is mostly referred to as vestibular neuritis (VN). Its cause is unknown and debated [1–3], even the primary locus (nerve versus labyrinth) is not proven [2]. Diagnosis is one of exclusion: cerebellar infarction, Wallenberg's syndrome or Meniere's disease or a tumor, neurovascular conflict and other issues [1, 4, 5] have to be ruled out. So far, different diagnostic tests have failed to diagnose VN exactly [6]. According to the inflammation hypothesis, VN may be caused by acute infection with different viruses [7] or by reactivation of latent Herpes virus in the vestibular ganglia [8, 9]. Bilateral VN may be caused by autoimmune processes [10]. New reports even suspect vascular risk factors for VN [11–13].

Some studies show involvement of both the superior vestibular nerve (SVN) and the inferior vestibular nerve (IVN) in VN [14, 15], while most report a predominant SVN lesion. The longer course through the temporal bone may explain the predominance of lesions of the SVN in VN [16, 17]. The function of the SVN is to innervate the superior and lateral semicircular canals and the utricle [18]. Caloric testing stimulates just the lateral semicircular canal and so just the SVN.

After vestibular failure, peripheral as well as central [19–22] compensation leads to improvement of symptoms. Recovery is strongest in the first weeks after onset [23]. Since the exact pathogenesis of vestibular failure is unclear, elucidation of anatomic sequelae (in this case atrophy of the SVN) is interesting. In one study, 50% of the patients improved to normalization of the vestibular test results after 6–12 months [14].

The measurement of the IAC nerves has been described previously [24] with 3D CISS in VN and in deafness [25] with limited resolution due to hardware restraints. With 3T MRI and multi-channel head coils, higher resolution is now possible [26].

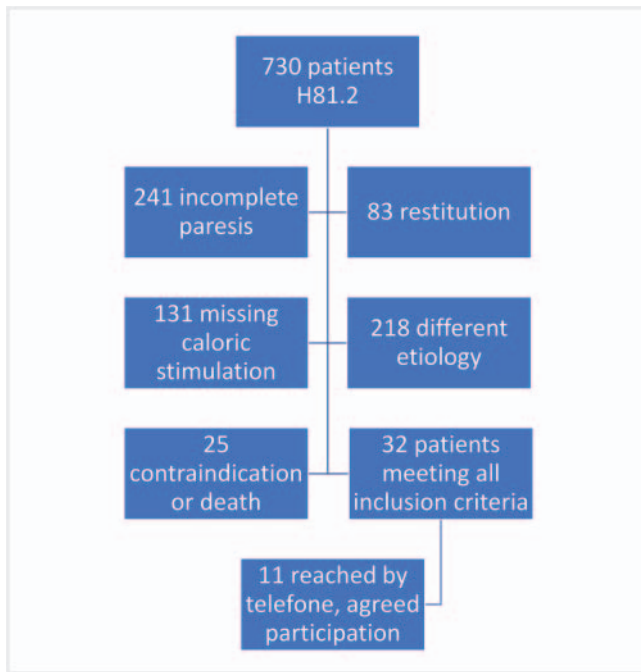
We sought to prove that persistent canal paresis (no caloric response) results in atrophy of the SVN.

## Methods

The study was performed according to the ethical standards of the declaration of Helsinki and following approval of the ethics committee of our university (no. 374/14).

Power calculations were performed with the following boundary conditions: Cases will show atrophy of more than 1/2, while controls will show no atrophy. Normal nerve cross-section areas will be the same in controls as in the unaffected SVN and the measurements will show normal distribution with similar standard deviations. In a convenience sample of 5 healthy collaborators, we found the standard deviation of the SVN area measurement to be 0.35, leading to an effect size of 1.4, thus a patient requirement of 10 subjects. We therefore included 10 patients and 10 age-matched healthy controls.

Patients were retrospectively identified with the help of the patient database of the ENT department, searching the years 2012 to 2017 for the corresponding ICD-10 code H81.2. Inclusion criteria for patients were a single attack of VN at least 6 months prior, with proven persistent canal paresis. This proof of persistent canal paresis required thermal stimulation either less than 3 months ago in cases of VN 6–12 months prior to the investigation, or less than 6 months ago for VN more than 12 months prior to the investigation. The inclusion process for patients is described in ► **Fig. 1**. The inclusion criteria for healthy controls were similar age (less than 5 years difference) as the corresponding patient and no inner ear affliction, i. e., no vertigo according to a standardized questionnaire (question 26 loading <5 points) [27, 28] in the last four weeks. Inclusion required written informed consent to participate in the imaging study.



► **Fig. 1** Inclusion process: This figure describes the inclusion process with search for the relevant diagnosis ICD H 81.2 which yielded 730 patients. Exclusion of incomplete paresis, restitution of function in the meantime, different etiology, missing caloric stimulation or contraindication to the examination led to a final group of 32 patients meeting all inclusion criteria. 11 patients could be reached by telephone and agreed to participate.

► **Abb. 1** Einschluss von Patienten. Die Grafik zeigt den Ablauf der Selektion von Studienteilnehmern: Suche in der Patientendatenbank der HNO-Klinik nach Patienten mit der ICD-10-Diagnose H81.2 (Neuritis vestibularis). Von den gefundenen 730 Patienten mussten diejenigen mit inkompletter Parese oder zwischenzeitiger Erholung der vestibulären Funktion ausgeschlossen werden. Außerdem andere Ursachen des Schwindels wie Tumor oder Ischämie. Außerdem Ausschluss bei fehlendem Ergebnis der kalorischen Stimulation oder Kontraindikation für MRT. Die gefundenen 32 Patienten wurden telefonisch kontaktiert, 11 Patienten erklärten ihre Bereitschaft zur Studienteilnahme.

The exclusion criteria for both groups were contraindications to MRI, relevant brain lesions like stroke or multiple sclerosis or relevant motion or susceptibility artifacts on the acquired MRI scans.

MRI scanning was performed on a 3 T system (Siemens Skyra, Erlangen, Germany) using the sequence parameters listed in ► **Table 1**.

While the FLAIR imaging was only used to exclude relevant brain pathology, the nerve diameter measurements were done with the CISS sequence images on a workstation using 3 D reformatting and the VOI tool of the PACS (Impax EE R20XVI SU3 of Agfa Healthcare, Bonn, Germany). In order to correctly measure the cross-sectional area of the SVN and IVN, a perpendicular plane along the axis of the internal auditory canal was reconstructed at 60% of the canal length. In-plane resolution of  $0.2 \times 0.3$  mm was achieved (see ► **Table 1**, ► **Fig. 2**).

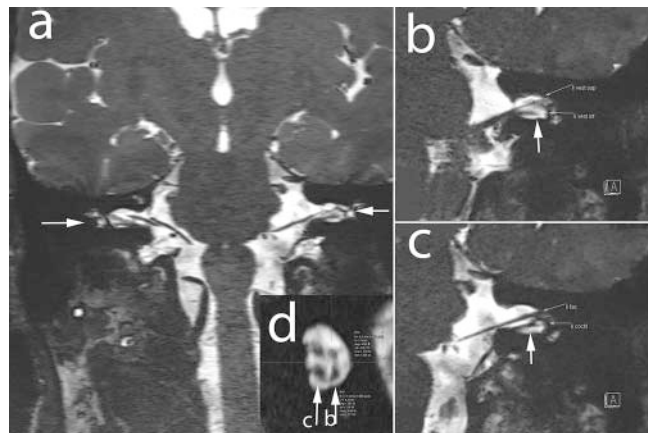
► **Table 1** MRI sequence parameters.

► **Tab. 1** MRT-Sequenzparameter.

sequence	FLAIR	CISS
FOV (mm)	220*179	170*197
slice thickness (mm)	6	0.2
TR (sec)	10 000	10.97
TE (sec)	81	4.97
FA in degrees	150	37
TA (min:sec)	2:22	9:51
dimension	coronal 2 D	coronal 3 D

FLAIR: fluid attenuated inversion recovery, CISS: constructive interference in steady state, FOV: field of view, TR: time of repetition, TE: echo time, FA: flip angle, TA: acquisition time.

FLAIR = fluid-attenuated inversion recovery; CISS = constructive interference in steady state; FOV = abgebildete Fläche; TR = Repetitionszeit; TE = Echozeit; FA = Flipwinkel; TA = Aufnahmedauer der Sequenz.



► **Fig. 2** Reconstruction of the CISS dataset and placement of the regions of interest (ROI). **a** shows a coronal view of the brainstem, the arrows point to the vestibulocochlear nerves. **b** shows the posterior and **c** the anterior part of the internal auditory canal, including the superior and inferior vestibular nerves as well as the cochlear and facial nerves. The arrows point to the site of reconstruction of the sagittal plane. **d** depicts the relevant cross-sectional areas of the superior and inferior vestibular nerve with the manually drawn ROIs measuring the area of the nerves.

► **Abb. 2** Rekonstruktion des CISS-3D-Datensatzes und Platzierung der Messfläche (Region of interest, ROI): **a** zeigt eine koronare Rekonstruktion, die den Hirnstamm darstellt. Pfeile deuten auf die vestibulocochleären Nerven. **b** zeigt einen posterioren und **c** einen anterioren Anschnitt des inneren Gehörgangs und damit den Nervus vestibularis superior und inferior (SVN, IVN) sowie den Nervus cochlearis und facialis. Die Pfeile zeigen die Ebene der Rekonstruktion in der sagittalen Ansicht **d** und dort die relevante Querschnittsfläche durch manuell eingezeichnete ROI auf dem SVN und IVN.

A reduction of resolution in the phase-encoding direction (RL) according to the known direction of the vestibular nerves in the right-left direction and the atrophy occurring in plane was applied to keep acquisition times reasonable.

The measurements were done independently by two readers blinded to the clinical information. Single measurements were used to compute interreader variability parameters, but for other comparisons, the averaged readings were used. Statistical computations (descriptive statistics, t-test and intraclass correlation coefficient (ICC)) were performed with R [29].  $P < 0.05$  was considered significant.

## Results

730 patients with the diagnosis ICD H81.2 were identified by searching the database of the university ENT department from January 1, 2012 until December 31, 2017. The enrollment process is depicted in ► Fig. 1. The coronal CISS with corresponding reconstruction of the inner auditory canal and measurement site is shown in ► Fig. 2. Exemplary measurements are depicted in ► Fig. 3.

11 patients meeting the inclusion criteria were finally enrolled, but 1 patient had to be excluded after scanning due to artifacts. Reconstruction of the perpendicular plane at 60% of the IAC length was successful. The area measurements for the vestibular nerves of the two raters differed by 22%, the interrater reliability (intraclass correlation coefficient (ICC)) was 0.66, which can be described as good [30].

The SVN and IVN area measurements are shown in ► Table 2, 3. There were statistically significant findings showing that the cross-sectional area of the symptomatic SVN averaged  $0.8 \text{ mm}^2$  compared to  $1.05 \text{ mm}^2$  for the asymptomatic side (24% difference, t-test  $p = 0.026$ ) and the difference between the asymptomatic and symptomatic side is significant compared to the right/left difference of the controls (here the mean areas were  $1.03$  and  $1.11 \text{ mm}^2$  respectively,  $p = 0.019$ ).

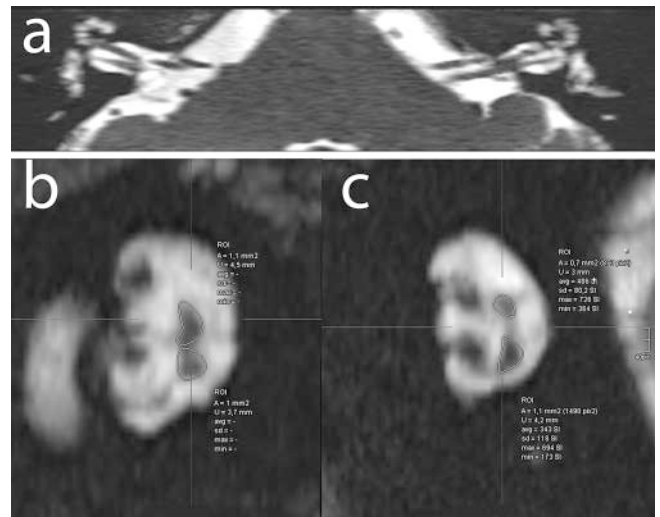
In 5 patients the difference between symptomatic and asymptomatic SVN shows an atrophy of more than  $0.25 \text{ mm}^2$ . These 5 patients drive the statistically significant difference of the group comparison (► Fig. 4). The atrophy of the SVN is correlated to the symptom duration (Pearson's  $r = 0.43$ ,  $p = 0.2$ ). The correlation does not reach significance.

## Discussion

Our measurements could show significant atrophy of the SVN in patients with persistent canal paresis after VN. However, while half of the patients do not show differences compared to controls, the group difference is driven by 5 patients exhibiting rather marked atrophy of the SVN.

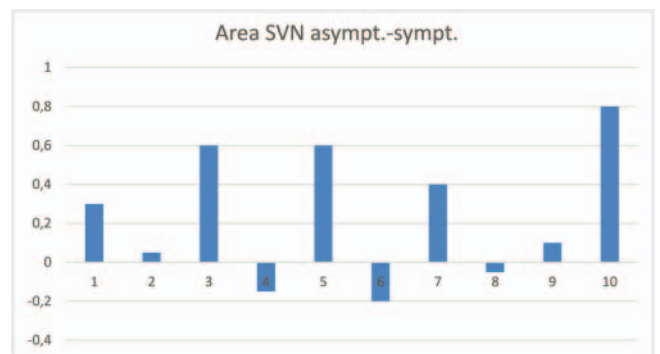
### Technical considerations

The measurements differed between the readers, but overall agreement was good, as the ICC of 0.66 shows, and the results are deemed reliable. Prior measurements of nerves in the internal



► Fig. 3 Patient example: Exemplary cross-sectional views of the internal auditory canal of a patient with atrophy of the superior vestibular nerve on the left side. **a** transverse view, **b** cross-sectional view with ROIs on the right side, **c** left side.

► Abb. 3 Beispielfall (Patient): Rekonstruierte Ansicht der Querschnittsflächen im inneren Gehörgang eines Patienten mit Atrophie des SVN bei linksseitiger NV. **a** zeigt eine transversale Rekonstruktion, **b** die sagittale Rekonstruktion der rechten Seite und **c** der linken Seite.



► Fig. 4 Distribution of atrophy among the patients in our study. Shown is the difference between asymptomatic SVN and symptomatic SVN.

► Abb. 4 Darstellung der Verteilung der Atrophie unter den Patienten in unserer Studie: Jeweils ist die Differenz der Querschnitte der asymptomatischen SVN – symptomatischen SVN gezeigt.

auditory canal [24, 25] with  $0.7 \text{ mm}$  isotropic resolution are thought to be less reliable (due to the small diameter of the vestibular and cochlear nerves between  $0.5$  and  $1 \text{ mm}$ ) than the now performed measurement with  $0.2 \text{ mm}$  in-plane resolution. With the resolution used in our study, it is possible to detect small diameter changes and to reliably discern two subgroups in our patients: 5 patients with atrophy and 5 without atrophy of the SVN. In one previous study [31] there were only minimal differences in diameter between symptomatic and asymptomatic vestibular

► **Table 2** Vestibular nerve area (in mm<sup>2</sup>) measurements of patients (no. 1–10) and controls (no. 11–20).

► **Tab. 2** Querschnittsfläche des SVN bzw. IVN in mm<sup>2</sup>. Messungen der Patienten (Nr. 1–10) und der Alters-gematchten, gesunden Kontrollpersonen (Nr. 11–20).

no.	side	age	r SVN	r IVN	l SVN	l IVN	SVN asymptomatic-symptomatic
1	left	65	0.7	0.6	0.4	0.85	0.3
2	left	74	1.15	0.75	1.1	0.7	0.05
3	right	74	0.75	1.2	1.35	1	0.6
4	right	76	1.1	0.8	0.95	0.65	-0.15
5	right	60	0.35	0.45	0.95	1.15	0.6
6	left	37	1	0.85	1.2	1	-0.2
7	left	62	1.15	0.85	0.75	1.15	0.4
8	right	61	1.2	0.8	1.15	0.85	-0.05
9	right	58	0.9	0.85	1	0.75	0.1
10	left	61	1.05	0.65	0.25	0.6	0.8
mean		62.80	0.94	0.78	0.91	0.87	0.25
SD		10.65	0.25	0.19	0.33	0.19	0.3
no.	side	age	r SVN	r IVN	l SVN	l IVN	SVN right-left
11	healthy	64	1.2	0.85	1.15	0.7	0.05
12	healthy	75	0.55	0.55	0.7	0.5	-0.15
13	healthy	74	0.95	0.65	0.85	0.45	0.1
14	healthy	79	0.9	0.55	0.7	0.5	0.2
15	healthy	58	1.4	1.05	1.9	1.25	-0.5
16	healthy	39	1	1.05	1.1	0.7	-0.1
17	healthy	60	1.1	0.9	1	0.6	0.1
18	healthy	59	1.2	0.9	1.45	0.85	-0.25
19	healthy	56	1.15	0.65	1.3	0.6	-0.15
20	healthy	57	0.85	0.7	0.9	1.15	-0.05
mean		62.10	1.03	0.79	1.11	0.73	-0.15
SD		11.07	0.22	0.18	0.35	0.26	0.19

SVN: superior vestibular nerve, IVN: inferior vestibular nerve, SVN: asymptomatic-symptomatic as a measure of atrophy could be computed for the patients, while we computed the side comparison right-left for healthy controls as a reference (estimate of natural variance).

SVN = Nervus vestibularis superior; IVN = Nervus vestibularis inferior. Die Differenz der Querschnittsflächen der asymptomatischen Seite minus der symptomatischen Seite (SVN asymptomatic-symptomatic) als Maß der Atrophie konnte für Patienten berechnet werden. Bei gesunden Kontrollen wurde als Maß der natürlichen Varianz die rechte-linke Seite berechnet.

nerves. However, since the resolution (0.7 mm) was the same as the nerve diameter, the results are deemed not reliable and did not permit the forming of subgroups. Higher resolution than used in our study would be possible with longer scan times, but pulsation and imperceptible head movements as well as patient comfort prohibit longer scan times.

### Heterogeneity regarding the atrophy of the SVN

Normally the SVN is larger than the IVN [32], and due to the longer course through the bony canal, the risk of SVN lesions is thought to be greater [16].

The absolute size of the SVN could be influenced by genetic causes. However, since the size of the nerves tends to be symmetrical [32], we used the comparison to the asymptomatic SVN as an internal reference.

Atrophy of nerves is due to axonal loss and therefore has functional consequences. Recently, atrophy of the lumbar myelon has been shown after cervical spine injury, with correlation of functional loss with the severity of lumbar atrophy and the extent of the cervical lesion [33]. In the optic nerve, atrophy occurs as early as 4–6 weeks after injury [34]. In our sample, the correlation of atrophy with symptom duration is marked but does not reach statistical significance, which would align with the reported time



► **Table 3** Area measurements (mm<sup>2</sup>) of SVN and IVN, significant differences between symptomatic and asymptomatic side are given in bold figures.

► **Tab. 3** Querschnittsfläche (mm<sup>2</sup>) des SVN und IVN. Signifikante Unterschiede zwischen symptomatischer und asymptomatischer Seite sind fett gedruckt.

measurements	patients symptomatic	patients healthy side	controls
SVN	<b>0.8</b>	1.05	1.07
IVN	0.84	0.81	0.76
SVN/IVN	<b>0.96</b>	1.32	1.43
SVN/SVN	<b>0.76</b>	n.a	n.a.
IVN/IVN	1.07	n.a	n.a.

SVN: superior vestibular nerve, IVN: inferior vestibular nerve, SVN/SVN ratio of SVN symptomatic/healthy, IVN/IVN ratio of IVN symptomatic/healthy. SVN = Nervus vestibularis superior; IVN = Nervus vestibularis inferior. Die Verhältnisse der Querschnittsflächen der symptomatischen Seite geteilt durch die asymptomatische Seite SVN/SVN bzw. IVN/IVN zeigen einen signifikanten Unterschied nur für den SVN.

course and our inclusion criteria of more than 6 months after VN. Thus, other explanations of this heterogeneity have to be considered.

### Is there only one type of VN?

Usually, patients presenting with acute VN are differentiated with neurotological measurements to discern different lesion sites [22]. Due to the broader inclusion of VN patients, one study describes affection mostly of both the SVN and IVN in VN [14], while another study describes affection of the SVN alone in about half of cases and a similar proportion of both SVN and IVN lesion [15]. A recent study using delayed contrast enhancement in FLAIR measurements found signs of inflammation in 69% of patients, with longer symptom duration in patients showing inflammation [35]. We tried to overcome these difficulties by including only patients with persistent canal paresis.

Normally, persistent canal paresis is treated as a single cause pathology. Our results with half of the patients showing marked atrophy and the other half exhibiting no atrophy despite stringent inclusion criteria with persistent canal paresis must be interpreted as a sign of disparate etiologies in our sample of VN. The concept of VN has been criticized already, and we had tried to avoid the pitfall of exclusively using the clinical diagnosis ICD H81.2 as the inclusion criterion but had narrowed the field by adding persistent canal paresis as a criterion. Thus, we included only cases with a possible lesion of the SVN and excluded cases more likely to have received IVN damage. Nevertheless, the striking disparity of our sample points to possibly different etiologies of the persistent canal paresis. VN atrophy means axonal loss, most probably due to damage to vestibular nerve neurons, thus pointing to a peripheral lesion. No atrophy in the presence of loss of function (persistent canal paresis) points to a lesion more centrally, although FLAIR did not show evidence of it. Thus, a central downregulation of ipsilateral afferent inputs during the process of compensation of the initial vertigo could be a possibility.

### Limitations

The measurements of the readers showed considerable variation. This may be partly attributable to the tool used: In the ROI area measurement tool, areas are only given in mm<sup>2</sup> with one decimal. This influences the interpretation of the results, even if the average of the difference between the readers was only 4%, resulting in no statistically significant change on group average readings. Since we did not reproduce the individual readings, we cannot know the intrarater variation. Our study did not intend to prove the diagnostic use of the area differences. Therefore, we cannot recommend it with this aim.

### Consequences

Earlier studies had shown quite different courses after VN with some cases with few remaining symptoms and others with full deficit [1]. There was also a correlation between inflammation and symptom duration [35].

Rehabilitation after VN includes physiotherapy [36] and involves neural and behavioral plasticity [23, 37], so that different paths could be taken to address peripheral damage with SVN atrophy as opposed to missing function without atrophy.

Further research into VN is warranted since the efficacy of current therapies is in question. A recent randomized controlled trial showed no value for the addition of methylprednisolone to conventional therapy [38], others had shown negative results for aminopyridine [19]. Peripheral causes (presumably leading to atrophy of the SVN) should be treated differently from centrally mediated causes without atrophy.

### Conflict of Interest

The authors declare that they have no conflict of interest.

## References

- [1] Nadol JB Jr. Vestibular neuritis. *Otolaryngology – head and neck surgery: official journal of American Academy of Otolaryngology-Head and Neck Surgery* 1995; 112: 162–172
- [2] Uffer DS, Hegemann SC. About the pathophysiology of acute unilateral vestibular deficit – vestibular neuritis (VN) or peripheral vestibulopathy (PVP)? *Journal of vestibular research: equilibrium & orientation* 2016; 26: 311–317. doi:10.3233/VES-160581
- [3] Greco A, Macri GF, Gallo A et al. Is vestibular neuritis an immune related vestibular neuropathy inducing vertigo? *Journal of immunology research* 2014; 2014: 459048. doi:10.1155/2014/459048
- [4] Lee H, Kim H-J, Koo J-W et al. Progression of acute cochleovestibulopathy into anterior inferior cerebellar artery infarction. *Journal of the neurological sciences* 2009; 278: 119–122
- [5] Loader B, Linauer I, Korckes S et al. A connection between neurovascular conflicts within the cerebellopontine angle and vestibular neuritis, a case controlled cohort study. *Acta otorhinolaryngologica Italica: organo ufficiale della Societa italiana di otorinolaringologia e chirurgia cervico-facciale* 2016; 36: 421–427. doi:10.14639/0392-100X-766
- [6] Nosrati-Zarenoe R, Hansson M, Hultcrantz E. Assessment of diagnostic approaches to idiopathic sudden sensorineural hearing loss and their influence on treatment and outcome. *Acta oto-laryngologica* 2010; 130: 384–391. doi:10.1080/00016480903161541
- [7] Ergul Y, Ekici B, Tastan Y et al. Vestibular neuritis caused by enteroviral infection. *Pediatric neurology* 2006; 34: 45–46. doi:10.1016/j.pediatrneurol.2005.05.025
- [8] Theil D, Arbusow V, Derfuss T et al. Prevalence of HSV-1 LAT in human trigeminal, geniculate, and vestibular ganglia and its implication for cranial nerve syndromes. *Brain Pathol* 2001; 11: 408–413
- [9] Rujescu D, Hartmann AM, Giegling I et al. Genome-Wide Association Study in Vestibular Neuritis: Involvement of the Host Factor for HSV-1 Replication. *Frontiers in neurology* 2018; 9: 591. doi:10.3389/fneur.2018.00591
- [10] Sutjita M, Peter JB, Baloh RW et al. Type II collagen antibodies in patients with sensorineural hearing loss. *Lancet* 1992; 339: 559–560
- [11] Han W, Wang D, Wu Y et al. Correlation between vestibular neuritis and cerebrovascular risk factors. *American journal of otolaryngology* 2018. doi:10.1016/j.amjoto.2018.08.006
- [12] Oron Y, Shemesh S, Shushan S et al. Cardiovascular Risk Factors Among Patients With Vestibular Neuritis. *The Annals of otology, rhinology, and laryngology* 2017; 126: 597–601. doi:10.1177/0003489417718846
- [13] Chung JH, Lee SH, Park CW et al. Clinical Significance of Arterial Stiffness and Metabolic Syndrome Scores in Vestibular Neuritis. *Otology & neurotology: official publication of the American Otological Society, American Neurotology Society [and] European Academy of Otolology and Neurotology* 2017; 38: 737–741. doi:10.1097/MAO.0000000000001352
- [14] Taylor RL, McGarvie LA, Reid N et al. Vestibular neuritis affects both superior and inferior vestibular nerves. *Neurology* 2016; 87: 1704–1712. doi:10.1212/WNL.0000000000003223
- [15] Lv YF, Zhang DG, Fan ZM et al. [Frequency and position characteristics of the vestibular dysfunction in vestibular neuritis patients]. *Lin chuang er bi yan hou tou jing wai ke za zhi = Journal of clinical otorhinolaryngology, head, and neck surgery* 2016; 30: 602–605. doi:10.13201/j.issn.1001-1781.2016.08.004
- [16] Gianoli G, Goebel J, Mowry S et al. Anatomic differences in the lateral vestibular nerve channels and their implications in vestibular neuritis. *Otology & neurotology: official publication of the American Otological Society, American Neurotology Society [and] European Academy of Otolology and Neurotology* 2005; 26: 489–494
- [17] Nayak S, He L, Roehm PC. Superior Versus Inferior Vestibular Neuritis: Are There Intrinsic Differences in Infection, Reactivation, or Production of Infectious Particles Between the Vestibular Ganglia? *Otology & neurotology: official publication of the American Otological Society, American Neurotology Society [and] European Academy of Otolology and Neurotology* 2015; 36: 1266–1274. doi:10.1097/MAO.0000000000000758
- [18] Swartz JD, Daniels DL, Harnsberger HR et al. Balance and equilibrium, I: The vestibule and semicircular canals. *AJNR Am J Neuroradiol* 1996; 17: 17–21
- [19] Beck R, Gunther L, Xiong G et al. The mixed blessing of treating symptoms in acute vestibular failure—evidence from a 4-aminopyridine experiment. *Experimental neurology* 2014; 261: 638–645. doi:10.1016/j.expneurol.2014.08.013
- [20] Zwergal A, Schlichtiger J, Xiong G et al. Sequential [(18)F]FDG microPET whole-brain imaging of central vestibular compensation: a model of deafferentation-induced brain plasticity. *Brain structure & function* 2014; 221: 159–170. doi:10.1007/s00429-014-0899-1
- [21] zu Eulenburg P, Stoeter P, Dieterich M. Voxel-based morphometry depicts central compensation after vestibular neuritis. *Annals of neurology* 2010; 68: 241–249. doi:10.1002/ana.22063
- [22] Allum JHJ, Scheltinga A, Honegger F. The Effect of Peripheral Vestibular Recovery on Improvements in Vestibulo-ocular Reflexes and Balance Control After Acute Unilateral Peripheral Vestibular Loss. *Otology & neurotology: official publication of the American Otological Society, American Neurotology Society [and] European Academy of Otolology and Neurotology* 2017; 38: e531–e538. doi:10.1097/MAO.0000000000001477
- [23] Kammerlind AS, Ledin TE, Odkvist LM et al. Recovery after acute unilateral vestibular loss and predictors for remaining symptoms. *American journal of otolaryngology* 2011; 32: 366–375. doi:10.1016/j.amjoto.2010.07.008
- [24] Adam SS, McDuffie JR, Ortel TL et al. Comparative effectiveness of warfarin and new oral anticoagulants for the management of atrial fibrillation and venous thromboembolism: a systematic review. *Annals of internal medicine* 2012; 157: 796–807. doi:10.7326/0003-4819-157-10-201211200-00532
- [25] Herman B, Angeli S. Differences in cochlear nerve cross-sectional area between normal hearing and postlingually deafened patients on MRI. *Otolaryngology-head and neck surgery: official journal of American Academy of Otolaryngology-Head and Neck Surgery* 2011; 144: 64–66. doi:10.1177/0194599810390884
- [26] Stimmer H, Niedermeyer HP, Stecher L et al. 3 T – MRI improves intrameatal cranial nerve detection in CI-candidates. *Acta oto-laryngologica* 2019; 139: 274–278. doi:10.1080/00016489.2019.1571281
- [27] Warninghoff JC. Schwindel – Charakterisierung von Patienten einer überregionalen Ambulanz und Entwicklung von Diagnoseindices [MD]. München: Ludwig-Maximilians-Universität München; 2009 104
- [28] Bayer O, Warninghoff JC, Straube A. Diagnostic indices for vertiginous diseases. *BMC neurology* 2010; 10: 98. doi:10.1186/1471-2377-10-98
- [29] R\_Development\_Core\_Team. R: A language and environment for statistical computing. In. 3.2.3 (2015-12-10) ed. Vienna: R Foundation for Statistical Computing; 2015
- [30] Cichetti D. Guidelines, criteria, and rules of thumb for evaluating normed and standardized assessment instruments in psychology. *Psychological Assessment* 1994; 6: 284–290
- [31] Fundakowski CE, Anderson J, Angeli S. Cross-sectional vestibular nerve analysis in vestibular neuritis. *The Annals of otology, rhinology, and laryngology* 2012; 121: 466–470
- [32] Kim HS, Kim DI, Chung IH et al. Topographical relationship of the facial and vestibulocochlear nerves in the subarachnoid space and internal auditory canal. *AJNR Am J Neuroradiol* 1998; 19: 1155–1161

- [33] David G, Seif M, Huber E et al. In vivo evidence of remote neural degeneration in the lumbar enlargement after cervical injury. *Neurology* 2019; 92: e1367–e1377. doi:10.1212/WNL.0000000000007137
- [34] Sarkies N. Traumatic optic neuropathy. *Eye* 2004; 18: 1122–1125. doi:10.1038/sj.eye.6701571
- [35] Byun H, Chung JH, Lee SH et al. Clinical value of 4-hour delayed gadolinium-Enhanced 3D FLAIR MR Images in Acute Vestibular Neuritis. *Laryngoscope* 2018; 128: 1946–1951. doi:10.1002/lary.27084
- [36] Teggi R, Caldirola D, Fabiano B et al. Rehabilitation after acute vestibular disorders. *The Journal of laryngology and otology* 2009; 123: 397–402. doi:10.1017/S0022215108002983
- [37] Deveze A, Bernard-Demanze L, Xavier F et al. Vestibular compensation and vestibular rehabilitation. Current concepts and new trends. *Neurophysiologie clinique = Clinical neurophysiology* 2014; 44: 49–57. doi:10.1016/j.neucli.2013.10.138
- [38] Yoo MH, Yang CJ, Kim SA et al. Efficacy of steroid therapy based on symptomatic and functional improvement in patients with vestibular neuritis: a prospective randomized controlled trial. *Eur Arch Otorhinolaryngol* 2017; 274: 2443–2451. doi:10.1007/s00405-017-4556-1