

A Gene-Based Classification of Primary Adrenocortical Hyperplasias

Authors

Fady Hannah-Shmouni , Constantine A. Stratakis

Affiliation

Section on Endocrinology & Genetics (SEGEN), NICHD, Bethesda, MD, USA

Key words

adrenal hyperplasia, Cushing syndrome, genetics, Carney complex, cyclic AMP, PPNAD, PMAH

received 11.11.2019

accepted 15.01.2020

Bibliography

DOI <https://doi.org/10.1055/a-1107-2972>

Horm Metab Res 2020; 52: 133–141

© Georg Thieme Verlag KG Stuttgart · New York

ISSN 0018-5043

Correspondence

Constantine A. Stratakis MD, D(Med) Sci., PhD(hc)
Senior Investigator and Scientific Director, Section on
Endocrinology & Genetics (SEGEN), The Eunice Kennedy
Shriver National Institute of Child Health and Human
Development National Institutes of Health
Building 10, CRC, Room 1-3330, 10 Center Dr., MSC1103
Bethesda
20892 Maryland
USA
Tel: +1 301 496 4686/496 6683, Fax: +1 301 402 0574/480
0378
stratak@mail.nih.gov

ABSTRACT

Primary or adrenocorticotropin-independent adrenocortical tumors and hyperplasias represent a heterogeneous group of adrenocortical neoplasms that arise from various genetic defects, either in isolation or familial. The traditional classification as adenomas, hyperplasias, and carcinomas is non-specific. The recent identification of various germline and somatic genes in the development of primary adrenocortical hyperplasias has provided important new insights into the molecular pathogenesis of adrenal diseases. In this new era of personalized care and genetics, a gene-based classification that is more specific is required to assist in the understanding of their disease processes, hormonal functionality and signaling pathways. Additionally, a gene-based classification carries implications for treatment, genetic counseling and screening of asymptomatic family members. In this review, we discuss the genetics of benign adrenocorticotropin-independent adrenocortical hyperplasias, and propose a new gene-based classification system and diagnostic algorithm that may aid the clinician in prioritizing genetic testing, screening and counseling of affected, at risk individuals and their relatives.

Introduction

Adrenocorticotropin (ACTH)-independent, primary adrenocortical tumors and hyperplasias are neoplasms of the adrenal cortex that arise due to perturbations in various key molecular pathways; for benign tumors cyclic AMP (cAMP)-signaling is the main pathway (► **Fig. 1**) [1]. Traditionally, ACTH-independent adrenocortical tumors and hyperplasias were classified into three major categories as adenomas, hyperplasias, and carcinomas [2]. This classification is non-specific for several reasons. First, it does not factor the various genetic defects and hormone functionality of these lesions. Second, causative genes in the predisposition and/or development of these lesions are increasing in number owing to the rapid adoption of genetic technologies in routine clinical practice and trans-

lational research. Third, these lesions may arise in the context of familial or syndromic conditions, which require careful phenotyping and genetic counseling of at risk individuals or their relatives. Thus, a more robust and specific classification system is required.

The various types of adrenocortical tumors and hyperplasias, their histology and genetics are described in ► **Table 1**. Translational research of primary adrenocortical hyperplasias have identified key molecular pathways involved in tumor formation (► **Fig. 1**) [3, 4]. The initial discovery of disease-causing activating variants in *GNAS*, which encodes the alpha subunit ($G\alpha$) of the stimulatory guanine nucleotide-binding protein (► **Fig. 1**) in primary adrenocortical hyperplasia of patients with McCune–Albright syndrome (MAS), was critical in establishing that cAMP signaling is involved

in adrenocortical tumorigenesis, if not in all, at least in cortisol-producing lesions [5–7]. Other early genetic discoveries included defects of the regulatory subunit type 1- α (R1 α) of protein kinase A (*PRKAR1A*) and protein kinase cAMP-activated catalytic subunit beta (*PRKACB*) [8] in Carney complex (CNC) [9], phosphodiesterases (*PDE11A*, *PDE8B*) in isolated micronodular adrenal hyperplasia (iMAD) [10], potassium voltage-gated channel subfamily J member 5 (*KCNJ5*) in aldosterone-producing adenomas (APA) [11], and *armadillo repeat containing 5* (*ARMC5*) in primary bilateral macronodular adrenocortical hyperplasia (PBMAH) [12]. In this review, we discuss the genetic and molecular mechanisms responsible for the formation of ACTH-independent adrenocortical hyperplasias and propose a new genetic classification given the most recent advances in gene discovery and to aid the clinician in the diagnosis and counseling of these conditions.

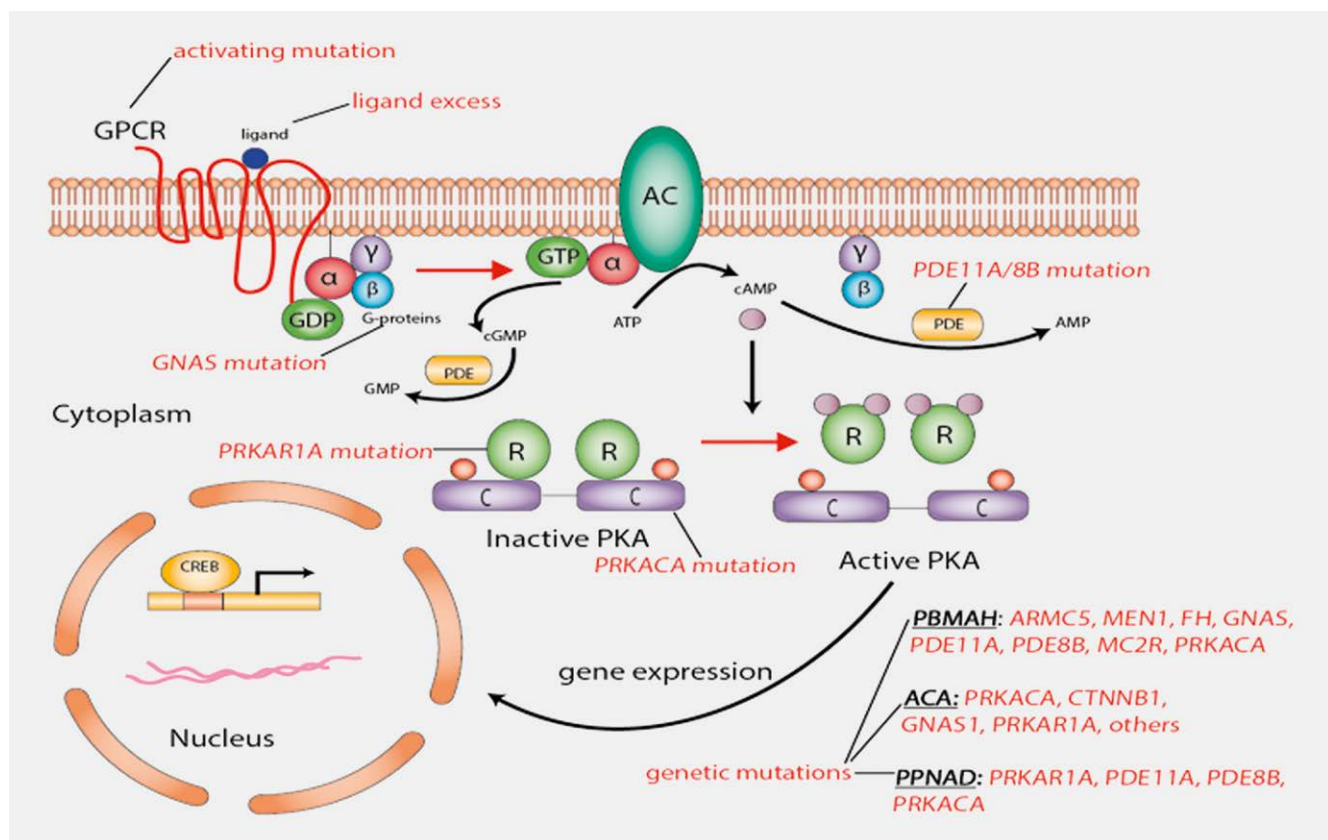
Molecular Pathways in Primary Adrenocortical Hyperplasias

The major molecular pathway that is perturbed in primary adrenocortical cortisol-producing neoplasms is the cAMP-signaling path-

way (►Fig. 1). Briefly, The G-protein coupled receptor for ACTH (ACTHR), also known as melanocortin 2 receptor (*MC2R*), is a seven-transmembrane receptor that undergoes extensive conformational changes in response to its ligand, ACTH (►Fig. 1). This leads to activation of adenylyl cyclase (AC) through the G proteins and the generation of cyclic AMP, activating protein kinase A (PKA), a holoenzyme that consists of a tetramer of two homo- or heterodimers regulatory subunits (R1 α , R1 β , R2 α and R2 β), and catalytic subunits (C α , C β , C γ and PRKX) that are encoded by the respective genes [13]. This in turn enables phosphorylation of PKA targets, including gene expression to mediate cell growth, differentiation and hormone production (e. g., cortisol and its pre-cursors). As shown in ►Fig. 1, genetic alterations in key genes of the cAMP-signaling pathway leads to the formation of various primary adrenocortical lesions.

Classification of Primary Adrenocortical Hyperplasia

In 2007, a comprehensive classification of ACTH-independent adrenocortical hyperplasia was proposed [2]. On histopathology,



►Fig. 1 The cyclic AMP-signaling pathways in primary adrenocortical cortisol-producing neoplasms. The G-protein coupled receptor for ACTH (ACTHR), also known as melanocortin 2 receptor (*MC2R*), is a seven-transmembrane receptor that undergoes extensive conformational changes in response to its ligand, ACTH. This leads to activation of adenylyl cyclase (AC) through the G proteins and the generation of cyclic AMP, activating protein kinase A (PKA), a holoenzyme that consists of a tetramer of two homo- or heterodimers regulatory subunits (R1 α , R1 β , R2 α and R2 β), and catalytic subunits (C α , C β , C γ and PRKX) that are encoded by the respective genes. This in turn enables phosphorylation of PKA targets, including gene expression to mediate cell growth, differentiation and hormone production (e. g., cortisol and its pre-cursors). Genetic alterations in key genes of the cAMP-signaling pathway leads to the formation of various primary adrenocortical lesions. AC: Adenylyl cyclase; C: Catalytic subunit of protein kinase A; cAMP: Cyclic AMP; CREB: Cyclic AMP response element binding protein, a transcription factor; GPCR: G-protein-coupled receptor; G α s, stimulatory subunit α of the G-protein; PDE11A: Phosphodiesterase 11A; PKA: cAMP-dependent protein kinase; R: Regulatory subunit.

these lesions are grossly divided into micro- (< 1 cm) and macro-nodular (> 1 cm) disease, a classification that primarily relies on the size of nodules [2]. Although size has biologic relevance [2], reliance on size alone may lead to erroneous classification of these nodules, as smaller or larger nodules can co-exist and/or be seen in either disease states. Additional tissue markers may help in the differentiation of the two processes, including the presence or absence of internodular hyperplasia or atrophy of the surrounding cortex (as in PBMAH) and pigmentation of the nodule or cortex (as in PPNAD) [2]. The most specific pigmentation is lipofuscin, a light to dark brown autofluorescent granularity of adrenal tissue which represents lysosomal residual bodies containing end products of oxidative damage to lipids [14]. Additional characteristics of these lesions includes sparing of the adrenal medulla and the persistence of cells that are probably derived from fetal adrenal precursors in the micronodular forms [15].

Macronodular adrenocortical hyperplasia

PBMAH is the most common subtype of macronodular adrenocortical hyperplasia. This condition is often bilateral and affects the adult population [16]. First described in 1964 [17], PBMAH has been referred to by many names which continues to pose confusion in medical literature, including massive macronodular adrenocortical disease (MMAD), bilateral macronodular adrenal hyperplasia (BMAH), ACTH-independent macronodular adrenocortical hyperplasia (AIMAH), autonomous macronodular adrenal hyperplasia (AMAD), primary macronodular adrenal hyperplasia (PMAH), ACTH-independent massive bilateral adrenal disease (AIMBAD), and “giant” or “huge” macronodular adrenal disease [18]. Asynchronous involvement of only one adrenal gland in PBMAH is rare [19]. After the recent discovery of a local intra-adrenal secretion of ACTH with an autocrine/paracrine effect on glucocorticoid secretion [20, 21] the term PBMAH has been favored, as a form of pituitary ACTH-independent hyperplasia.

On imaging, PBMAH is characterized by bilateral adrenal enlargement that is often multilobular. On pathology, PbMAH is represented by a dominant or multiple yellowish nodules (similar in color to normal adrenal tissue) with intervening hyperplasia or atrophy, consisting of lipid-rich and poor cells that form several island-like structures, devoid of dark pigmentation [17]. On histology, PBMAH can be divided into two types: Type 1 manifests with multiple nodules or discrete adenomas of various sizes (but typically over 1 cm) and internodular atrophy, while those with Type 2 have diffuse hyperplasia without internodular atrophy [22]. The combined weight of both adrenals in PBMAH ranges from 55–90 grams [16, 23].

PBMAH is a clinically heterogeneous disorder that is often associated with subclinical glucocorticoid and/or mineralocorticoid secretion in adults over a number of years. PBMAH may also manifest clinically with overt Cushing syndrome, associated with cortisol (or its precursor steroids) and/or other steroid hormone (including aldosterone) excess [22, 24]. Glucocorticoid and other steroid hormone secretion may be mediated by non-mutated but aberrantly expressed receptors through vasopressin, serotonin, catecholamines, gastric inhibitory polypeptide (GIP), luteinizing hormone, or autocrine/paracrine ACTH stimulation [25–28].

PBMAH was initially mostly reported as a sporadic disease but was found to be inherited in a dominant manner in several families. Recently, the tumor suppressor *ARMC5* was implicated in 20–50% of apparent sporadic and familial PBMAH cases, where both alleles carried one germline and one somatic disease-causing variant each [12, 19, 29, 30]. A second somatic event is required to mediate tumorigenesis and polyclonal nodularity, either 16p loss of heterozygosity or a somatic hit in *ARMC5* [31]. Interestingly, each nodule in PBMAH may harbor a ‘private’ disease-causing variant, thus tissues have defects that completely inactivate *ARMC5* [31].

Other genetic defects have been implicated in the pathogenesis of PBMAH, including the somatic activating variant of *GNAS* at codon Arg (201) without features of MAS [22, 32], the germline p.R867G variant of *PDE11A* in a patient with familial PBMAH [22], the several disease-causing germline variants of *PDE8B* [33], and germline variants in *FH*, *MEN1*, and *APC* in the context of familial syndromes as detailed below in this review [22, 32]. Very rarely, patients with familial PBMAH may carry germline duplications of *PRKACA* resulting in copy number gains [34, 35]. Possible disease-causing variants of the *MC2R* gene have also been reported in PBMAH [36]. A number of genomic/transcript abnormalities have been reported in PBMAH, including losses in 20q13 and 14q23 [7], overexpression of *WISP2*, *BCL2*, *E2F1*, *EGF*, *c-KIT*, *MYB*, *PRKACA*, and *CTNNB1*, which implicates various aberrant oncogenic pathways in nodular polyclonality and growth [37]. Chromatin deregulation of *DOT1L* and *HDAC9*, implicated in regulating gene transcription and cell proliferation have also been implicated in the pathogenesis of PBMAH [38].

Other rare subtypes of ACTH-independent macronodular adrenocortical hyperplasia include primary bimorphic adrenocortical disease (PBAD, as seen in MAS) and food-dependent Cushing syndrome (FDCS, also known as GIP-dependent Cushing syndrome). PBAD due to MAS is a congenital disorder that presents in the infantile period with severe hypercortisolism due to nodular adrenocortical hyperplasia with sharply defined zones of cortical atrophy that give the cortex a bimorphic appearance [5, 39]. PBAD is caused by constitutive activation of the cAMP-signaling pathway from postzygotic gain-of-function variants in *GNAS*, within exon 8 of the $G\alpha$ subunit (► Fig. 1) [7]. Moreover, the differential diagnosis of hypercortisolism in patients with MAS also includes bilateral “atypical” adenomas [40], isolated bilateral hyperplasia [41], and hyperplasia with spontaneous resolution [42] or improvement after unilateral adrenalectomy [43, 44].

In a rare form of FDCS, glucocorticoid excess is driven by aberrant glucose-dependent insulinotropic polypeptide receptor (GIPR) expression that arise from somatic duplications (within the adrenal lesions) in chromosome region 19q13.32 containing the *GIPR* locus [45]. GIP-dependent PBMAH should be distinguished from FDCS. The differential histopathologic characteristics and features of these lesions are summarized in ► Table 1.

Micronodular adrenocortical hyperplasia

Of the micronodular variety, PPNAD which is congenital and often bilateral is the most common subtype. PPNAD is either pigmented (c-PPNAD) as seen in CNC, or isolated (i-PPNAD); this condition has also been referred to non-specific nomenclatures, including micronodular adrenal disease and microadenomatosis or primary adren-

► **Table 1** Classification and characteristics of primary adrenocortical hyperplasia.

Adrenocortical lesions	Genes (locus)	Histopathology	Characteristics
PBMAH	<i>ARMC5</i> (16p11.2) <i>MEN1</i> (11q13) <i>FH</i> (1q42.3–43) <i>APC</i> (5q22.2) <i>PDE11A</i> (2q31.2) <i>PDE8B</i> (5q13.3) <i>GNAS</i> (20q13) <i>PRKACA</i> duplication (19p13.1)	Nodules or macroadenomatous, > 1 cm, with (type 1) or without (type 2) internodular atrophy Hyperplasia with dominant nodule	Middle age, mild hypercortisolism and/or mineralocorticoid excess Associated with MEN-1, FAP, MAS, HLRCS, isolated (AD) Most lesions have aberrant GPCRs (vasopressin, serotonin, catecholamines, GIP, luteinizing hormone) PMAH carry the ability of intra-adrenal production of ACTH with an autocrine/paracrine effect on glucocorticoid or mineralocorticoid production
PBAD	<i>GNAS</i> (20q13; mosaic)	Distinct adenomas (> 1 cm), with occasional microadenomas and internodular atrophy	Infants and very young children MAS
FDGS (GIP-dependent)	<i>GIPR</i> gene (19q13.32) duplication	Large adenomas and/or macronodules	Isolated or familial aberrant GPCRs (GIPR), low fasting cortisol, hypercortisolism post-meals
i-PPNAD	<i>PRKAR1A</i> (17q22–24) <i>PRKACA</i> duplications (19p13.1)	Microadenomatous (< 1 cm) hyperplasia with pigmentation	Children and young adults Lentiginosis in few cases
c-PPNAD	<i>PRKAR1A</i> (17q22–24, <i>CNC1</i> locus) 2p16 (<i>CNC2</i> locus, unknown gene)	Microadenomatous (< 1 cm) hyperplasia with (mostly) internodular atrophy and pigmentation	Children, young and middle aged adults Disease at a younger age and a higher frequency of myxomas, schwannomas, and thyroid and gonadal tumors than patients without <i>PRKAR1A</i> variants. In-frame deletion of exon 3 and the c.708 + 1G>T appears to confer a more severe <i>CNC</i> phenotype, while the splice variant c.709(-7–2)del6 and the initiation alternating substitution c.1A>G/p.M1Vp has been associated with incomplete penetrance of <i>CNC</i> , as seen in i-PPNAD <i>CNC1</i> : The hot spot c.491–492delTG is most closely associated with lentiginosis, cardiac myxoma, and thyroid tumors when opposed to all other <i>PRKAR1A</i> variants Expressed R1α mutant protein present with more severe and aggressive <i>CNC</i> -phenotype <i>CNC2</i> : Sporadic disease later in life with a lower frequency of myxomas, schwannomas, thyroid and LCCSCT
iMAD	<i>PDE11A</i> (2q31.2) <i>PDE8B</i> (5q13) <i>PRKACA</i> (19p13.1) 2p16 (unknown gene)	Microadenomatous (< 1 cm) hyperplasia with internodular hyperplasia and limited or absent pigmentation	Mostly children and young adults Cyclical hypercortisolism May be associated with a paradoxical rise of glucocorticoid excretion during the Liddle's test Isolated or AD

APC: Adenomatous polyposis coli gene; c-PPNAD: *CNC*-associated primary pigmented nodular adrenocortical disease; *CNC*: Carney complex; FAP: Familial adenomatous polyposis; FDGS: Food-dependent Cushing syndrome; *GNAS*: Gene coding for the stimulatory subunit α of the G-protein ($G_{\alpha s}$); GPCR: G-protein-coupled receptor; HLRCS: Hereditary leiomyomatosis and renal cancer syndrome; i-MAD: Isolated micronodular adrenocortical disease; i-PPNAD: Isolated PPNAD; LCCSCT: Large cell calcifying Sertoli cell tumor; MAS: McCune–Albright syndrome; MEN1: Multiple endocrine neoplasia type 1; PBAD: Primary bimorphic adrenocortical disease; PBNMAH: Primary bilateral macronodular adrenocortical hyperplasia; PDE8B: Phosphodiesterase 8B gene; PDE11A: Phosphodiesterase 11A gene; PRKAR1A: Protein kinase, cAMP-dependent, regulatory, type I, α gene.

ocortical nodular dysplasia with foci of eosinophilic giant cells [46]. The term PPNAD was coined by Dr J. Aidan Carney (Mayo Clinic, Rochester, Minnesota, United States) in 1984 [47]. PPNAD presents as multiple, small, pigmented nodules (~6 mm in size) with internodular cortical atrophy [18]. Unlike in PMAH, the adrenal glands in PPNAD have several pathognomonic features including abnormal adrenal contour on imaging, smaller in size than in PBMAH (15–25 grams), darkly pigmented (brown or black nodules) and there is usually internodular cortical atrophy (reflecting atrophy of the 'normal' ACTH-dependent cortex) [18]. c-PPNAD is inherited in an autosomal dominant manner and has been linked to three major loci: c-PPNAD is primarily caused by inactivating variants in *PRKAR1A* (*CNC1* locus) [9]. Rarely, *CNC* is caused by a yet to be identified

gene that is mapped to chromosome 2 (*CNC2* locus on 2p16) [48]. Activation of the cAMP pathway in PPNAD leads to upregulation of serotonin (5-HT) synthesizing enzyme tryptophan hydroxylase (TPH) and its receptors (5-HT₄, 5-HT₆, and 5-HT₇).

It should be noted that *CNC* may also be caused by *PRKACB* amplification (*CNC3* locus) [8]; *PRKACB* codes for the PKA catalytic subunit beta ($C\beta$) (► **Fig. 1**). Defects in *PRKACB* have not been linked to PPNAD despite its association with other manifestations of *CNC*.

iMAD represents a distinct and rare disorder of the adrenal glands that manifests with hypercortisolism of very early onset [2]. First described in 2004, iMAD is regarded as a separate entity from PPNAD, with earlier onset of clinical manifestations, cyclicity of hypercortisolism, and clinically manifesting in isolation; however,

► **Table 2** Familial syndromes associated with primary adrenocortical hyperplasias.

Familial syndromes	Gene (locus)	Mode of inheritance	Major features
Carney complex	<i>PRKAR1A</i> (17q22–24, CNC1 locus) 2p16 (CNC2 locus, gene unknown) <i>PRKACB</i> (1p31.1, CNC3 locus)	AD	<ul style="list-style-type: none"> PPNAD Cardiac myxomas Pigmented skin lesions (lentiginosis and blue nevi) Somatotroph-pituitary adenomas LCCSCT Benign thyroid nodules, differentiated thyroid cancer Melanocytic schwannomas
Multiple Endocrine Neoplasia Type 1	<i>MEN1</i> (11q13)	AD	<ul style="list-style-type: none"> Primary hyperparathyroidism Pituitary adenomas Neuroendocrine neoplasms Skin lesions Adrenal tumors, including PBMAH
Familial Adenomatous Polyposis	<i>APC</i> (5q22.2)	AD	<ul style="list-style-type: none"> Large pre-cancerous colorectal polyps in the second and third decade of life Adrenocortical tumors, including adrenocortical cancer and PBMAH Papillary thyroid carcinomas Lipomas Pancreatic carcinomas
Hereditary Leiomyomatosis and Renal Cell Cancer	<i>FH</i> (1q42.3–43)	AD	<ul style="list-style-type: none"> Hereditary leiomyomatosis Renal cancer Adrenocortical tumors, including PBMAH

APC: Adenomatous polyposis coli gene; c-PPNAD: CNC-associated primary pigmented nodular adrenocortical disease; CNC: Carney complex; FAP: Familial adenomatous polyposis; FDGS: Food-dependent Cushing syndrome; GNAS: Gene coding for the stimulatory subunit α of the G-protein ($G_{\alpha s}$); GPCR: G-protein-coupled receptor; HLRCs: Hereditary leiomyomatosis and renal cancer syndrome; i-MAD: Isolated micronodular adrenocortical disease; i-PPNAD: Isolated PPNAD; LCCSCT: Large cell calcifying Sertoli cell tumor; MAS: McCune–Albright syndrome; MEN1: Multiple endocrine neoplasia type 1; PBAD: Primary bimorphic adrenocortical disease; PBMAH: Primary bilateral macronodular adrenocortical hyperplasia; PDE8B: phosphodiesterase 8B gene; PDE11A: phosphodiesterase 11A gene; PRKAR1A: Protein kinase, cAMP-dependent, regulatory, type I, α gene.

these two entities share several features including micronodularity, paradoxical rise of glucocorticoid excretion during the Liddle’s test (1 mg overnight and low and high dose dexamethasone suppression tests) [49], and autosomal dominant inheritance in some cases [50, 51]. On pathology, iMAD is characterized by multiple small yellow-to-dark brown nodules surrounded by a cortex with a uniform appearance, which leads to capsular deficits resulting in extra-adrenal cortical excrescences and moderate diffuse cortical hyperplasia [2, 51, 52]. This disease is highly heterogeneous, and disease-causing variants in *PDE11A* [52, 53], *PDEB8* [10, 52], or germline duplications of *PRKACA* [34, 35, 54] have been implicated in its pathogenesis. Micronodular adrenocortical hyperplasias mainly produce cortisol and/or its pre-cursors, although non-cortisol producing lesions exist (unpublished data) but have not been extensively studied [15].

Familial Syndromes Associated with Primary Adrenocortical Hyperplasia

Several monogenic disorders have been associated with the development of primary adrenocortical hyperplasias (► **Table 2**). The following section briefly enlists these conditions.

Carney Complex (CNC)

CNC is an autosomal dominant multiple neoplasia syndrome arising from genetic alterations in three loci, *PRKAR1A* (which codes for R1 α subunit of PKA and is known as the CNC1 locus), 2p16 (CNC2), and *PRKACB* amplification (CNC3 locus) [55]. Most disease-causing variants are caused by inactivating variants in R1 α of PKA that are spread along the whole coding sequence [9, 56]. The clinical manifestations of CNC include PPNAD (more than 60% of patients with CNC have clinically detectable PPNAD), cardiac myxomas, various pigmented skin lesions, growth-hormone excess due to somatotroph-pituitary hyperplasia, benign large cell calcifying Sertoli cell tumor of the testis, thyroid lesions and melanocytic schwannomas. CNC does not predispose to macronodular adrenocortical hyperplasia.

Multiple Endocrine Neoplasia Type 1 (MEN-1)

MEN-1 is an autosomal dominant condition that arises from heterozygous disease-causing inactivating germline variants of *MEN1* (11q13) [57]. The clinical manifestations of MEN-1 include primary hyperparathyroidism (>95%), skin lesions (>90%), pituitary adenomas (45%), and neuroendocrine neoplasms (>30%). Adrenal enlargement are seen in approximately 20.4% (146/715) of patients with MEN-1. MEN-1 may predispose to PBMAH (10.1% of the

cohort) [22, 58]. It is not known if MEN-1 predisposes to micronodular adrenocortical hyperplasia.

Familial Adenomatous Polyposis (FAP)

FAP is an autosomal dominant condition that arise from the tumor suppressor gene *APC*. The clinical manifestations include large pre-cancerous colorectal polyps, primary adrenocortical lesions including PBMAH, papillary thyroid carcinomas, lipomas, and pancreatic carcinomas. PBMAH is an infrequent manifestation of FAP [22]. It is not known if FAP predisposes to micronodular adrenocortical hyperplasia.

Hereditary Leiomyomatosis and Renal Cell Cancer (HLRCS)

HLRCC is an autosomal dominant condition arising from disease-inactivating variants of the mitochondrial enzyme fumarate hydratase (*FH*). Clinical manifestations include hereditary leiomyomatosis, renal cancer, and adrenal lesions. HLRCC predisposes to PMAH and/or adrenocortical adenomas that can be non-functional [22, 59, 60], although the first demonstration of *FH*'s involvement in adrenocortical tumors was in a patient with PBMAH and mostly subclinical hypercortisolism [59].

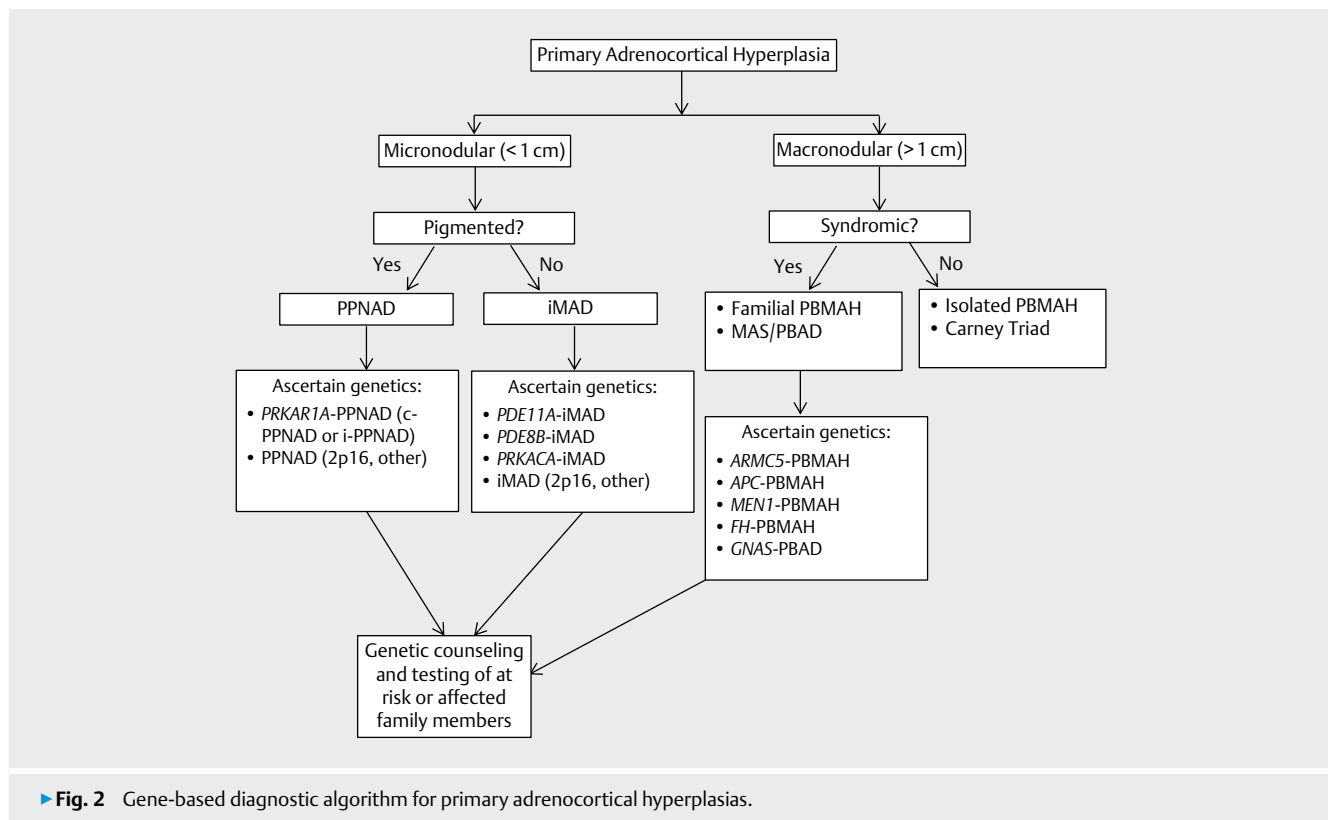
Carney Triad (CT)

CT is a sporadic condition from an unknown genetic defect with a female predominance. In CT, patients harbor a recurrent aberrant

DNA methylation of the promoter region of the *SDHC* gene [61]. This condition predisposes to hamartomatous lesions in various organs (such as pulmonary chondromas), gastrointestinal stromal tumors, pheochromocytoma, and esophageal leiomyoma [62]. CT is the only known adrenal condition that has among its clinical manifestations both adrenocortical and medullary involvement; in fact, adrenal lesions are the fourth component of this condition, which includes PMAH and/or adrenocortical adenomas that are mostly non-functional [63].

Genetic Classification, Testing and Counseling of Patients with Familial Primary Adrenocortical Hyperplasias

Advances in the field of genetics and genomics has substantially progressed and informed our understanding of the molecular pathogenesis of sporadic and familial forms of primary adrenocortical hyperplasias. In keeping with the growing list of genes implicated in the pathogenesis of these lesions, and to better serve genetic testing and counseling of affected or at risk patients, a gene-based classification in which patients are grouped based on the presence of disease-causing germline variants or other genetic alterations is required (► Fig. 2). This classification will highlight the causative genes, which may aid with prioritizing genetic testing and/or counseling of affected family members. Additionally, this approach may decrease the risk of misclassifying familial cases as sporadic. An example of such a classification system includes listing the implicated gene name before the type of hyperplasia, such as *ARMC5*-PBMAH, *MEN1*-PBMAH, *PRKAR1A*-CNC, and *PDE11A*-iM-



AD (► Fig. 2). As there are yet unidentified molecular cause(s) of these adrenocortical hyperplasias [15], we anticipate a growing number of genes implicated in these disorders over the next decades and a robust, flexible and easy to follow classification system is thus required.

Since most familial forms of adrenocortical hyperplasias are inherited in an autosomal dominant manner, establishing a causative gene is important for understanding the disease mechanisms, mode of inheritance and usefulness of cascade screening. Although the genotype-phenotype correlation is often times unpredictable, providing specific screening and counseling could decrease a patient's anxiety towards this uncertainty, decrease genetic discrimination and ensure appropriate disease surveillance. Genetic screening may begin as early as infancy in at risk individuals, especially in CNS or iMAD from MAS. A successful patient counseling model should incorporate the patient's values and attitudes toward their disease, while underscoring the risks and benefits of genetic screening and counseling, psychosocial interventions and service delivery [64].

In the context of *ARMC5*-PBMAH or *PDE11A*-iMAD/PBMAH, the penetrance is decreased and first-degree relatives that are carriers may not be affected. Therefore, all first-degree relatives with a known carrier state should be referred for genetic counseling and phenotype-directed biochemical screening per established clinical guidelines. Family screening of *ARMC5*, as with the other genes as listed in ► Table 1 and ► 2, will allow early detection of carriers, and prospective follow up. Genetic testing should be offered when an individual is free to refuse or accept the test according to their wishes and moral beliefs. Children should not be tested for these low penetrant genes unless there is clinical evidence of disease.

Conclusions

The identification of several genetic causes of primary adrenocortical hyperplasias, primarily in the cAMP-signaling pathways, have paved the way for large-scale clinical and molecular studies and future research. The traditional classification as adenomas, hyperplasias and carcinomas is non-specific and has added confusion to the nomenclature of these lesions. In this new era of personalized care and genetics, a gene-based classification that is more specific is required to assist in the understanding of their disease processes, hormonal functionality and signaling pathways. Additionally, a gene-based classification carries implications for treatment, genetic counseling and screening of asymptomatic family members.

Author and Contributors

All authors contributed equally to the conception or design of the work; or the acquisition, analysis, or interpretation of data for the work; and drafting the work or revising it critically for important intellectual content; and final approval of the version to be published; and agreement to be accountable for all aspects of the work in ensuring that questions related to the accuracy or integrity of any part of the work are appropriately investigated and resolved.

Funding Information

This work was supported by the intramural program of the *Eunice Kennedy Shriver* National Institute of Child Health & Human Development, National Institutes of Health (NIH), protocol HD008920. Dr. Stratakis has patents on the *PRKAR1A*, *PDE11A*, and *GPR101* genes and his laboratory has recently received research funding from Pfizer Inc.

Conflict of Interest

Dr. Stratakis holds patents on the *PRKAR1A*, *PDE11A*, *GPR101* genes and/or their function and his laboratory has received support from Pfizer Inc on research on *GPR101* and acromegaly.

References

- [1] Bimpaki EI, Nesterova M, Stratakis CA. Abnormalities of cAMP signaling are present in adrenocortical lesions associated with ACTH-independent Cushing syndrome despite the absence of mutations in known genes. *Eur J Endocrinol* 2009; 161: 153–161
- [2] Stratakis CA, Boikos SA. Genetics of adrenal tumors associated with Cushing's syndrome: A new classification for bilateral adrenocortical hyperplasias. *Nat Clin Pract Endocrinol Metab* 2007; 3: 748–757
- [3] Stratakis CA. New genes and/or molecular pathways associated with adrenal hyperplasias and related adrenocortical tumors. *Mol Cell Endocrinol* 2009; 300: 152–157
- [4] Stratakis CA. Adrenocortical tumors, primary pigmented adrenocortical disease (PPNAD)/Carney complex, and other bilateral hyperplasias: The NIH studies. *Horm Metab Res* 2007; 39: 467–473
- [5] Carney JA, Young WF, Stratakis CA. Primary bimorphic adrenocortical disease: Cause of hypercortisolism in McCune-Albright syndrome. *Am J Surg Pathol* 2011; 35: 1311–1326
- [6] Boston BA, Mandel S, LaFranchi S et al. Activating mutation in the stimulatory guanine nucleotide-binding protein in an infant with Cushing's syndrome and nodular adrenal hyperplasia. *J Clin Endocrinol Metab* 1994; 79: 890–893
- [7] Weinstein LS, Shenker A, Gejman PV et al. Activating mutations of the stimulatory G protein in the McCune-Albright syndrome. *N Engl J Med* 1991; 325: 1688–1695
- [8] Forlino A, Vetro A, Garavelli L et al. *PRKACB* and Carney complex. *N Engl J Med* 2014; 370: 1065–1067
- [9] Kirschner LS, Carney JA, Pack SD et al. Mutations of the gene encoding the protein kinase A type I-alpha regulatory subunit in patients with the Carney complex. *Nat Genet* 2000; 26: 89–92
- [10] Horvath A, Mericq V, Stratakis CA. Mutation in *PDE8B*, a cyclic AMP-specific phosphodiesterase in adrenal hyperplasia. *N Engl J Med* 2008; 358: 750–752
- [11] Choi M, Scholl UI, Yue P et al. K⁺ channel mutations in adrenal aldosterone-producing adenomas and hereditary hypertension. *Science* 2011; 331: 768–772
- [12] Assie G, Libe R, Espiard S et al. *ARMC5* mutations in macronodular adrenal hyperplasia with Cushing's syndrome. *N Engl J Med* 2013; 369: 2105–2114
- [13] Taylor SS, Ilouz R, Zhang P et al. Assembly of allosteric macromolecular switches: lessons from PKA. *Nat Rev Mol Cell Biol* 2012; 13: 646–658
- [14] Mochizuki Y, Park MK, Mori T et al. The difference in autofluorescence features of lipofuscin between brain and adrenal. *Zoolog Sci* 1995; 12: 283–288

- [15] Stratakis CA. cAMP/PKA signaling Defects in tumors: Genetics and tissue-specific pluripotential cell-derived lesions in human and mouse. *Mol Cell Endocrinol* 2013; 371: 208–220
- [16] Zeiger MA, Nieman LK, Cutler GB et al. Primary bilateral adrenocortical causes of Cushing's syndrome. *Surgery* 1991; 110: 1106–1115
- [17] Kirschner MA, Powell RD Jr., Lipsett MB. Cushing's Syndrome: Nodular cortical hyperplasia of adrenal glands with clinical and pathological features suggesting adrenocortical tumor. *J Clin Endocrinol Metab* 1964; 24: 947–955
- [18] Stratakis CA, Kirschner LS. Clinical and genetic analysis of primary bilateral adrenal diseases (micro- and macronodular disease) leading to Cushing syndrome. *Horm Metab Res* 1998; 30: 456–463
- [19] Alencar GA, Lerario AM, Nishi MY et al. ARMC5 mutations are a frequent cause of primary macronodular adrenal Hyperplasia. *J Clin Endocrinol Metab* 2014; 99: E1501–E1509
- [20] Louiset E, Duparc C, Young J et al. Intraadrenal corticotropin in bilateral macronodular adrenal hyperplasia. *N Engl J Med* 2013; 369: 2115–2125
- [21] Lefebvre H, Duparc C, Chartrel N et al. Intraadrenal adrenocorticotropin production in a case of bilateral macronodular adrenal hyperplasia causing Cushing's syndrome. *J Clin Endocrinol Metab* 2003; 88: 3035–3042
- [22] Hsiao HP, Kirschner LS, Bourdeau I et al. Clinical and genetic heterogeneity, overlap with other tumor syndromes, and atypical glucocorticoid hormone secretion in adrenocorticotropin-independent macronodular adrenal hyperplasia compared with other adrenocortical tumors. *J Clin Endocrinol Metab* 2009; 94: 2930–2937
- [23] Lieberman SA, Eccleshall TR, Feldman D. ACTH-independent massive bilateral adrenal disease (AIMBAD): A subtype of Cushing's syndrome with major diagnostic and therapeutic implications. *Eur J Endocrinol* 1994; 131: 67–73
- [24] Bourdeau I, Lampron A, Costa MH, Tadjine M, Lacroix A. Adrenocorticotrophic hormone-independent Cushing's syndrome. Current opinion in endocrinology, diabetes, and obesity 2007; 14: 219–2125
- [25] Bourdeau I, D'Amour P, Hamet P et al. Aberrant membrane hormone receptors in incidentally discovered bilateral macronodular adrenal hyperplasia with subclinical Cushing's syndrome. *J Clin Endocrinol Metab* 2001; 86: 5534–5540
- [26] Lacroix A, Bourdeau I, Lampron A et al. Aberrant G-protein coupled receptor expression in relation to adrenocortical overfunction. *Clin Endocrinol* 2010; 73: 1–15
- [27] Berthon A, Hannah-Shmouni F, Maria AG et al. High expression of adrenal P450 aromatase (CYP19A1) in association with ARMC5-primary bilateral macronodular adrenocortical hyperplasia. *J Steroid Biochem Mol Biol* 2019; 191: 105316
- [28] Hannah-Shmouni F, Moraitis AG, Romero VV et al. Successful treatment of estrogen excess in primary bilateral macronodular adrenocortical hyperplasia with leuprolide acetate. *Horm Metab Res* 2018; 50: 124–132
- [29] Faucz FR, Zilbermint M, Lodish MB et al. Macronodular adrenal hyperplasia due to mutations in an armadillo repeat containing 5 (ARMC5) gene: A clinical and genetic investigation. *J Clin Endocrinol Metab* 2014; 99: E1113–E1119
- [30] Kyo C, Usui T, Kosugi R et al. ARMC5 Alterations in Primary Macronodular Adrenal Hyperplasia (PMAH) and the Clinical State of Variant Carriers. *J Endocr Soc* 2019; 3: 1837–1846
- [31] Correa R, Zilbermint M, Berthon A et al. The ARMC5 gene shows extensive genetic variance in primary macronodular adrenocortical hyperplasia. *Eur J Endocrinol* 2015; 173: 435–440
- [32] Fragoso MC, Domenice S, Latronico AC et al. Cushing's syndrome secondary to adrenocorticotropin-independent macronodular adrenocortical hyperplasia due to activating mutations of GNAS1 gene. *J Clin Endocrinol Metab* 2003; 88: 2147–2151
- [33] Rothenbuhler A, Horvath A, Libe R et al. Identification of novel genetic variants in phosphodiesterase 8B (PDE8B), a cAMP-specific phosphodiesterase highly expressed in the adrenal cortex, in a cohort of patients with adrenal tumours. *Clin Endocrinol (Oxf)* 2012; 77: 195–199
- [34] Beuschlein F, Fassnacht M, Assie G et al. Constitutive activation of PKA catalytic subunit in adrenal Cushing's syndrome. *N Engl J Med* 2014; 370: 1019–1028
- [35] Lodish MB, Yuan B, Levy I et al. Germline PRKACA amplification causes variable phenotypes that may depend on the extent of the genomic defect: Molecular mechanisms and clinical presentations. *Eur J Endocrinol* 2015; 172: 803–811
- [36] Swords FM, Baig A, Malchoff DM et al. Impaired desensitization of a mutant adrenocorticotropin receptor associated with apparent constitutive activity. *Mol Endocrinol* 2002; 16: 2746–2753
- [37] Almeida MQ, Harran M, Bimpaki EI et al. Integrated genomic analysis of nodular tissue in macronodular adrenocortical hyperplasia: Progression of tumorigenesis in a disorder associated with multiple benign lesions. *J Clin Endocrinol Metab* 2011; 96: E728–E738
- [38] Cao Y, He M, Gao Z et al. Activating hotspot L205R mutation in PRKACA and adrenal Cushing's syndrome. *Science* 2014; 344: 913–917
- [39] Kirk JM, Brain CE, Carson DJ et al. Cushing's syndrome caused by nodular adrenal hyperplasia in children with McCune-Albright syndrome. *J Pediatr* 1999; 134: 789–792
- [40] Benjamin DR, McRoberts JW. Polyostotic fibrous dysplasia associated with Cushing syndrome. *Arch Pathol* 1973; 96: 175–178
- [41] Paris F, Philibert P, Lumbroso S et al. Isolated Cushing's syndrome: An unusual presentation of McCune-Albright syndrome in the neonatal period. *Horm Res* 2009; 72: 315–319
- [42] Gillis D, Rosler A, Hannon TS et al. Prolonged remission of severe Cushing syndrome without adrenalectomy in an infant with McCune-Albright syndrome. *J Pediatr* 2008; 152: 882–884 e1–4
- [43] Hamajima T, Maruwaka K, Homma K et al. Unilateral adrenalectomy can be an alternative therapy for infantile onset Cushing's syndrome caused by ACTH-independent macronodular adrenal hyperplasia with McCune-Albright syndrome. *Endocr J* 2010; 57: 819–824
- [44] Brown RJ, Kelly MH, Collins MT. Cushing syndrome in the McCune-Albright syndrome. *J Clin Endocrinol Metab* 2010; 95: 1508–1515
- [45] Lecoq AL, Stratakis CA, Viengchareun S et al. Adrenal GIPR expression and chromosome 19q13 microduplications in GIP-dependent Cushing's syndrome. *JCI Insight* 2017; 2: e92184
- [46] Schweizer-Cagianut M, Froesch ER, Hedinger C. Familial Cushing's syndrome with primary adrenocortical microadenomatosis (primary adrenocortical nodular dysplasia). *Acta Endocrinol (Copenh)* 1980; 94: 529–535
- [47] Shenoy BV, Carpenter PC, Carney JA. Bilateral primary pigmented nodular adrenocortical disease. Rare cause of the Cushing syndrome. *Am J Surg Pathol* 1984; 8: 335–344
- [48] Stratakis CA, Carney JA, Lin JP et al. Carney complex, a familial multiple neoplasia and lentiginosis syndrome. Analysis of 11 kindreds and linkage to the short arm of chromosome 2. *J Clin Invest* 1996; 97: 699–705
- [49] Husebye ES, Allolio B, Arlt W et al. Consensus statement on the diagnosis, treatment and follow-up of patients with primary adrenal insufficiency. *J Intern Med* 2014; 275: 104–115
- [50] Gunther DF, Bourdeau I, Matyakhina L et al. Cyclical Cushing syndrome presenting in infancy: An early form of primary pigmented nodular adrenocortical disease, or a new entity? *J Clin Endocrinol Metab* 2004; 89: 3173–3182
- [51] Carney JA, Gaillard RC, Bertherat J et al. Familial micronodular adrenocortical disease, Cushing syndrome, and mutations of the gene encoding phosphodiesterase 11A4 (PDE11A). *Am J Surg Pathol* 2010; 34: 547–555

- [52] Horvath A, Giatzakis C, Tsang K et al. A cAMP-specific phosphodiesterase (PDE8B) that is mutated in adrenal hyperplasia is expressed widely in human and mouse tissues: A novel PDE8B isoform in human adrenal cortex. *Eur J Hum Genet* 2008; 16: 1245–1253
- [53] Horvath A, Boikos S, Giatzakis C et al. A genome-wide scan identifies mutations in the gene encoding phosphodiesterase 11A4 (PDE11A) in individuals with adrenocortical hyperplasia. *Nat Genet* 2006; 38: 794–800
- [54] Carney JA, Lyssikatos C, Lodish MB et al. Germline PRKACA amplification leads to Cushing syndrome caused by 3 adrenocortical pathologic phenotypes. *Hum Pathol* 2015; 46: 40–49
- [55] Stratakis CA, Kirschner LS, Carney JA. Clinical and molecular features of the Carney complex: diagnostic criteria and recommendations for patient evaluation. *J Clin Endocrinol Metab* 2001; 86: 4041–4046
- [56] Horvath A, Bertherat J, Groussin L et al. Mutations and polymorphisms in the gene encoding regulatory subunit type 1-alpha of protein kinase A (PRKAR1A): An update. *Hum Mutat* 2010; 31: 369–379
- [57] Chandrasekharappa SC, Guru SC, Manickam P et al. Positional cloning of the gene for multiple endocrine neoplasia-type 1. *Science* 1997; 276: 404–407
- [58] Gatta-Cherifi B, Chabre O, Murat A et al. Adrenal involvement in MEN1. Analysis of 715 cases from the Groupe d'etude des Tumeurs Endocrines database. *Eur J Endocrinol* 2012; 166: 269–279
- [59] Matyakhina L, Freedman RJ, Bourdeau I et al. Hereditary leiomyomatosis associated with bilateral, massive, macronodular adrenocortical disease and atypical cushing syndrome: A clinical and molecular genetic investigation. *J Clin Endocrinol Metab* 2005; 90: 3773–3779
- [60] Lehtonen HJ, Kiuru M, Ylisaukko-Oja SK et al. Increased risk of cancer in patients with fumarate hydratase germline mutation. *J Med Genet* 2006; 43: 523–526
- [61] Haller F, Moskalev EA, Faucz FR et al. Aberrant DNA hypermethylation of SDHC: A novel mechanism of tumor development in Carney triad. *Endocr Relat Cancer* 2014; 21: 567–577
- [62] Carney JA, Sheps SG, Go VL et al. The triad of gastric leiomyosarcoma, functioning extra-adrenal paraganglioma and pulmonary chondroma. *N Engl J Med* 1977; 296: 1517–1518
- [63] Carney JA, Stratakis CA, Young WF Jr.. Adrenal cortical adenoma: the fourth component of the Carney triad and an association with subclinical Cushing syndrome. *Am J Surg Pathol* 2013; 37: 1140–1149
- [64] Raygada M, King KS, Adams KT et al. Counseling patients with succinate dehydrogenase subunit defects: Genetics, preventive guidelines, and dealing with uncertainty. *J Pediatr Endocrinol Metab* 2014; 27: 837–844