

Performance of two Methods for Cardiac MRI Edema Mapping: Dual-Contrast Fast Spin-Echo and T₂ Prepared Balanced Steady State Free Precession

Leistung zweier Methoden für kardiale MR-Ödembildgebung: Doppelkontrast-Fast-Spin-Echo und T₂-präparierte balanced Steady State Free Precession

Authors

Patrick Krumm¹, Petros Martirosian², Dominik Rath³, Meinrad Gawaz³, Konstantin Nikolaou¹, Bernhard Daniel Klumpp¹, Andreas Hornung⁴, Ulrich Kramer¹, Fritz Schick², Tobias Geisler³, Tanja Zitzelsberger¹

Affiliations

- 1 Diagnostic and Interventional Radiology, University of Tübingen, Germany
- 2 Section on Experimental Radiology, University of Tübingen, Germany
- 3 Cardiology and Cardiovascular Medicine, University of Tübingen, Germany
- 4 Pediatric Cardiology, University of Tübingen, Germany

Key words

heart, cardiac, imaging sequences, ischemia/infarction, edema, MR imaging

received 24.07.2019

accepted 17.12.2019

Bibliography

DOI <https://doi.org/10.1055/a-1088-3478>

Published online: 4.2.2020

Fortschr Röntgenstr 2020; 192: 669–677

© Georg Thieme Verlag KG, Stuttgart · New York

ISSN 1438-9029

Correspondence

Dr. Patrick Krumm

Diagnostische und Interventionelle Radiologie,
Universitätsklinikum Tübingen, Hoppe-Seyler-Str. 3,
72076 Tübingen, Germany
Tel.: ++49/070 71/2 98 66 76
patrick.krumm@uni-tuebingen.de

ZUSAMMENFASSUNG

Ziel Vergleich von richtig positiven und falsch negativen Werten bei myokardialem Ödem-Mapping zweier Methoden. Der Ödemnachweis mittels MRT kann schwierig sein.

Material und Methoden 76 Patienten (Alter 59 ± 11 Jahre, 15 weiblich) mit akutem Myokardinfarkt (MI) und 10 gesunde Probanden wurden prospektiv in diese am Einzelzentrum durchgeführte Studie eingeschlossen. Im Median 2,5 Tage nach Revaskularisation wurde eine Herz-MRT bei 1,5 T zum

Ödem-Mapping durchgeführt: Eine Steady-State-Free-Precession (SSFP)-Mapping-Sequenz mit T₂-Präparationspulsen (T₂prep) sowie ein Dual-contrast-Fast-Spin-Echo (dcFSE)-Signalzerfall-Ödem-Mapping. Als Referenz für ein zu erwartendes Ödem im akut infarzierten Myokard wurde Late-Gadolinium-Enhancement (LGE) eingesetzt.

Ergebnisse 311 Myokardsegmente in Patienten waren akut infarziert, mit einem mittleren T₂ von 73 ms für T₂prep-SSFP vs. 87 ms für dcFSE-Ödem-Mapping. In gesunden Probanden war das mittlere myokardiale T₂ 56 ms für T₂prep-SSFP vs. 50 ms für dcFSE-Ödem-Mapping. Operationscharakteristiken eines Beobachters (ROC-Kurven) für T₂prep-SSFP zeigten eine Fläche unter der Optimierungskurve (AUC) von 0,962, p < 0,0001, Youden-Index J 0,8266, assoziierter Schwellenwert > 60 ms, Sensitivität 94 %, Spezifität 89 %. Für dcFSE war die ROC-AUC 0,979, p < 0,0001, J 0,9219, assoziierter Schwellenwert > 64 ms, Sensitivität 93 %, Spezifität 99 %.

Schlussfolgerung Beide Methoden zum Ödem-Mapping erfassen ein höhergradiges Ödem mit hoher Sensitivität. Dennoch kann ein Ödem mit beiden Mapping-Methoden auch bei akutem Infarkt fokal unterschätzt werden.

Kernaussagen:

- Beide Methoden zeigen eine hohe Sensitivität zur Detektion eines Ödems.
- Ödeme können von T₂prep-SSFP und dcFSE-Mapping fokal unterschätzt werden.

ABSTRACT

Purpose To compare true positive and false negative results of myocardial edema mapping in two methods. Myocardial edema may be difficult to detect on cardiac MRI.

Materials and Methods 76 patients (age 59 ± 11 years, 15 female) with acute myocardial infarction (MI) and 10 healthy volunteers were prospectively included in this single-center study. 1.5 T cardiac MRI was performed in patients 2.5 days after revascularization (median) for edema mapping: Steady State Free Precession (SSFP) mapping sequence with T₂-preparation pulses (T₂prep); and dual-contrast Fast Spin-Echo

(dcFSE) signal decay edema mapping. Late gadolinium enhancement (LGE) was used as the reference for expected edema in acute MI.

Results 311 myocardial segments in patients were acutely infarcted with mean T_2 73 ms for T_2 prep SSFP vs. 87 ms for dcFSE edema mapping. In healthy volunteers the mean T_2 was 56 ms for T_2 prep SSFP vs. 50 ms for dcFSE edema mapping. Receiver operating characteristic (ROC) curve for T_2 prep SSFP show area under the curve (AUC) 0.962, $p < 0.0001$, Youden index J 0.8266, associated criterion > 60 ms, sensitivity 94%, specificity 89%. dcFSE ROC AUC 0.979, $p < 0.0001$, J 0.9219, associated criterion > 64 ms, sensitivity 93%, specificity 99%.

Conclusion Both edema mapping methods indicate high-grade edema with high sensitivity. Nevertheless, edema in acute infarction may be focally underestimated in both mapping methods.

Key Points:

- Sensitivity for edema detection is high for both methods.
- Edema may be focally underestimated by T_2 prep SSFP edema mapping and dcFSE mapping.

Citation Format

- Krumm P, Martirosian P, Rath D et al. Performance of two Methods for Cardiac MRI Edema Mapping: Dual-Contrast Fast Spin-Echo and T_2 Prepared Balanced Steady State Free Precession. *Fortschr Röntgenstr* 2020; 192: 669–677

Introduction

Myocardial edema can be difficult to detect in cardiac MRI due to the low contrast between edematous and remote myocardium [1, 2]. Quantitative cardiac MRI for evaluation of the myocardium is under clinical investigation and has proven to be superior to visual or semiquantitative edema imaging [1]. For “myocardial T_2 mapping”, a T_2 prepared Steady State Free Precession (SSFP) sequence with T_2 -preparation pulses (T_2 prep) is commonly utilized [2].

An alternative dual-contrast Fast Spin-Echo (dcFSE) signal decay edema mapping method revealed a high signal increase in myocardial segments with edema. As in FSE imaging, the signal decay time is prolonged not only by T_2 but also by T_1 effects [3, 4]. Comparison of these mapping methods in patients with inflammatory disease such as myocarditis, who may benefit most from edema imaging [5], is complicated, as there is no suitable reference method or reference standard proving areas with edema.

The aim of this study was to evaluate potential underestimation of edema in overlaps of healthy and pathologic values. This should be achieved with a representative comparison of dcFSE and T_2 prep SSFP myocardial edema mapping with cohorts for healthy and edematous myocardium, in healthy controls, and edema in acute myocardial ST-elevation myocardial infarction (STEMI), using late gadolinium enhancement as the reference standard for infarcted areas of myocardium.

The dcFSE edema mapping method is based on multi-parametric signal decay with T_1 contamination and does not represent absolutely accurate T_2 . Therefore, we use the term “Signal Decay Time” (SDT) as the value for dcFSE edema mapping [3]. Values derived from T_2 prep SSFP edema mapping are denoted as T_2 .

We hypothesized that the relative signal increase in edema may be higher in dcFSE than in T_2 prep SSFP myocardial edema mapping.

Materials and Methods

Study Population

76 patients with primary acute ST-segment elevation myocardial infarction (STEMI) (mean age: 58.9 ± 11.4 years; range: 38–

82 years; 15 females, 61 males) were prospectively included in this single-center study between August 2013 and February 2016. Cardiac MRI was performed at median 2.5 days (range: 1–10 days) after catheter-based coronary artery revascularization. The heart rate in patients was 69 ± 14 bpm (range: 46–148 bpm).

13 male patients were excluded from descriptive statistics and comparison of the methods due to non-compliance with breath commands. In six patients, no edema imaging was performed. In four patients, only T_2 prep SSFP edema mapping was completed, and in three patients, only dcFSE signal decay edema mapping was completed. 63 datasets remained for evaluation.

10 healthy volunteers (age: 33.6 ± 14.4 years; range [23; 61 years], 4 women) underwent non-contrast cardiac MRI and were serially also examined with dcFSE signal decay edema mapping and T_2 prep SSFP edema mapping for evaluation of scanner-specific normal values in a single examination. The data for healthy volunteers in dcFSE signal decay edema has already been published before [3], was used to determine normal variation in this study and is given in this study for comprehension within this publication.

The institutional review board approved this prospective study (504/2013BO1). Written and informed consent for study participation was obtained from all subjects.

Image Acquisition

Cardiac MRI was performed on a 1.5 T MRI scanner (MAGNETOM Avanto, SIEMENS Healthcare, Erlangen, Germany). DcFSE signal decay edema mapping and T_2 prep balanced SSFP myocardial edema mapping were performed in corresponding three representative short-axis slices (basal, mid-ventricular, and apical). Edema mapping measurements were conducted before contrast agent administration serially in random order for each slice of each method in one breath-hold. Sequence parameters were predetermined in the precursor study, optimized for both edema mapping methods and were not changed for this study. T_2 mapping sequence parameters are listed in ► **Table 1**.

Late Gadolinium Enhancement (LGE) imaging was acquired 10 minutes after body weight-adapted intravenous administration of contrast agent (0.15 mmol/kg body weight, Gadobutrol (Gadovist, Bayer Vital, Leverkusen, Germany)). LGE imaging was

► **Table 1** Sequence parameters for myocardial edema imaging.

► **Tab. 1** Sequenzparameter für myokardiales Ödem-Mapping.

parameter	dcFSE	T ₂ prep SSFP
field of view	320 × 265	236 × 290–276 × 340
TR	707 ms	279 ms
TE	6.3, 75 ms	1.25 ms
trigger pulse	2	3
matrix	256 × 159	130 × 160
receiver band-width	331 Hz/Pixel	893 Hz/Px
slice thickness	5 mm	8 mm
fat saturation	none	none
echo-train length	9	–
parallel imaging	GRAPPA factor 2	GRAPPA factor 2
number of contrasts	2	3
T ₂ preparation pulses	–	1) none; 2) 24 ms; 3) 55 ms

dcFSE = dual-contrast Fast Spin Echo; T₂prep SSFP = Steady State Free Precession with T₂-preparation pulses; GRAPPA: Generalized Autocalibrating Partially Parallel Acquisition.

performed as a stack of short-axis slices of a 2D T₁ weighted spoiled gradient echo sequence with manually adjusted optimal inversion recovery timing.

Image analysis

Edema maps for both dcFSE and T₂prep SSFP were calculated on an offline workstation by two readers in consensus (5 and 12 years of experience in cardiac MR imaging). Noise-corrected signal decay time (SDT) values of dcFSE and T₂ values for T₂prep SSFP mapping were evaluated from measurement data using a self-written fitting program in MATLAB (Mathworks, Natick, MA, USA) as described before in the precursor study [3]. Unevaluable segments were recorded (artifacts due to trigger, breathing, folding, susceptibility).

To generate nominal data in a dichotomous trait (edema within a segment/no edema within a segment) data was categorized as follows: For both edema mapping methods, SDT or T₂ values were considered as pathologic if above the 97.5% quantile in the healthy volunteer cohort. LGE images were evaluated on an offline workstation (CVI 42, Circle Cardiovascular Imaging, Calgary AB, Canada), also on a nominal scale and in a dichotomous trait (LGE within a segment/no LGE within a segment). LGE in a thinned myocardium from potential previous unrecognized myocardial infarction was excluded.

Each imaging method was evaluated according to the 16 segments of the AHA model. According to the pretest probability for occurrence of edema, segments were categorized in groups as described in the precursor study [3]:

1. Positive LGE in acute myocardial infarction (MI) (very high pretest probability)
2. a) Positive LGE with additional microvascular obstruction (MVO), excluding MVO area (very high pretest probability)
b) MVO area itself (high probability for susceptibility artifact)
3. Negative LGE, but adjacent to a positive LGE segment (penumbra of MI, high pretest probability)
4. Negative LGE, remote from MI (low pretest probability)
5. Healthy volunteer controls (very low pretest probability)

Statistical analysis

Statistical analysis was performed using JMP (Version 13.1, SAS Institute Inc., Cary NC, USA), receiver operating characteristic (ROC) curves were plotted with MedCalc (Version 18.10, MedCalc Software, Ostend, Belgium). Variables are expressed as mean value ± standard deviation (SD). Relative signal increase in percent of mean SDT in patients' myocardium groups compared to healthy volunteer controls was calculated.

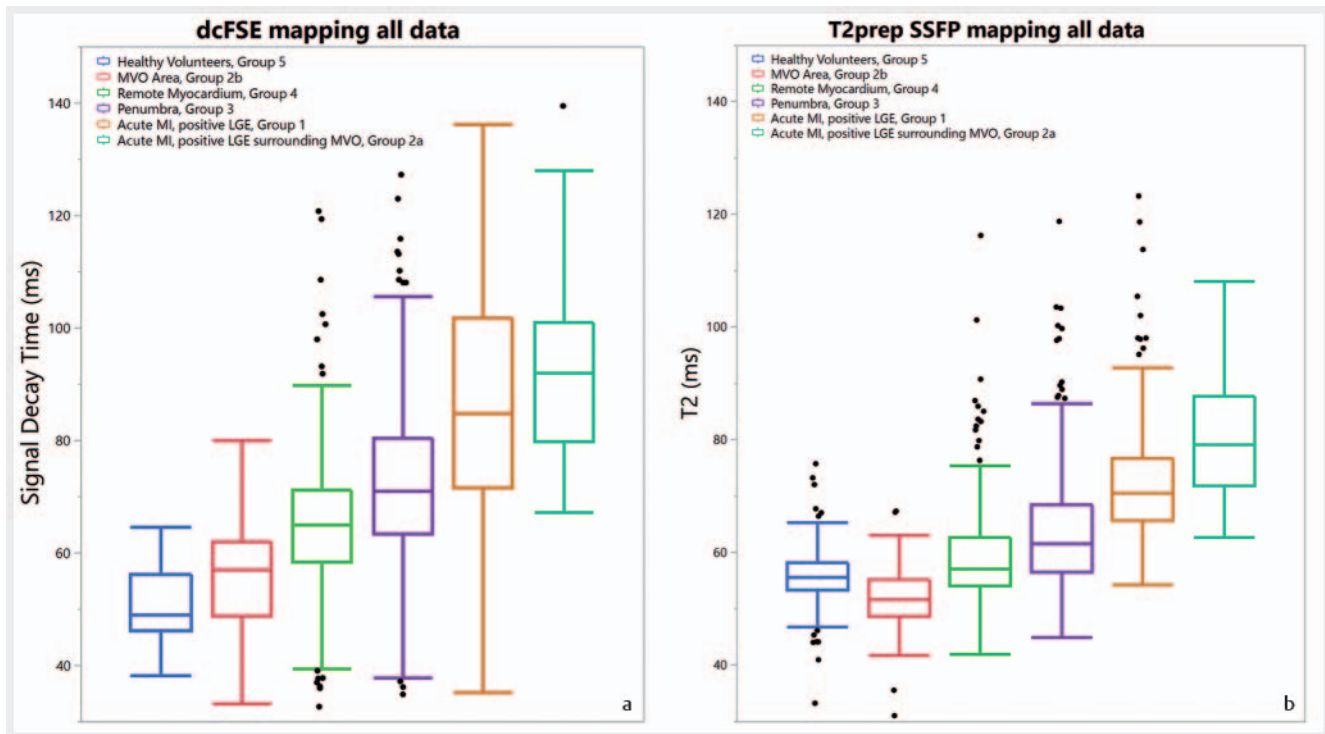
For all comparisons and tests between methods, multiplication of samples with 16 measurements per individual was avoided. Only one segment per individual or a mean value of measurements within one individual was compared.

ROC curves were plotted for both methods to plot the true positive rate (TPR) against the false positive rate (FPR) for all evaluable segments: SDT/T₂ values of all segments in each healthy volunteer were considered as true negative (TN). SDT/T₂ value of all acutely infarcted segments with positive LGE (segment groups 1 & 2a) in each patient were considered true positive (TP). All other segment groups were not evaluated in ROC curves.

A two-sided McNemar's test was applied to test for marginal homogeneity in the diagnosis of edema in LGE positive segments (group 1 and 2a) for both edema mapping techniques. For McNemar's test, binary ordinal edema data was generated for each method and transferred to a contingency table: If all group 1 and 2a segments within a patient had a SDT or T₂ value above pathological cut-off above 97.5% upper quantile of healthy volunteers, binary code 1 (edema) was assigned. If one or more segments within a patient had SDT or T₂ values below the pathological cut-off, binary code 0 (no edema) was assigned. Level of significance α was set to 5%. Power analysis (1- β) for McNemar's test was performed to control type-II error (β) according to Connor [6]. The sensitivity for both methods was calculated from this dichotomous data: Sensitivity = true positives/(true positives + false negatives). Null hypothesis (H₀) was that there is no difference in false negatives for both methods in myocardial segments with edema.

Results

No unrecognized previous myocardial infarction was found. In dcFSE edema mapping, 978/1008 (97%) of the segments in patients and 136/160 (85%) of the segments in healthy volunteers were evaluable, and 54 segments had to be excluded due to artifacts (trigger, breathing, folding, susceptibility). In T₂prep SSFP edema mapping, 907/1008 (90%) of the segments in patients and 157/160 (98%) of the segments in volunteers were evaluable, and 104 segments had to be excluded due to artifacts.



► **Fig. 1** All edema mapping SDT/T2 data plotted in a boxplot by rank of signal intensity for **a** dcFSE and **b** T₂prep SSFP. **a** In dcFSE the relative signal increase in edema in acutely infarcted segments (orange, turquoise) is higher, but with a high range. In dcFSE the low outlier values in edema can most likely be explained by susceptibility and they reduce sensitivity and specificity for dcFSE. **b** In T₂prep SSFP healthy volunteers show high outliers, which are responsible for reduced sensitivity and specificity in the further evaluation. The MVO area itself shows typically low intensity due to a susceptibility artifact in both methods.

► **Abb. 1** Alle Ödem-Mapping-Daten in Boxplots sortiert nach Signalintensität für **a** dcFSE und **b** T₂prep-SSFP. **a** Bei dcFSE ist der relative Signalanstieg im Ödem in akut infarzierten Segmenten (orange, türkis) höher, jedoch mit sehr hoher Varianz. Bei dcFSE sind die niedrigen Ausreißerwerte im Ödem am ehesten durch Suszeptibilität erklärbar und reduzieren hier Sensitivität und Spezifität für dcFSE. **b** Bei T₂prep SSFP zeigen gesunde Probanden hohe Ausreißerwerte auf. Diese sind bei SSFP für die reduzierte Sensitivität und Spezifität verantwortlich. Die MVO-Zone selbst zeigt artefaktbedingt typisch niedrige Werte in beiden Methoden.

Descriptive absolute results for both edema mapping methods in each group are given in ► **Fig. 1**, ► **Table 2**.

For dcFSE edema mapping in healthy volunteers, the mean SDT was 50 ± 6 ms (this result was previously published in the precursor study), the 97.5 % upper quantile was 64.5 ms. For T₂prep SSFP edema mapping, the mean T₂ in healthy volunteers was 56 ± 5 ms, and the 97.5 % upper quantile was 67.9 ms. From this, pathologic thresholds for edema diagnosis in this study were determined as SDT ≥ 65 ms for dcFSE; and T₂ ≥ 68 ms for T₂prep SSFP edema mapping.

► **Fig. 2** depicts clinical MR images of both methods in an exemplary patient.

Statistical Testing

ROC curve analysis for dcFSE edema mapping is shown in ► **Fig. 3**: Positive segments n = 311 (70 %), negative segments n = 136 (30 %), area under the ROC curve (AUC) 0.979, p < 0.0001, Youden index J 0.9219, associated criterion > 64 ms, sensitivity 92.9 %, specificity 99.3 %.

ROC curve analysis for T₂prep SSFP edema mapping is shown in ► **Fig. 4**: Positive segments n = 293 (65 %), negative segments

n = 156 (35 %), area under the ROC curve (AUC) 0.962 p < 0.0001, Youden index J 0.8266, associated criterion > 60.4 ms, sensitivity 94.2 %, specificity 88.5 %.

Five patients were excluded from intermethod comparison for incomplete datasets within the tested groups in one or both of the methods, so that 58 patients were included in McNemar's test.

The contingency table for both methods is given in ► **Table 3**. The discordance (contingency table cells c and b) was 27, and the Chi-square statistic was 23.51. McNemar's test revealed significant marginal inhomogeneity between the methods (p < 0.0001), power (1 - β = 0.99). The sensitivity for dcFSE edema mapping was 79 % and for T₂prep SSFP edema mapping was 33 % determined with the contingency table using the fixed specificity of 97.5 % and declaring the entire patient as "false negative" if one or more segments were false negative for each mapping method.

Discussion

In the present study we systematically compared two cardiac MRI T₂ edema mapping methods for signal increase, as well as for true

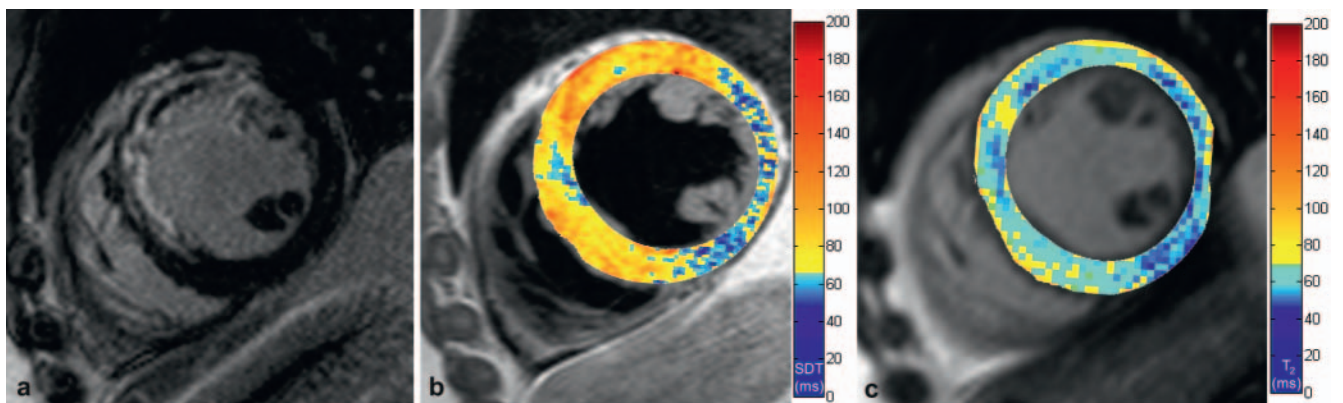
► **Table 2** Results for edema mapping.

► **Tab. 2** Ödem-Mapping-Ergebnisse.

	dcFSE mean noise corrected SDT (\pm SD) [ms]. Relative signal increase vs. volunteers [%]	T ₂ prep SSFP mean noise corrected T ₂ (\pm SD) [ms]. Relative signal increase vs. volunteers [%]	dcFSE number of segments n	T ₂ prep SSFP number of segments n
group 1 Acute MI, positive LGE	87 \pm 20 74 %	73 \pm 11 30 %	245	226
group 2a acute MI segment with MVO, excluding MVO	92 \pm 15 84 %	80 \pm 10 43 %	66	65
group 2b MVO area	55 \pm 9 10 %	52 \pm 7 -7 %	66	65
group 3 penumbra	72 \pm 15 44 %	64 \pm 11 14 %	333	310
group 4 remote myocardium in STEMI	65 \pm 12 30 %	59 \pm 9 5 %	334	302
group 5 healthy volunteers	50 \pm 6	56 \pm 5	136	157

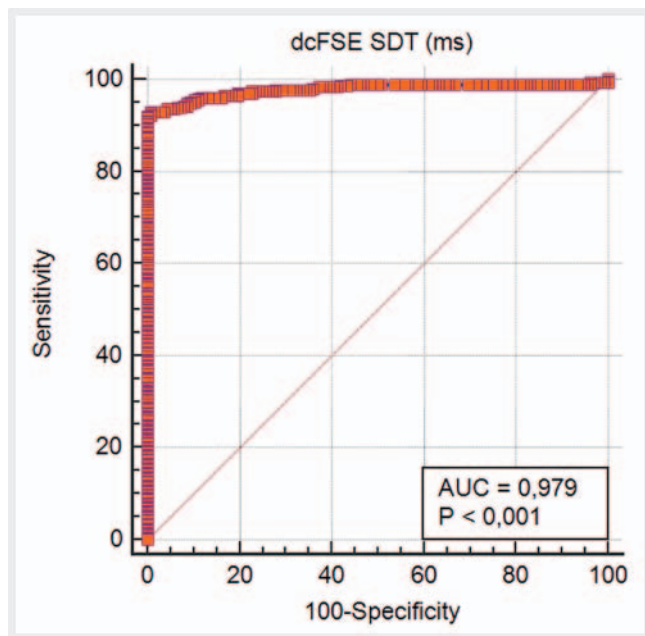
Absolute results for edema mapping in both methods for all groups are presented. Relative signal increase compared to healthy volunteers in italics. Susceptibility effects in the MVO area lead to relevant local signal decrease.

Absolute Ergebnisse für das Ödem-Mapping mit beiden Methoden für alle Segmentgruppen. Der relative Signalanstieg, verglichen mit den gesunden Probanden, ist in kursiv angegeben. Suszeptibilitätsartefakte im Areal der mikrovaskulären Obstruktion (MVO) führen hier lokal zu einem relevanten Abfall des Signals. SD = Standard Deviation; MI = Myocardial Infarction; LGE = Late Gadolinium Enhancement; MVO = Microvascular Obstruction; STEMI = ST-Elevation Myocardial Infarction.



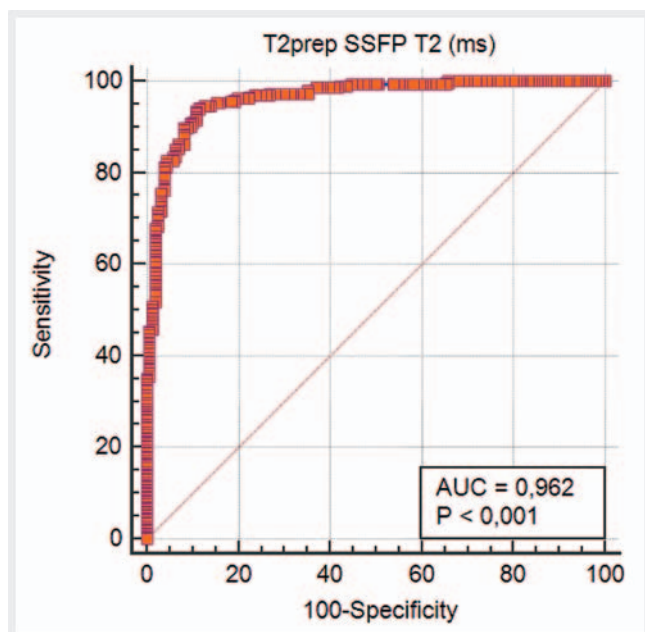
► **Fig. 2** Representative mid-ventricular short-axis cardiac MR images of a 56-year-old male patient with acute ST-elevation myocardial infarction, three days after interventional revascularization. **a** LGE indicating acute myocardial infarction in the septum and anterior segments with microvascular obstruction (MVO) providing an example for edema underestimation in T₂prep SSFP edema mapping. **b** dcFSE edema mapping indicates pathologic SDT values in the septal segments by yellow and red colors (cut-off for yellow color 65 ms). **c** T₂prep SSFP edema mapping indicates pathologic T₂ values in the septal segments by yellow colors (cut-off for yellow color 68 ms) and provides an example for focal edema underestimation also outside MVO.

► **Abb. 2** Repräsentative mittventrikuläre Kurzachsen-MR-Bilder eines 56-jährigen männlichen Patienten mit akutem ST-Hebungsinfarkt, 3 Tage nach interventioneller Revaskularisierung. **a** LGE zeigt den akuten Myokardinfarkt septal und anterior mit mikrovaskulärer Obstruktion (MVO). **b** dcFSE-Ödem-Mapping zeigt pathologische SDT-Werte septal gelb und rot (Schwellenwert für gelb 65 ms). **c** T₂prep-SSFP-Ödem-Mapping zeigt pathologische T₂-Werte septal gelb (Schwellenwert für gelb 68 ms) und beispielhaft fokale Unterschätzung des Ödems auch außerhalb der MVO.



► **Fig. 3** Receiver operating characteristic (ROC) curve for dcFSE show area under the curve (AUC) 0.979, $p < 0.0001$, Youden index J 0.9219, associated criterion > 64 ms, sensitivity 93 %, specificity 99 %.

► **Abb. 3** Operationscharakteristik eines Beobachters (ROC-Kurve) für dcFSE zeigt eine Fläche unter der Optimierungskurve (AUC) von 0,979, $p < 0,0001$, Youden-Index J 0,9219, assoziierter Schwellenwert > 64 ms, Sensitivität 93 %, Spezifität 99 %.



► **Fig. 4** ROC curve for T₂prep SSFP show AUC 0.962, $p < 0.0001$, Youden index J 0.8266, associated criterion > 60 ms, sensitivity 94 %, specificity 89 %.

► **Abb. 4** ROC-Kurve für T₂prep-SSFP zeigt eine AUC von 0,962, $p < 0,0001$, Youden-Index J 0,8266, assoziierter Schwellenwert > 60 ms, Sensitivität 94 %, Spezifität 89 %.

positive and false negative results in high-grade edema of acute myocardial infarction.

The relative signal increase in edema was higher in dcFSE compared to T₂prep SSFP edema mapping as expected due to T₁ contamination. In intra-methodal comparison, both methods show high sensitivity and specificity. Unexpectedly, inter-methodal comparison of the edema mapping methods indicate more focal false negatives in T₂prep SSFP edema mapping in our study approach.

In our study, McNemar's test revealed that focal false negative underestimation of high-grade edema was significantly higher in T₂prep SSFP compared to dcFSE edema.

The low sensitivity in McNemar's test is because two strict conditions had to be achieved: 1) the edema mapping SDT/T₂ value must be above the 97.5 % upper quantile of healthy volunteers; and 2) one acutely infarcted segment below this value results in the entire patient being categorized as "false negative". The specificity was not calculated in the contingency table/McNemar analysis for this was manually set by the cut-off above the 97.5 % upper quantile. As graphically visible in the boxplots of all data, the high outlier values of healthy volunteers in T₂prep SSFP edema mapping were higher up to the median in acutely infarcted segments. For T₂prep SSFP this led to a higher pathologic cut-off value using the 97.5 % upper quantile (> 68 ms) than associated criterion in ROC analysis (> 60 ms). On the other hand, the range of acutely infarcted segments was very wide in dcFSE edema mapping, also leading to a certain underestimation of edema.

ROC curves instead indicate high sensitivity and specificity of both methods with even higher sensitivity of T₂prep SSFP edema mapping, resulting in a lower specificity as a matter of course.

Concerning our segment-based ROC analysis, a multiplication of sample bias with 16 measurements in healthy volunteers and a mean of 5 measurements in STEMI patients has to be stated. A reduction to only one measurement per study subject by mean values, highest values or lowest values would have led to underrepresentation of either high or low values and would not have taken these important margins into account.

Edema mapping techniques are known to outperform qualitative T₂ imaging [3]. Nevertheless, this study shows underestimation may occur also in edema mapping. If focal underestimation of edema is clinically relevant for an individual, the McNemar analysis should be taken in account.

To evaluate true positives and false negatives, only healthy volunteers and patients with edema with the maximum possible extent and development were examined in this study. This edema extent in STEMI patients may be used to evaluate the area at risk in clinical trials, but has only little impact on the clinical decision and outcome. However, detection of low-grade and diffuse edema is most important for the diagnosis of inflammatory cardiac diseases, such as myocarditis [5, 7–9], sarcoidosis [10], cardiac allograft rejection [11], connective tissue and rheumatic disorders [12, 13] and myocardial involvement in antineutrophil cytoplasmic antibody (ANCA)-associated vasculitis [14]. Misinterpretation and overdiagnosis of edema is possible using T₁ contaminated methods such as dcFSE, especially in the case of T₁ elevation due to diffuse fibrosis or scar. dcFSE may probably falsely yield a higher SDT in subacute or chronic MI unlike T₂prep SSFP edema mapping. The extent of edema in the segments adjacent to infarction

► **Table 3** Contingency table and McNemar test.

► **Tab. 3** 4-Feldertafel und McNemar-Test.

count	T ₂ prep SSFP no edema (0)	T ₂ prep SSFP edema (1)	total
dcFSE no edema (0)	10	2	12
dcFSE edema (1)	29	17	46
Total	39	19	58

Contingency table for comparison of both methods.

For this test, each patient was assigned to "edema" if all LGE-positive acutely infarcted segments (group 1 and 2a) had a true-positive SDT or T₂ value above the pathological cut-off within each method. If one or more segments within a patient had a false-negative SDT or T₂ values below the pathological cut-off, "no edema" was assigned.

The discordance (contingency table cells c and b) was 27 with a Chi-square statistic of 23.51. McNemar's test revealed significant marginal inhomogeneity between methods ($p < 0.0001$, power $(1 - \beta) = 0.99$).

The sensitivity was 79% for dcFSE edema mapping and 33% for T₂prep SSFP edema mapping using this method with a fixed specificity of 97.5%.

4-Feldertafel für den Vergleich beider Methoden.

Für diesen Test wurde jeder Patient der Gruppe „Ödem“ zugewiesen, wenn alle LGE-positiven, akut infarzierten Segmente (Segmentgruppen 1 und 2a) richtig positive SDT- oder T₂-Werte oberhalb der pathologischen Grenzwerte innerhalb der jeweiligen Methode aufwiesen.

Wenn ein oder mehrere Segmente falsch negative SDT- oder T₂-Werte unterhalb der pathologischen Grenzwerte innerhalb der jeweiligen Methode aufwiesen, wurde der Patient der Gruppe „kein Ödem“ zugewiesen.

Der Unterschied der Diskordanten (4-Feldertafel Zellen c und b) betrug 27, mit Chi-Quadrat 23,51. Der McNemar-Test deckt eine signifikante marginale Inhomogenität zwischen den Methoden auf ($p < 0,0001$, Power $(1 - \beta) = 0,99$).

Die mit dieser Methode berechnete Sensitivität für das dcFSE-Ödem-Mapping beträgt 79%, für das T₂prep-SSFP-Ödem-Mapping 33% mit einer festgelegten Spezifität von 97,5%.

(group 3) and remote from infarction (group 4) cannot be validated with a reference method, as their edema mapping results only indicate potential low-grade edema. Thus, no evaluation of the validity of false positive and false negative findings has been performed in these segment groups.

As previously published by Baeßler et al., we expected a different SDT or T₂ for different edema mapping methods [15]. Her working group has already proven the reproducibility of three different T₂-mapping methods for cardiac MRI in healthy volunteers [16].

Our mean value for T₂prep SSFP edema mapping in healthy volunteers is similar to previously published values [9, 16, 17], but we found higher outliers also in healthy volunteers in both methods leaving no gap between volunteers and patients but rather a typical continuum, with a cut-off value influencing diagnostic accuracy.

As a general finding, we determined an underestimation even of high-grade edema when performing cardiac MRI edema mapping in patients suffering from acute myocardial infarction. Therefore, an even higher underestimation with a reduced sensitivity

and specificity must be expected in low- and intermediate-grade edema as may occur in inflammatory cardiomyopathy. This has also recently been hypothesized by Baeßler et al., as they found higher diagnostic performance in the diagnosis of myocarditis in parameters derived from mean absolute deviation of myocardial T₂ than by mere global myocardial T₂ values, due to a high overlap of these absolute values with those of healthy volunteers [18]. As previously hypothesized by Montant et al., the cut-off values are helpful for differentiation but edema has to be considered a continuum between a pathologic core and a potentially healthy remote myocardium [19].

Two different but similar cut-off values for SDT and T₂ in both edema mapping methods were confirmed (around 65 ms). The spread and range of signal decay time in dcFSE edema mapping were higher than in T₂prep SSFP edema mapping. The higher signal increase in FSE imaging arises mainly from the contribution of T₁ contamination from stimulated echoes. Other effects may be a higher slice thickness and thus thicker slabs of myocardium depicted in FSE images with potential partial volume effects, less absolute and less homogeneous signal in FSE images, and only two time-points for dcFSE edema mapping. Various other reasons influence T₂ quantification in clinical imaging for both methods: variation in flip angle, pulse sequence timing, magnetic field inhomogeneity and crusher gradients [3, 4]. A higher signal in dark-blood FSE images may be expected in infarcted segments due to reduced contractility of the myocardium as well as due to the slow-flow artifact of blood in the trabecula [20]. All mapping techniques suffer from potential partial volume effects with pericardial fat and the blood pool [21]. As influences of T₁ and magnetization transfer cannot be ruled out in dcFSE signal generation [22], the decay time evaluated in "dcFSE myocardial edema mapping" is predominantly dependent on the T₂ constant but remains multi-parametric. Consequently, we chose the expression "signal decay time" (SDT) for this value is not true T₂. Methods to quantitatively determine myocardial edema are commonly referred to as "myocardial T₂ mapping" [1, 9, 23]. This seems justified for T₂prep SSFP edema mapping measures T₂.

Both methods compared in our study acquire all image data of one slice in all contrasts for mapping within one breath-hold, to ensure clinical practicability. For absolute quantification of T₂ decay time, all methods clinically applicable for cardiac imaging are not sufficient: much longer acquisition times, more different contrast images, as well as exclusion of T₁ and T₂* contamination would be needed for absolute quantification of T₂ decay time. The influence of T₂* susceptibility effect is demonstrated by the separate evaluation of the MVO area itself (segment group 2b) with artificially very low SDT and T₂ values in the center of infarction. The same segments show the highest SDT and T₂ for high-grade edema when the MVO area itself is excluded (segment group 2a).

The contribution of both T₁ and T₂ to signal increase in dcFSE edema mapping has been demonstrated in the precursor study [3] and can be considered as the most important reason for the higher sensitivity. The signal increase measured by dcFSE in edema is not absolute T₂ but a new parameter dependent on T₁ and T₂ and referred to as SDT (signal decay time). The effect of edema detection by myocardial T₁ mapping is probably subject to the same effect. The underestimation of low-grade edema in T₂prep

SSFP edema mapping may be a reason why T_1 mapping has meanwhile been proposed for the diagnosis of myocarditis [24] and has become one major criterion in the updated Lake Louise Criteria for myocarditis [25] and structured reporting [26]. However, this study cannot draw conclusions about whether myocardial T_1 mapping is sufficient to detect edema. If myocardial T_1 mapping is used for edema detection, it may suffer from lower specificity due to changes reported in many diseases with higher extracellular compartment [21, 27].

There are no general recommendations as to whether a healthy volunteer control group for each sequence and even each scanner at each site is needed [28] but it may be beneficial for the local interpretation of results.

Limitations

As a limitation in study design, only acute post-infarction edema was examined but may not be representative for subtle edema in inflammatory cardiomyopathy as myocarditis with subacute or chronic onset. No motion correction was applied. The apical slice was included in this evaluation, but this area is often prone to partial volume artifacts. Therefore, all images and segments with misalignment were excluded from evaluation to eliminate influence from motion correction algorithms. No exclusion of other cardiomyopathies potentially being present in addition to acute STEMI was performed. No reference method for the occurrence of edema in vivo is available, but myocardial edema in acute MI is highly expected. No histological confirmation of the findings was performed in this study. Myocardial edema and correlation with T_2 has been previously verified in a porcine model [29]. In a discussion about post-initial decrease wave of edema 24 hours after reperfusion, this phenomenon has then been interpreted as hemorrhage [30, 31]. We have controlled this effect by exclusion and separate evaluation of the MVO area with hemorrhage. Nevertheless, LGE is not a perfect reference standard. Women with STEMI were underrepresented with only 24% of the patient cohort. The healthy volunteer cohort is relatively small.

Conclusion

In conclusion, both edema mapping methods indicate high-grade edema with high sensitivity. Nevertheless, edema in acute infarction may be focally underestimated in both mapping methods.

Conflict of Interest

The authors declare that they have no conflict of interest.

References

- Naßenstein K, Nensa F, Schlosser T et al. Cardiac MRI: T_2 -Mapping Versus T_2 -Weighted Dark-Blood TSE Imaging for Myocardial Edema Visualization in Acute Myocardial Infarction. *Fortschr Röntgenstr* 2014; 186: 166–172
- Kellman P, Aletras AH, Mancini C et al. T_2 -prepared SSFP improves diagnostic confidence in edema imaging in acute myocardial infarction compared to turbo spin echo. *Magn Reson Med* 2007; 57: 891–897
- Krumm P, Martirosian P, Rath D et al. Signal decay mapping of myocardial edema using dual-contrast fast spin-echo MRI. *J Magn Reson Imaging* 2016; 44: 186–193
- Ben-Eliezer N, Sodickson D, Block K. Rapid and accurate T_2 mapping from multi-spin-echo data using bloch-simulation-based reconstruction. *Magn Reson Med* 2015; 73: 809–817
- Friedrich MG, Sechtem U, Schulz-Menger J et al. Cardiovascular magnetic resonance in myocarditis: A JACC White Paper. *J Am Coll Cardiol* 2009; 53: 1475–1487
- Connor RJ. Sample size for testing differences in proportions for the paired-sample design. *Biometrics* 1987; 43: 207–211
- Kühl U, Schultheiss HP. Myocarditis: early biopsy allows for tailored regenerative treatment. *Dtsch Arztebl Int* 2012; 109: 361–368
- Achenbach S, Barkhausen J, Beer M et al. Consensus recommendations of the German Radiology Society (DRG), the German Cardiac Society (DGK) and the German Society for Pediatric Cardiology (DGPK) on the use of cardiac imaging with computed tomography and magnetic resonance imaging. *Fortschr Röntgenstr* 2012; 184: 345–368
- Thavendiranathan P, Walls M, Giri S et al. Improved detection of myocardial involvement in acute inflammatory cardiomyopathies using T_2 mapping. *Circ Cardiovasc Imaging* 2012; 5: 102–110
- Greulich S, Kitterer D, Latus J et al. Comprehensive Cardiovascular Magnetic Resonance Assessment in Patients With Sarcoidosis and Preserved Left Ventricular Ejection Fraction. *Circ Cardiovasc Imaging* 2016; 9: e005022
- Vignaux O, Dhote R, Duboc D et al. Clinical significance of myocardial magnetic resonance abnormalities in patients with sarcoidosis: a 1-year follow-up study. *Chest* 2002; 122: 1895–1901
- Mayr A, Kitterer D, Latus J et al. Evaluation of myocardial involvement in patients with connective tissue disorders: a multi-parametric cardiovascular magnetic resonance study. *J Cardiovasc Magn Reson* 2016; 18: 67
- Greulich S, Mayr A, Kitterer D et al. Advanced myocardial tissue characterisation by a multi-component CMR protocol in patients with rheumatoid arthritis. *Eur Radiol* 2017; 27: 4639–4649
- Greulich S, Mayr A, Kitterer D et al. T_1 and T_2 mapping for evaluation of myocardial involvement in patients with ANCA-associated vasculitides. *J Cardiovasc Magn Reson* 2017; 19: 6
- Baeßler B, Schaarschmidt F, Stehning C et al. Cardiac T_2 -mapping using a fast gradient echo spin echo sequence – first in vitro and in vivo experience. *J Cardiovasc Magn Reson* 2015; 17: 67
- Baeßler B, Schaarschmidt F, Stehning C et al. Reproducibility of three different cardiac T_2 -mapping sequences at 1.5T. *J Magn Reson Imaging* 2016; 44: 1168–1178
- Verhaert D, Thavendiranathan P, Giri S et al. Direct T_2 quantification of myocardial edema in acute ischemic injury. *J Am Coll Cardiol* 2011; 4: 269–278
- Baeßler B, Schaarschmidt F, Treutlein M et al. Re-evaluation of a novel approach for quantitative myocardial oedema detection by analysing tissue inhomogeneity in acute myocarditis using T_2 -mapping. *Eur Radiol* 2017; 27: 5169–5178
- Montant P, Sigovan M, Revel D et al. MR imaging assessment of myocardial edema with T_2 mapping. *Diagn Interv Imaging* 2015; 96: 885–890
- Friedrich MG, Kim HW, Kim RJ. T_2 -weighted imaging to assess post-infarct myocardium at risk. *J Am Coll Cardiol* 2011; 4: 1014–1021
- Kellman P, Hansen MS. T_1 -mapping in the heart: accuracy and precision. *J Cardiovasc Magn Reson* 2014; 16: 2
- Stromp TA, Leung SW, Andres KN et al. Gadolinium free cardiovascular magnetic resonance with 2-point Cine balanced steady state free precession. *J Cardiovasc Magn Reson* 2015; 17: 90

- [23] Markl M, Rustogi R, Galizia M et al. Myocardial T₂-mapping and velocity mapping: changes in regional left ventricular structure and function after heart transplantation. *Magn Reson Med* 2013; 70: 517–526
- [24] Kim PK, Hong YJ, Im DJ et al. Myocardial T₁ and T₂ mapping: Techniques and clinical applications. *Korean J Radiol* 2017; 18: 113–131
- [25] Ferreira VM, Schulz-Menger J, Holmvang G et al. Cardiovascular Magnetic Resonance in Nonischemic Myocardial Inflammation: Expert Recommendations. *J Am Coll Cardiol* 2018; 72: 3158–3176
- [26] Bunck AC, Baeßler B, Ritter C et al. Structured Reporting in Cross-Sectional Imaging of the Heart: Reporting Templates for CMR Imaging of Cardiomyopathies (Myocarditis, Dilated Cardiomyopathy, Hypertrophic Cardiomyopathy, Arrhythmogenic Right Ventricular Cardiomyopathy and Siderosis). *Fortschr Röntgenstr.* Epub ahead of print October 9 2019 doi:10.1055/a-0998-4116
- [27] Roller FC, Harth S, Schneider C et al. T₁, T₂ Mapping and Extracellular Volume Fraction (ECV): Application, Value and Further Perspectives in Myocardial Inflammation and Cardiomyopathies. *Fortschr Röntgenstr* 2015; 187: 760–770
- [28] Schulz-Menger J, Bluemke DA, Bremerich J et al. Standardized image interpretation and post processing in cardiovascular magnetic resonance: Society for Cardiovascular Magnetic Resonance (SCMR) board of trustees task force on standardized post processing. *J Cardiovasc Magn Reson* 2013; 15: 35
- [29] Fernández-Jiménez R, Sánchez-González J, Agüero J et al. Myocardial edema after ischemia/reperfusion is not stable and follows a bimodal pattern: imaging and histological tissue characterization. *J Am Coll Cardiol* 2015; 65: 315–323
- [30] Berry C, Carrick D, Haig C et al. “Waves of Edema” Seem Implausible. *J Am Coll Cardiol* 2016; 67: 1868–1869
- [31] Fernández-Jiménez R, Fuster V, Ibanez B. Reply: “Waves of Edema” Seem Implausible. *J Am Coll Cardiol* 2016; 67: 1869–1870

ERRATUM 08.12.2020

Krumm P, Martirosian P, Rath D et al. Performance of two Methods for Cardiac MRI Edema Mapping: Dual-Contrast Fast Spin-Echo and T2 Prepared Balanced Steady State Free Precession. *Fortschr Röntgenstr* 2020; 192: 669–677

Contrast agent concentration applied for Late Gadolinium Enhancement (LGE) imaging as reference method was 0.15 mmol/kg body weight (Gadobutrol, Gadovist, Bayer Vital, Leverkusen, Germany).