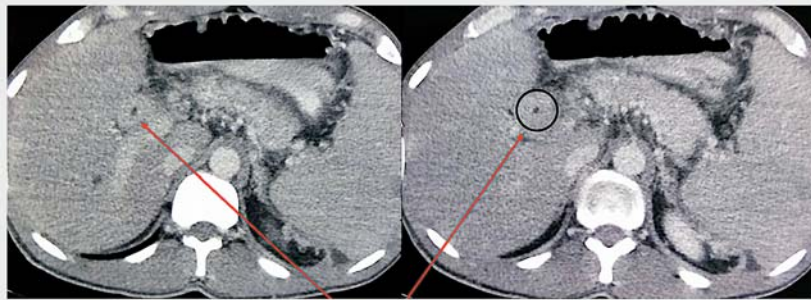
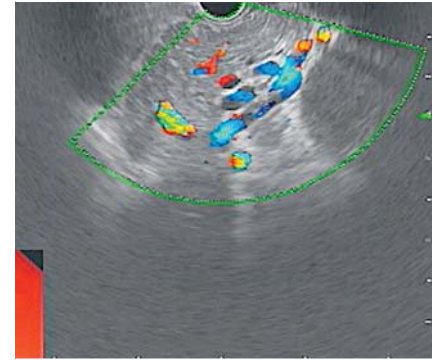


## Linear endoscopic ultrasound examination of portal biliopathy

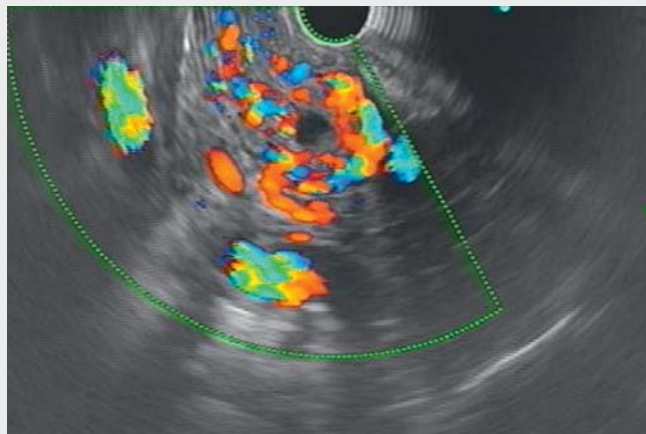


Diffuse thickening of CBD

► **Fig. 1** Contrast-enhanced computed tomography showed diffuse thickening of the common bile duct (arrows, ring).



► **Fig. 2** Endoscopic ultrasonography showing the pancreatic body with multiple peripancreatic collaterals.



► **Video 1** Endoscopic ultrasound examination of portal biliopathy.

A 30-year-old man diagnosed 10 years ago with extrahepatic portal vein thrombosis underwent multiple sessions of endoscopic band ligation of esophageal varices. The last endoscopy session showed obliterated varices. Recently the patient complained of having had mild abdominal pain for 2 weeks. Laboratory evaluation showed mild anemia (Hb 11 g/dL) and normal bilirubin (total 1 mg/dl) with mildly elevated liver enzymes: alanine transaminase 68 U/L, as-

partate transaminase 42 U/L, and alkaline phosphatase 168 U/L (normal <120 U/L). Serum amylase and lipase were normal. Contrast-enhanced computed tomography showed diffuse thickening of the common bile duct (CBD) (► **Fig. 1**), multiple peripancreatic collaterals, and a normal pancreas. Magnetic resonance cholangiography could not be done because of the patient's claustrophobia. For CBD evaluation he underwent endoscopic ultrasonography (EUS) with a line-

ar echoendoscope. The EUS scope was passed into the duodenal bulb. From the duodenal bulb, multiple serpiginous linear structures were seen in the suprapancreatic region. On Doppler examination all these linear serpiginous structures showed a positive signal, and in the center a small, round, anechoic structure suggestive of the CBD was seen (► **Video 1**). The CBD was then traced from the ampulla to the hilum and back and forth. These paracholedochal collaterals resulted in a diffusely decreased caliber of the CBD. On CT examination these paracholedochal collaterals gave a pseudo-appearance of thickened walls of the CBD. Further EUS examination showed a normal pancreas, splenomegaly, and multiple peripancreatic and splenic hilar collaterals (► **Fig. 2**). The patient was managed symptomatically and asked to attend for regular follow-up. Portal biliopathy is defined as abnormalities in the extrahepatic bile duct with or without abnormalities in intrahepatic radicles in a patient with portal cavernoma [1]. The role of EUS is still evolving. EUS can accurately detect sites of varices in relation to the CBD (paracholedochal, intracholedochal, subepithelial, etc.), and that could be useful in patients undergoing endoscopic retrograde cholan-

giography. EUS may be considered as an alternative diagnostic modality to magnetic resonance cholangiography when it is not possible to perform the latter.

Endoscopy\_UCTN\_Code\_CCL\_1AF\_2AZ\_3AD

### Competing interests

None

### The authors

**Radhika Chavan, Zaheer Nabi, Sundeep Lakhtakia, Mohan Ramchandani, Jahangeer Basha, Rajesh Gupta, D. Nageshwar Reddy**  
Department of Medical Gastroenterology, Asian Institute of Gastroenterology, Somajiguda, Hyderabad, India

### Corresponding author

**Radhika Chavan, MD**  
Asian Institute of Gastroenterology,  
Somajiguda, Hyderabad – 500 082, India  
drradhikachavan@gmail.com

### Reference

- [1] Dhiman RK, Saraswat VA, Valla DC et al. Portal cavernoma cholangiopathy: consensus statement of a working party of the Indian National Association for Study of the Liver. *J Clin Exp Hepatol* 2014; 4: S2–S14

### Bibliography

DOI <https://doi.org/10.1055/a-1028-6948>  
Published online: 7.11.2019  
Endoscopy 2020; 52: E136–E137  
© Georg Thieme Verlag KG  
Stuttgart · New York  
ISSN 0013-726X

#### ENDOSCOPY E-VIDEOS

<https://eref.thieme.de/e-videos>



*Endoscopy E-Videos* is a free access online section, reporting on interesting cases and new techniques in gastroenterological endoscopy. All papers include a high quality video and all contributions are freely accessible online.

This section has its own submission website at <https://mc.manuscriptcentral.com/e-videos>