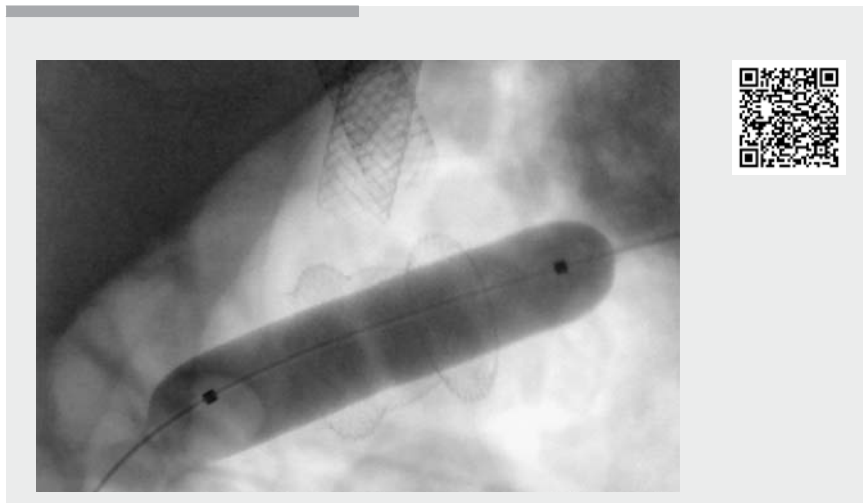


Buried lumen-apposing metal stent after gastrojejunal bypass

The possibilities of performing endoscopic gastroenteral bypass and enteroenteral bypass have been explored recently in patients with Roux-en-Y reconstruction after subtotal gastrectomy or biliary anastomosis; however, data are still scant and based on limited follow-up. The main adverse events described in the available literature are displacement or migration of the enteral stents, enteral perforations, and early bleeding [1–3]. We here describe the occurrence and our management of an intramural gastric partial migration of a lumen-apposing metal stent (LAMS), a rare adverse event of endoscopic gastroenteral bypass that has not yet been reported.

A 72-year-old man underwent endoscopic retrograde cholangiopancreatography (ERCP) via an endoscopic enteral bypass [4], with double metal stenting to treat an anastomotic stricture of the hepaticojejunostomy on the Roux-en-Y loop (previously performed because of a lesion of the common bile duct found during cholecystectomy). He failed to present for removal of the stents at 6 months; however, he presented to the Emergency Department because of acute cholangitis 13 months after the endoscopic procedure. An abdominal computed tomography (CT) scan showed correct positioning of both the biliary and enteral stents (partially obstructed by stones and sludge); however, the gastric flare of the enteral LAMS seemed to be “buried” in the gastric wall.

An ERCP was scheduled to remove the stents. During the endoscopy, performed using an operative gastroscope (EG-216; Pentax), the gastric side of the bypass was recognized as a small (around 5 mm) ulcerated orifice (► **Video 1**). The scope could not be passed through the small residual opening, so a guidewire (0.035-inch Jagwire; Boston Scientific) was pushed through the orifice until it reached the connected biliary jejunal loop. A 15-mm dilation balloon (CRE 12–15 mm; Boston Scientific) was



► **Video 1** The video shows the endoscopic management of a rare adverse event following endoscopic gastroenteral bypass: the flare of the lumen-apposing metal stent buried at the gastric side of the endoscopic bypass.

inflated and left within the LAMS to channel back the bypass for 24 hours.

At the second-look endoscopy, the gastric orifice of the bypass was now larger and clearly visible. The operative gastroscope was pushed through the endoscopic gastroenteral bypass and the biliary stents were removed, although the procedure proved difficult because one of the stents was entrapped in an anastomotic recess of the hepaticojejunostomy. A cholangiography performed at the end of the procedure showed no residual defect in the biliary tree and no evidence of bile leakage. Removal of the enteral LAMS appeared to carry a risk of perforation because the gastric flare was located in the deep layers of the gastric wall. Therefore, a biflanged fully covered metal stent (Nagi Stent, 16 mm × 2 cm; EuroMedical Inc.) was placed into the LAMS to guarantee the patency of the bypass.

The patient experienced a self-limited episode of fever (due to transient bacteremia), but both his symptoms and blood tests improved in 12 hours and he was discharged 48 hours after the procedure.

Endoscopy_UCTN_Code_CPL_1AL_2AB

Competing interests

None

The authors

Lorenzo Dioscoridi, Edoardo Forti, Francesco Pugliese, Marcello Cintolo, Giulia Bonato, Aurora Giannetti, Massimiliano Mutignani
Digestive and Interventional Endoscopy Unit, Niguarda-Ca' Granda Hospital, Milan, Italy

Corresponding author

Lorenzo Dioscoridi, MD
Digestive and Interventional Endoscopy Unit, Niguarda Ca' Granda Hospital, Piazza dell'Ospedale Maggiore 3, 20162 Milano, Italy
Fax: +39-02-64442911
massimiliano.mutignani@ospedaleniguarda.it

References

- [1] Mutignani M, Manta R, Pugliese F et al. Endoscopic ultrasound-guided duodenojejunal anastomosis to treat postsurgical Roux-en-Y hepaticojejunostomy stricture: a dream or a reality? *Endoscopy* 2015; 47: E350–E351
- [2] Majmudar K, Wagh MS. EUS-guided jejuno-jejunosotomy with lumen-apposing metal stent for complete jejunal obstruction after gastric bypass. *Gastrointest Endosc* 2016; 84: 853–854
- [3] Tyberg A, Perez-Miranda M, Sanchez-Ocana R et al. Endoscopic ultrasound-guided gastrojejunostomy with lumen-apposing metal stent: a multicenter, international experience. *Endosc Int Open* 2016; 4: E276–E281
- [4] Mutignani M, Forti E, Larghi A et al. Endoscopic entero-ental bypass: an effective new approach to the treatment of postsurgical complications of hepaticojejunostomy. *Endoscopy* 2019. doi:10.1055/a-0914-2855

Bibliography

DOI <https://doi.org/10.1055/a-1025-1919>
Published online: 25.10.2019
Endoscopy 2020; 52: E134–E135
© Georg Thieme Verlag KG
Stuttgart · New York
ISSN 0013-726X

ENDOSCOPY E-VIDEOS <https://eref.thieme.de/e-videos>



Endoscopy E-Videos is a free access online section, reporting on interesting cases and new

techniques in gastroenterological endoscopy. All papers include a high quality video and all contributions are freely accessible online.

This section has its own submission website at

<https://mc.manuscriptcentral.com/e-videos>