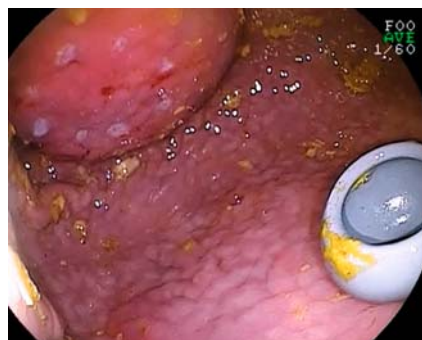

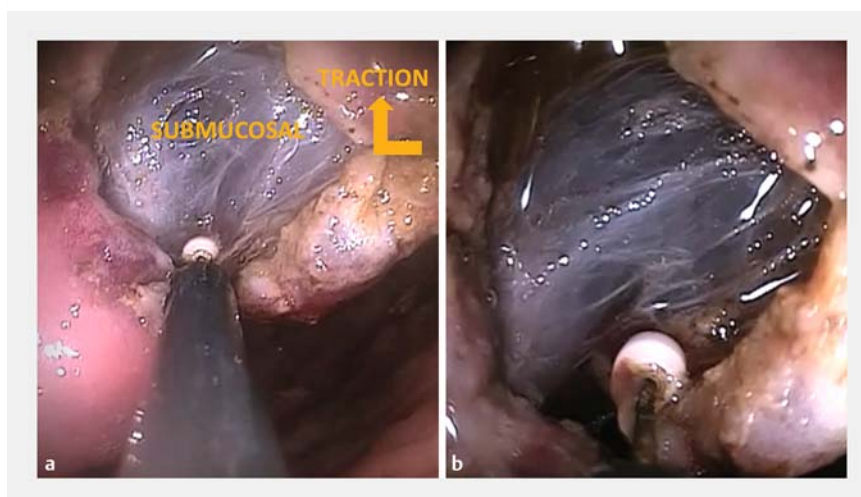Percutaneous traction via a novel endoscopic trocar facilitates endoscopic submucosal dissection



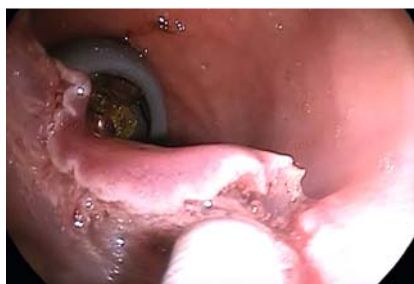► **Fig. 1** Endoscopic image showing a gastric port in the wall contralateral to the marked lesion.

Minimally invasive endoscopic procedures are associated with fewer adverse events and shorter hospital stays compared with surgery [1]. However, some advanced endoscopic procedures, including endoscopic submucosal dissection (ESD), require specialized training and significant experience to achieve competency and are not widely performed in non-specialist centers [2]. Despite the availability of a wide range of accessory devices, endoscopy lacks the dexterity required to achieve triangulation of instruments to perform non-axial tissue manipulation [3]. Because of the limitations of flexible endoscopes, a novel percutaneous intragastric trocar (PIT) has been designed. This device (Endo-TAGSS LLC, Kansas City, Missouri, USA) is placed using well-understood percutaneous endoscopic gastrostomy (PEG) techniques that have been performed by many physicians worldwide, with low rates of adverse events [4]. While previous studies have used this technique in intragastric procedures, in this video we demonstrate the use of the PIT device in both gastric and colonic ESD [5].

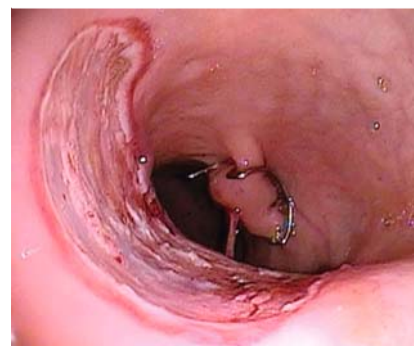
Under endoscopic visualization, an intragastric port (3.8 mm/11 Fr) was placed in a fashion similar to that of a standard PEG in the contralateral wall of



► **Fig. 2** Images during endoscopic submucosal dissection with percutaneous intragastric trocar (PIT) assistance showing: **a** the use of a grasper through the PIT, which allows traction on the lesion to improve visualization and tissue tension to enhance dissection; **b** improved exposure of the submucosal layer.



► **Fig. 3** Endoscopic image showing colonic endoscopic submucosal dissection with percutaneous intragastric trocar (PIT) assistance.

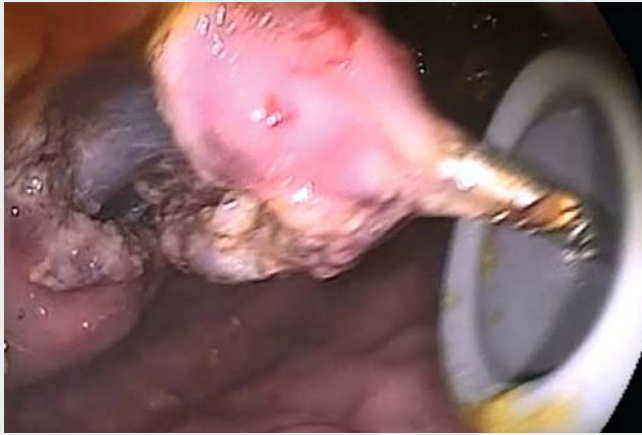

► **Fig. 4** Final appearance following colonic endoscopic submucosal dissection after closure of the colon access site with a cap-mounted clip.

the lesion (► **Fig. 1**). The dilator tip was replaced with a trocar head and connected to a laparoscopic insufflator. After the trocar had been placed, a gastroscop and conventional injection needle were used to perform submucosal lift, which was followed by mucosal incision. A grasper was used through the trocar to hold the tissue and provide traction for better exposure and tissue tension during dissection (► **Fig. 2** and ► **Fig. 3**). In ► **Video 1**, we closed the defects using the over-the-scope clip (OTSC) Twin

Grasper and cap-mounted OTSCs (Ovesco Endoscopy AG, Tübingen, Germany) (► **Fig. 4**), but any approved endoscopic closure device can be used.

This novel endoscopic trocar therefore allows for hybrid percutaneous–endoscopic procedures, improving exposure and tissue manipulation, with the potential to shorten the learning curve and broaden the adoption of challenging procedures, such as ESD.



Video 1 Use of a second instrument through the percutaneous intragastric trocar (PIT) allows traction on the lesion to improve visualization and tissue tension to enhance dissection.

Endoscopy_UCTN_Code_TTT_1AO_2AC

Competing interests

C. Thompson is a consultant for Boston Scientific, Endo-TAGSS, Olympus, Apollo Endosurgery, Fractyl, and USGI medical; H. Aihara is a consultant for Fujifilm, Olympus and Boston Scientific. The remaining authors have no competing interests to report.

The authors

Diogo Turiani Hourneaux de Moura, Hiroyuki Aihara, Kelly E. Hathorn, Liam Patrick Burns, Christopher C. Thompson

Division of Gastroenterology, Hepatology and Endoscopy, Brigham and Women's Hospital, Harvard Medical School, Boston, Massachusetts, USA

Corresponding author

Christopher C. Thompson, MD, MS

Brigham and Women's Hospital, Division of Gastroenterology, Hepatology and Endoscopy, 75 Francis St., Thorn 1404, Boston, MA 02115, USA
Fax: +1-617-264-6342
cthompson@hms.harvard.edu

References

- [1] Kondo A, de Moura EG, Bernardo WM et al. Endoscopy vs surgery in the treatment of early gastric cancer: Systematic review. *World J Gastroenterol* 2015; 21: 13177–13187
- [2] Turiani Hourneaux de Moura D, Aihara H, Jirapinyo P et al. Robot-assisted endoscopic submucosal dissection versus conventional ESD for colorectal lesions: outcomes of a randomized pilot study in endoscopists without prior ESD experience (with video). *Gastrointest Endosc* 2019; 90: 290–298

- [3] Ge PS, Thompson CC, Jirapinyo P et al. Suture pulley countertraction method reduces procedure time and technical demand of endoscopic submucosal dissection among novice endoscopists learning endoscopic submucosal dissection: a prospective randomized ex vivo study. *Gastrointest Endosc* 2019; 89: 177–184
- [4] Bravo JG, Ide E, Kondo A et al. Percutaneous endoscopic versus surgical gastrostomy in patients with benign and malignant diseases: a systematic review and meta-analysis. *Clinics (Sao Paulo)* 2016; 71: 169–178
- [5] Storm AC, Aihara H, Thompson CC. Novel intragastric trocar placed by PEG technique permits endolumenal use of rigid instruments to simplify complex endoscopic procedures. *Gastrointest Endosc* 2016; 84: 518–522

Bibliography

DOI <https://doi.org/10.1055/a-1025-1856>
Published online: 25.10.2019
Endoscopy 2020; 52: E132–E133
© Georg Thieme Verlag KG
Stuttgart · New York
ISSN 0013-726X

ENDOSCOPY E-VIDEOS

<https://eref.thieme.de/e-videos>



Endoscopy E-Videos is a free access online section, reporting on interesting cases and new techniques in gastroenterological endoscopy. All papers include a high quality video and all contributions are freely accessible online.

This section has its own submission website at <https://mc.manuscriptcentral.com/e-videos>