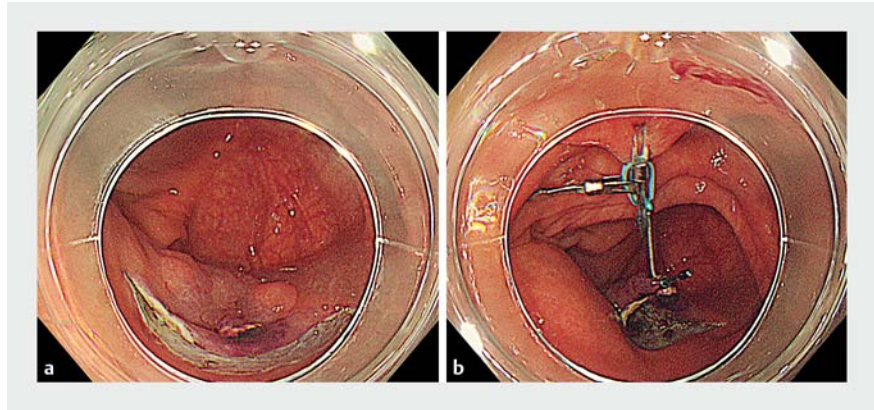


Usefulness of a clutch cutter combined with an S-O clip in improving stability when opening the pocket in the pocket-creation method

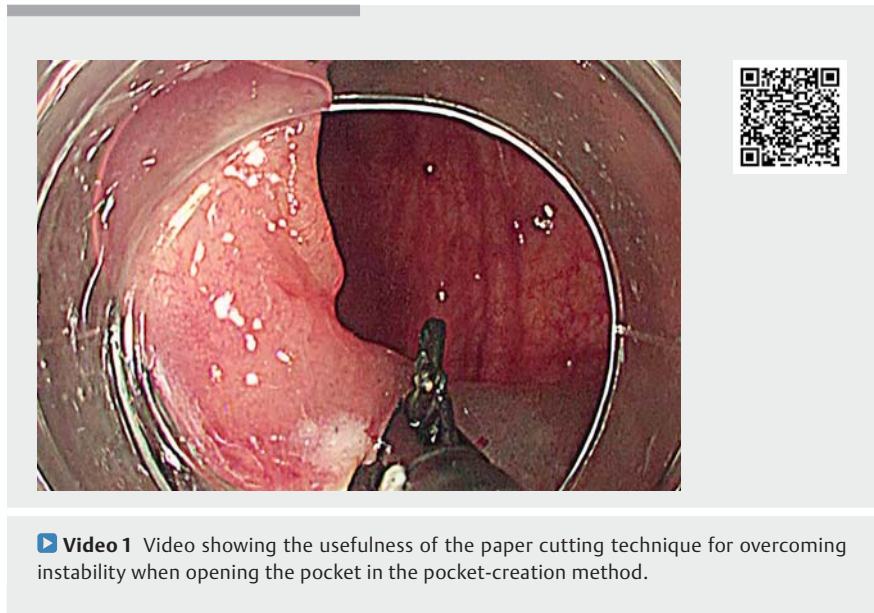
The pocket-creation method (PCM) is a useful resection technique that has been developed to overcome difficulties in colorectal endoscopic submucosal dissection (ESD) [1, 2]. However, this technique itself poses certain challenges in resection when opening the pocket, particularly when there are considerable respiratory changes. Here, we report the usefulness of combining a clutch cutter [3] – a scissor-type knife – with an S-O clip [4] for overcoming instability when opening the pocket in the PCM.

A 76-year-old man underwent ESD for a 23-mm type IIa tumor on the cecum. Marked respiratory changes were observed. We first created a pocket using a clutch cutter. Next, adequate dissection directly beneath the lesion was performed under a stable visual field. When opening the pocket, marked respiratory changes were observed again. An S-O clip was attached to the anal side of the lesion, and once traction was obtained (► **Fig. 1**), the surrounding normal mucosa and submucosa were cut in a manner similar to cutting paper (paper cutting technique [PCT]), and the tumor was removed (► **Fig. 2**). Even with respiratory changes, resection could be safely performed because the lesion was anchored by the S-O clip, as well as by the clutch cutter, and the procedure was completed without any complications (► **Video 1**).

Previously, a tip-type knife was used for PCM; however, for lesions beyond the sigmoid colon with major respiratory changes, instability when opening the pocket was frequently experienced despite the use of an S-O clip. This problem was subsequently overcome by the combined use of a clutch cutter only when opening the pocket. We present this video report of the PCT as an aid for novice surgeons performing colorectal ESD.



► **Fig. 1** Figure showing a submucosal pocket that was created and the lesion with an S-O clip attached. **a** We created a submucosal pocket under most of the lesion using a clutch cutter. **b** An S-O clip was attached to the anal side of the lesion, and traction was obtained.



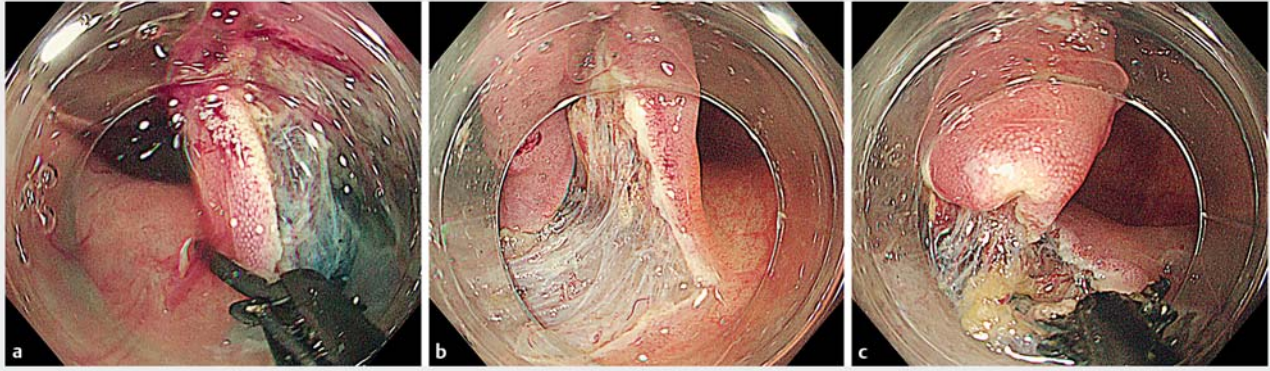
► **Video 1** Video showing the usefulness of the paper cutting technique for overcoming instability when opening the pocket in the pocket-creation method.

The PCT is useful for overcoming instability when opening the pocket in the PCM.

Endoscopy_UCTN_Code_TTT_1AQ_2AD

Competing interests

None



► **Fig. 2** The normal mucosa and submucosa surrounding the lesion were cut in a manner similar to cutting paper (paper cutting technique). **a** Cutting on the left side. **b, c** Cutting on the right side.

The authors

Satoshi Abiko, Ayumu Yoshikawa, Kazuaki Harada, Naoki Kawagishi, Itsuki Sano, Hisashi Oda, Takuto Miyagishima
Department of Gastroenterology, Kushiro Rosai Hospital, Kushiro, Japan

Corresponding author

Satoshi Abiko, MD
Department of Gastroenterology, Kushiro Rosai Hospital, 13-23, Nakazono-cho, Kushiro 085-8533, Japan
Fax: +81-154-257308
abiko1982@gmail.com

References

- [1] Hayashi Y, Miura Y, Yamamoto H. Pocket-creation method for the safe, reliable, and efficient endoscopic submucosal dissection of colorectal lateral spreading tumors. *Dig Endosc* 2015; 27: 534–535
- [2] Sakamoto H, Hayashi Y, Miura Y et al. Pocket-creation method facilitates endoscopic submucosal dissection of colorectal laterally spreading tumors, non-granular type. *Endosc Int Open* 2017; 5: E123–E129
- [3] Akahoshi K, Minoda Y, Komori K et al. Endoscopic submucosal dissection using the “Clutch Cutter” for early esophageal squamous cell carcinoma. *Endoscopy* 2013; 45: 1035–1038
- [4] Sakamoto N, Osada T, Shibuya T et al. The facilitation of a new traction device (S-O clip) assisting endoscopic submucosal dissection for superficial colorectal neoplasms. *Endoscopy* 2008; 40: E94–E95

Bibliography

DOI <https://doi.org/10.1055/a-1024-3566>
Published online: 25.10.2019
Endoscopy 2020; 52: E128–E129
© Georg Thieme Verlag KG
Stuttgart · New York
ISSN 0013-726X

ENDOSCOPY E-VIDEOS
<https://eref.thieme.de/e-videos>



Endoscopy E-Videos is a free access online section, reporting on interesting cases and new techniques in gastroenterological endoscopy. All papers include a high quality video and all contributions are freely accessible online.

This section has its own submission website at
<https://mc.manuscriptcentral.com/e-videos>