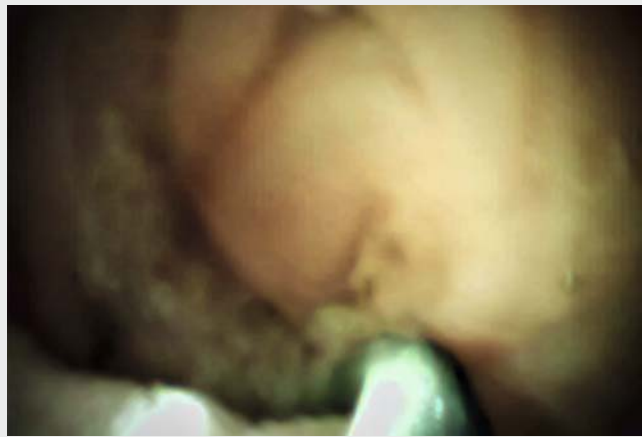

## Treatment of afferent loop syndrome using digital cholangioscopy through the percutaneous transhepatic biliary drainage route

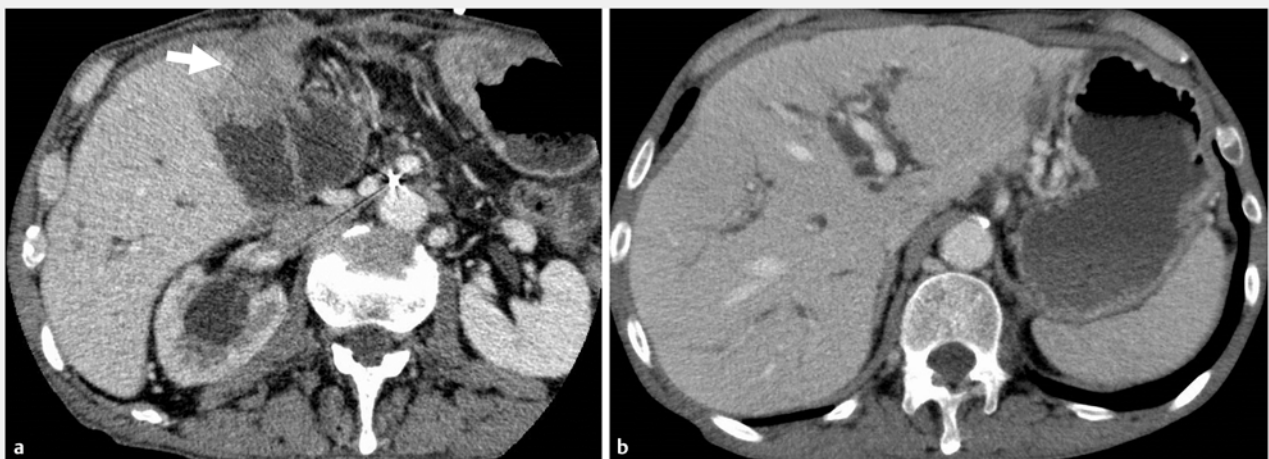
A 75-year-old man with peritoneal recurrence of distal bile duct cancer after pancreaticoduodenectomy was admitted because of cholangitis. A computed tomography scan showed obstruction of the afferent limb by peritoneal metastasis and intrahepatic bile duct dilatation without stricture at the hepaticojejunostomy (► **Fig. 1**). After the patient's cholangitis had resolved with percutaneous transhepatic biliary drainage (PTBD), placement of a self-expandable metal stent (SEMS) was planned across the malignant afferent limb stricture through the PTBD route under fluoroscopic guidance. However, a guidewire could not be passed through the stricture because of the tightness of the stricture and the dilated proximal afferent limb (► **Fig. 2a**). Therefore, once the PTBD route had matured, we inserted the digital cholangioscope (SpyGlass DS Direct Visualization System; Boston Scientific Japan, Tokyo, Japan) through the bile duct. Guidewire passage was easily achieved under direct visualization (► **Fig. 2b**), and a SEMS was successfully placed across the stricture (► **Fig. 2c**; ► **Video 1**).

Recently, there have been strategies reported for non-surgical management of afferent loop syndrome [1, 2], especially using a lumen-apposing metal stent (LAMS) under endoscopic ultrasound (EUS) guidance [3, 4]. While a LAMS pro-

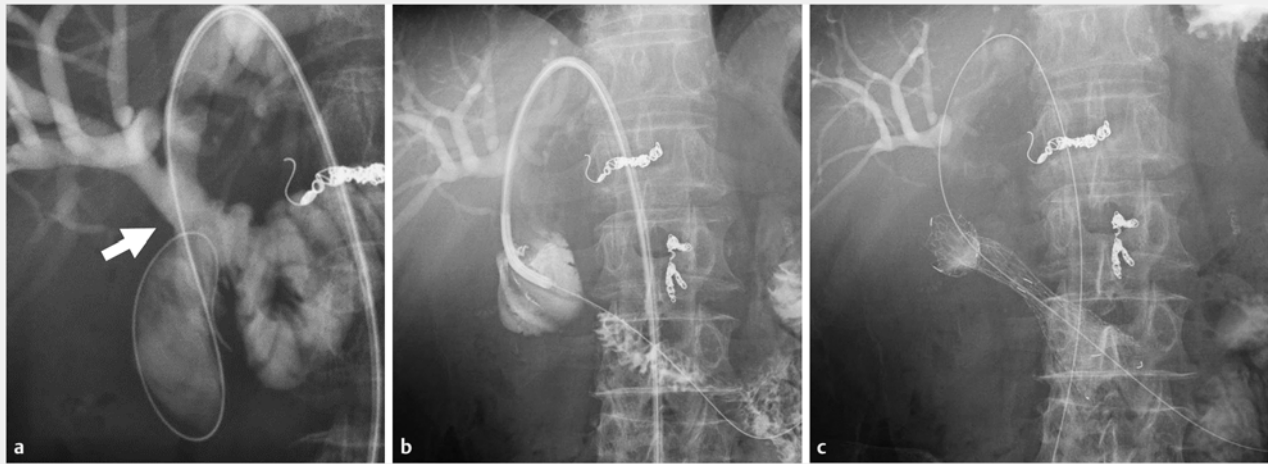
vides safety owing to its one-step procedure, it is not commercially available for this purpose in many countries. Furthermore, EUS-guided gastrojejunostomy carries a potential risk of bleeding or peritonitis if performed in the presence



► **Video 1** Successful guidewire placement across a malignant afferent limb stricture under direct visualization using digital cholangioscopy through the percutaneous transhepatic biliary drainage route in a patient with recurrent bile duct cancer after pancreaticoduodenectomy.



► **Fig. 1** Computed tomography images showing: **a** peritoneal metastasis (arrow) and dilatation of the afferent limb; **b** the dilated intrahepatic bile duct.



**► Fig. 2** Radiographic images showing: **a** the guidewire, which could not be placed across the malignant stricture of the afferent limb under fluoroscopic guidance (the anastomosis of the hepaticojejunostomy [arrow] was widely open); **b** the guidewire successfully placed through the stricture of afferent limb using digital cholangioscopy; **c** a self-expandable metal stent successfully positioned across the malignant afferent limb stricture.

of active cholangitis. Therefore, in patients with concomitant cholangitis, PTBD is often performed as the initial drainage procedure. The PTBD route can then potentially be used to relieve afferent loop syndrome, but guidewire passage across the stricture is technically challenging.

We previously reported the use of digital cholangioscopy as an effective modality for guidewire passage across a complex biliary stricture [5] and we used the same approach for management of this malignant afferent limb stricture. In summary, guidewire manipulation under direct visualization using digital cholangioscopy has proved effective in patients in whom guidewire passage has failed under fluoroscopic guidance, including in the presence of an afferent limb stricture.

Endoscopy\_UCTN\_Code\_TTT\_1AR\_2AG

### Competing interests

None

### The authors

Ryunosuke Hakuta<sup>1</sup>, Hirofumi Kogure<sup>1</sup>, Yousuke Nakai<sup>1,2</sup>, Tatsuya Sato<sup>1</sup>, Naminatsu Takahara<sup>1</sup>, Suguru Mizuno<sup>1</sup>, Kazuhiko Koike<sup>1</sup>

- 1 Department of Gastroenterology, Graduate School of Medicine, The University of Tokyo, Tokyo, Japan
- 2 Department of Endoscopy and Endoscopic Surgery, The University of Tokyo, Tokyo, Japan

### Corresponding author

#### Yousuke Nakai, MD, PhD

Department of Endoscopy and Endoscopic Surgery, Graduate School of Medicine, The University of Tokyo, 7-3-1 Hongo Bunkyo-ku, Tokyo 113-8655, Japan  
Fax: +81-3-38140021  
ynakai-tky@umin.ac.jp

### References

- [1] Sasaki T, Isayama H, Kogure H et al. Double-balloon enteroscope-assisted enteral stent placement for malignant afferent-loop obstruction after Roux-en-Y reconstruction. *Endoscopy* 2014; 46 (Suppl. 01): E541 – E542
- [2] Yane K, Hayashi T, Katanuma A. Successful emergency endoscopic drainage for afferent limb syndrome-induced severe acute cholangitis in a patient with altered Roux-en Y anatomy. *Dig Endosc* 2018; 30: 802 – 803
- [3] Benallal DC, Hoibian S, Caillol F et al. EUS-guided gastroenterostomy for afferent loop syndrome treatment stent. *Endosc Ultrasound* 2018; 7: 418 – 419

- [4] Lajin M, Catalano MF, Khan NM et al. Endoscopic ultrasound-guided gastrojejunostomy using a 2-cm lumen-apposing metal stent to treat benign afferent loop syndrome. *Endoscopy* 2019; 51: 695 – 696
- [5] Hakuta R, Kogure H, Nakai Y et al. Successful guidewire placement across hilar malignant biliary stricture after deceased donor liver transplantation using new digital cholangioscopy. *Endoscopy* 2018; 50: E54 – E56

### Bibliography

DOI <https://doi.org/10.1055/a-0999-5204>  
Published online: 17.9.2019  
*Endoscopy* 2020; 52: E71–E72  
© Georg Thieme Verlag KG  
Stuttgart · New York  
ISSN 0013-726X

### ENDOSCOPY E-VIDEOS <https://eref.thieme.de/e-videos>



*Endoscopy E-Videos* is a free access online section, reporting on interesting cases and new techniques in gastroenterological endoscopy. All papers include a high quality video and all contributions are freely accessible online.

This section has its own submission website at  
<https://mc.manuscriptcentral.com/e-videos>