

How to endoscopically repair a biliodigestive fistula complicating a perforated peptic ulcer: a customized “natural” choledochoduodenal anastomosis

A perforated peptic ulcer is associated with a 30% mortality and 50% morbidity and is usually managed as a surgical emergency [1]. To seal the perforation, applying interrupted sutures with omental apposition is the most commonly used technique [2]. In a few cases, a perforated peptic ulcer may be complicated by a choledochoduodenal fistula, which is managed surgically by laparoscopic digestive resection [3] or medically with a protein pump inhibitor and endoscopic retrograde cholangiopancreatography (ERCP). We present a case of a biliary

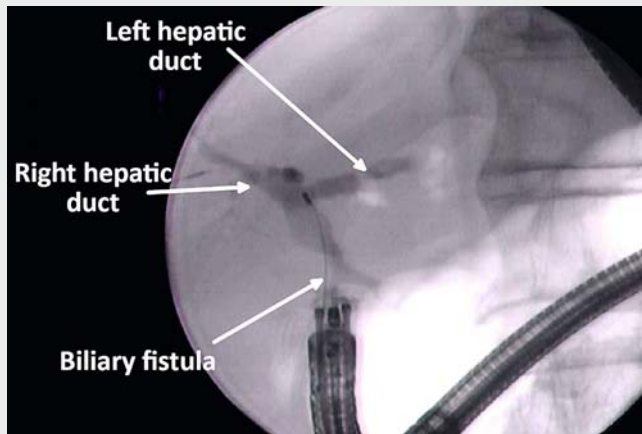
fistula complicating a perforated peptic ulcer that was managed endoscopically in an original way.

An 84-year-old man presented with abdominal pain and fever. Clinical results showed an inflammatory syndrome associated with normal findings from hepatic tests. A perforated peptic ulcer was confirmed by computed tomography (CT) and antibiotic therapy was started (piperacillin/tazobactam 12g daily). The patient had emergency surgery with suturing and abdominal drainage. The drain started producing biliary fluid 1 week

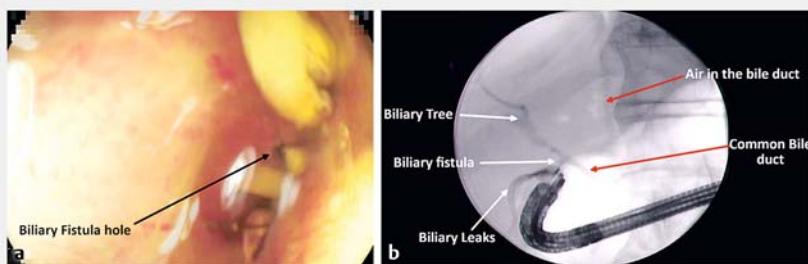
later at a volume of 300 to 500 mL/day. At 1 month, imaging confirmed a persistent duodenal leak, and the patient was transferred to our tertiary center.

Endoscopically, we found an ulcer located in the bulb in contact with the surgical drain hiding the choledochoduodenal fistula (► Fig. 1 a, ► Video 1). First, a straight catheter with a guidewire was introduced into the choledochoduodenal fistula and opacification allowed visualization of the biliary tree (► Fig. 1 b). Second, a fully covered metal biliary stent was deployed, with the proximal flange in the common bile duct and the distal flange in the stomach, to channel the biliary flow. Third, an enteral metallic fully covered stent was deployed that covered the bulb ulcer (► Fig. 2). There was no perioperative complication. At day 1, no biliary fluid persisted in the drain, which was removed. At 6 weeks, an endoscopic control showed after stent removal a complete cicatrization of the bulb (► Fig. 3 a) with a “natural” choledochoduodenal anastomosis (► Fig. 3 b). This case illustrates the possibilities of therapeutic endoscopy to treat complex biliary fistulas by directing the bile towards the digestive tract.

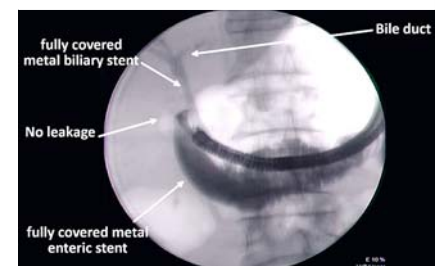
Endoscopy_UCTN_Code_TTT_1AR_2AG



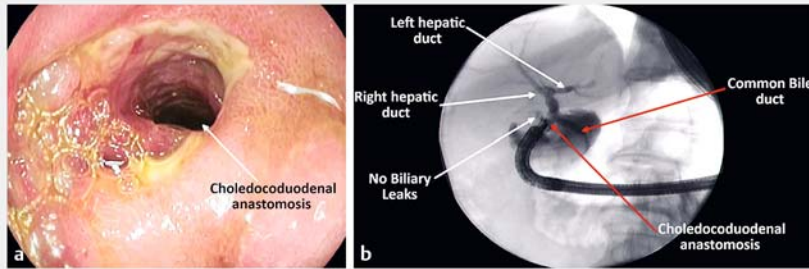
► Video 1 Endoscopic repair of biliodigestive fistula complicating a perforated peptic ulcer, providing a customized “natural” choledochoduodenal anastomosis.



► Fig. 1 A perforated peptic ulcer complicated by a leaking choledochoduodenal fistula. a Biliary fistula opening. b A perforated peptic ulcer with biliary leak.



► Fig. 2 Endoscopic treatment with multiple prostheses.



► **Fig. 3** Control of endoscopic treatment at 6 weeks. **a** Choledochoduodenal anastomosis lumen. **b** Fluoroscopic control showing a customized “natural” choledochoduodenal anastomosis.

- [2] Søreide K, Thorsen K, Harrison EM et al. Perforated peptic ulcer. *Lancet* 2015; 386: 1288–1298
- [3] Tonolini M. Spontaneous pneumobilia revealing choledocho-duodenal fistula: A rare complication of peptic ulcer disease. *J Emerg Trauma Shock* 2013; 6: 146–147

Bibliography

DOI <https://doi.org/10.1055/a-0978-4760>

Published online: 21.8.2019

Endoscopy 2020; 52: E31–E32

© Georg Thieme Verlag KG

Stuttgart · New York

ISSN 0013-726X

Competing interests

None

The authors

Laurent Monino^{1,2}, Jean-Michel Gonzalez², Marc Barthet²

- 1 Department of Hepatogastroenterology, Université catholique de Louvain, Cliniques universitaires Saint-Luc, Brussels, Belgium
- 2 Department of Hepatogastroenterology, Assistance Publique des Hôpitaux de Marseille, Aix-Marseille Université, Hôpital Nord, Marseille, France

Corresponding author

Laurent Monino, MD

Department of Hepatogastroenterology, AP-HM, Aix-Marseille Université, Hôpital Nord, Chemin des Bourrelly, 13015 Marseille, France

Fax: +33-4-91968737

laurent.monino@uclouvain.be

monino.laurent@hotmail.fr

References

- [1] Møller MH, Adamsen S, Thomsen RW et al. Multicentre trial of a perioperative protocol to reduce mortality in patients with peptic ulcer perforation. *Br J Surg* 2011; 98: 802–810

ENDOSCOPY E-VIDEOS

<https://eref.thieme.de/e-videos>



Endoscopy E-Videos is a free access online section, reporting on interesting cases and new

techniques in gastroenterological endoscopy. All papers include a high quality video and all contributions are freely accessible online.

This section has its own submission website at

<https://mc.manuscriptcentral.com/e-videos>