

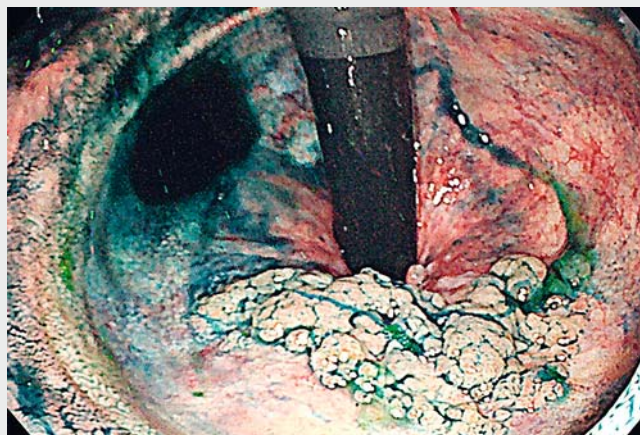
Endoscopic submucosal dissection for remnant rectal neoplasm after ileal pouch-anal anastomosis for ulcerative colitis

Restorative proctocolectomy with stapled ileal pouch-anal anastomosis (IPAA) has been a routinely performed surgical procedure for ulcerative colitis (UC); however, tumor development from the remnant rectal mucosa is problematic [1, 2]. Here, we report a case of successful endoscopic submucosal dissection (ESD) for a neoplasm arising from the remnant rectal mucosa after proctocolectomy for refractory UC (► **Video 1**).

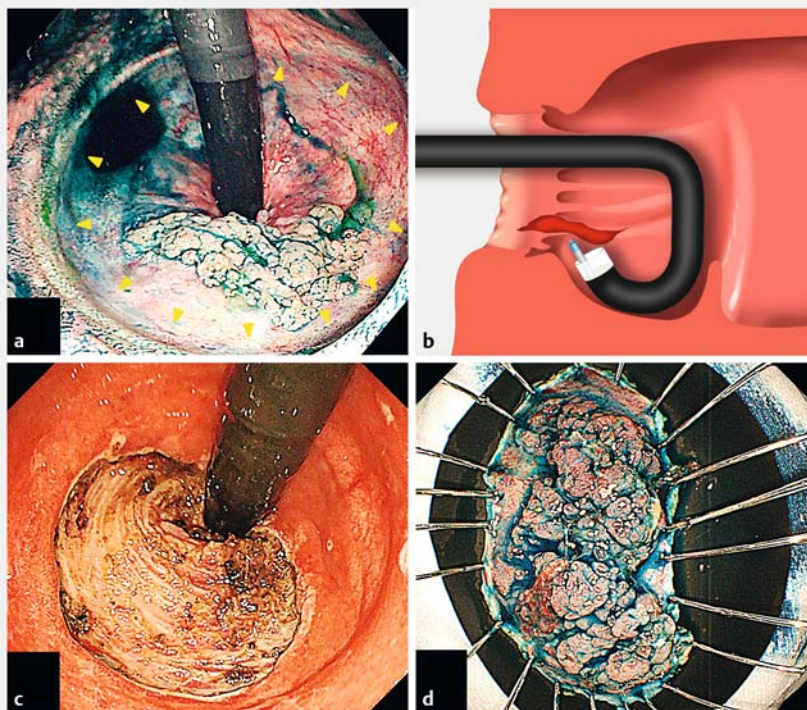
A 64-year-old woman who underwent restorative proctocolectomy with stapled IPAA for refractory UC 16 years ago was diagnosed with a sessile neoplasm, measuring 40 mm in diameter (► **Fig. 1 a**). Endoscopic submucosal dissection (ESD) was proposed as a total excisional biopsy for histopathological assessment, including background mucosa.

The rectal lumen was nonpliable owing to the surgical anastomotic suture and diffuse submucosal fibrosis, and therefore, unlike in the usual rectal ESD procedure, a vertical approach to the muscularis was required. For this we used a multi-bending gastroscope (GIF-2TQ260M; Olympus Medical Systems, Tokyo, Japan), which offered a tangential approach to the submucosal space during a retroflex maneuver (► **Fig. 1 b**). Dissection using endo-cut mode was effective, even for the severe fibrotic submucosa. Successful en bloc resection was achieved (► **Fig. 1 c, d**). Histopathology revealed a tubulovillous adenoma with R0 resection (► **Fig. 2**). Immunohistochemically, the tumor was negative for p53, and no dysplastic lesion was found in the background mucosa. Thus, the lesion was diagnosed as a sporadic rectal adenoma with curative resection.

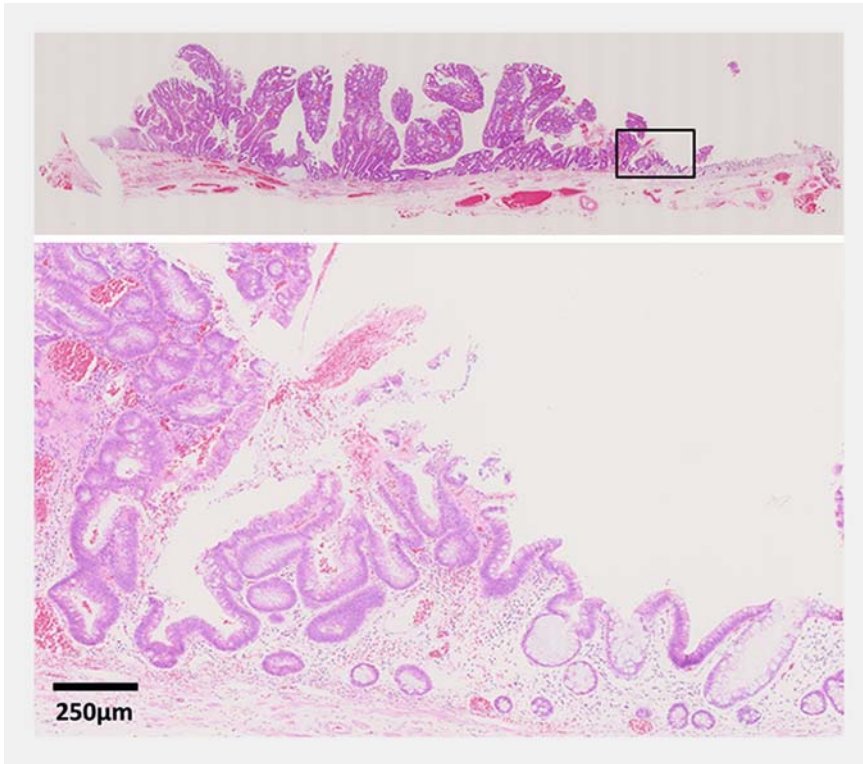
To our knowledge, this is the first report describing tumorigenesis, including sporadic neoplasm, and a detailed technique of rectal ESD after proctocolectomy for UC. Although colorectal ESD for patients with UC is usually difficult because of submucosal fibrosis and adi-



► **Video 1** Endoscopic submucosal dissection for a neoplasm arising from a remnant rectal mucosa after proctocolectomy for ulcerative colitis.



► **Fig. 1** The sequence of endoscopic submucosal dissection (ESD). **a** Endoscopic retroflex view of the lesion. Arrow head shows anastomotic suture line. **b** The schema of tangential approach using a retroflex maneuver with multi-bending function. **c** The ulcer bed after performing ESD. **d** The resected specimen.



► **Fig. 2** Loupe view and high-power microscopic view of the resected specimen. The microscopic view shows the area outlined by a black square in the loupe view (hematoxylin and eosin stain).

pose tissue deposition [3], successful ESD can help to avoid invasive surgery and preserve the quality of life. ESD is considered useful as a precise and minimally invasive diagnostic procedure for neoplastic lesions in patients with UC, even after proctocolectomy.

Endoscopy_UCTN_Code_TTT_1AQ_2AD

Competing interests

None

The authors

Shunsuke Yoshii, Shinichiro Shinzaki, Yoshito Hayashi, Yoshiki Tsujii, Munehiro Ashida, Hideki Iijima, Tetsuo Takehara
 Department of Gastroenterology and Hepatology, Osaka University Graduate School of Medicine, Osaka, Japan

Corresponding author

Tetsuo Takehara, MD, PhD

Department of Gastroenterology and Hepatology, Osaka University Graduate School of Medicine, Osaka, Japan
 Fax: +81-6-68793629
 takehara@gh.med.osaka-u.ac.jp

References

- [1] Annese V, Beaugerie L, Egan L et al. European evidence-based consensus: inflammatory bowel disease and malignancies. *J Crohns Colitis* 2015; 9: 945–965
- [2] Shergill AK, Lightdale JR, Bruining DH et al. The role of endoscopy in inflammatory bowel disease. *Gastrointest Endosc* 2015; 81: 1101–1121
- [3] Suzuki N, Toyonaga T, East JE. Endoscopic submucosal dissection of colitis-related dysplasia. *Endoscopy* 2017; 49: 1237–1242

Bibliography

DOI <https://doi.org/10.1055/a-0950-9501>
 Published online: 30.7.2019
Endoscopy 2019; 51: E406–E407
 © Georg Thieme Verlag KG
 Stuttgart · New York
 ISSN 0013-726X

ENDOSCOPY E-VIDEOS

<https://eref.thieme.de/e-videos>



Endoscopy E-Videos is a free access online section, reporting on interesting cases and new techniques in gastroenterological endoscopy. All papers include a high quality video and all contributions are freely accessible online.

This section has its own submission website at <https://mc.manuscriptcentral.com/e-videos>